

Case study

Retained Fractured Epidural Catheters: A Case Series and a Proposed Management Algorithm

Abstract

Retained fractured epidural catheter fragments are a rare but potentially serious complication of neuraxial anaesthesia, with reported incidences ranging from 0.002% to 0.055%. Despite their infrequency, management remains controversial, particularly in asymptomatic patients, due to the balance between risks of surgical retrieval and potential long-term complications such as migration, infection, granuloma formation, and neurological compromise.

Methods and Objective: This was a 2-centre retrospective study of nine patients with retained epidural catheter fragments following lumbar epidural anaesthesia from 2023-2025. The objective of the study is to describe and evaluate the outcomes of treatment and to design a management guideline.

Results: Computed tomography (CT) scan successfully localized the retained fragments in all cases, with fragment lengths ranging from 0.9 cm to 15 cm, and locations including intra-canal, interlaminar, and paraspinal regions. Seven patients underwent surgical removal within 2–5 days of the incident, while two were managed conservatively. Surgical outcomes were rather favorable.

Conclusion: Our findings support CT scan as the primary imaging modality for accurate localization of retained catheter fragments. Clinical decisions should be guided by symptomatology, fragment location, length, and age factors. Based on expert consensus, we propose a structured management algorithm emphasizing early imaging, risk stratification, and shared decision-making. This approach aims to standardize care, reduce morbidity, and address medicolegal considerations in both tertiary and resource-limited settings.

Keywords: Retained epidural catheter, complications of neuraxial anaesthesia, epidural catheter management, broken epidural catheter.

Introduction

Epidural anaesthesia is a widely used and generally safe technique for lower limb surgery, obstetric procedures, and perioperative pain management. Audits and contemporary reviews have demonstrated a low incidence of serious complications associated with neuraxial techniques (1). Nevertheless, complications may include post-dural puncture headache, epidural hematoma, abscess formation, and rarely, fracture and retention of the epidural catheter (2; 3; 4).

The reported incidence of retained epidural catheter fragments in adults ranges from 0.002% to 0.055% (2; 3; 4). Despite its rarity, this complication presents a significant clinical dilemma. While symptomatic patients typically warrant surgical intervention, management of asymptomatic patients remains controversial. Conservative management carries risks such as migration, abscess formation, granuloma development, and delayed neurological compromise (5; 6; 7; 8; 9; 10; 11), whereas surgical removal may result in dural injury, neurological deficit, wound complications, or failure of retrieval (12; 13).

Increasing medicolegal expectations regarding disclosure of adverse events further complicate decision-making and necessitate transparent communication with patients and families (14; 15). We present a case series of nine patients with retained fractured epidural catheter fragments and propose a consensus-based management algorithm to guide clinical practice for retained epidural catheters.

Material and Methods

This was a retrospective case series conducted in an inpatient setting at two hospitals located in two different states in Malaysia. The study included all patients with retained epidural catheters who were referred and managed between January 2023 and December 2025. Inclusion criteria comprised all patients with a retained epidural catheter following neuraxial anaesthesia who were referred to the spine team at the respective institutions. Patients who declined management by the spine team were excluded. All referrals were made directly by the anesthetic team. The primary objective was to evaluate the effectiveness of the available treatment plans and the outcome.

Upon referral, patient is evaluated for signs and symptoms of the retained catheter. This is done after resolution of anesthetic effects to avoid an inaccurate clinical finding. Identification of the entry point of the retained catheter is scrutinized to determine if there is any portion remained externally visible. The existing catheter examined and estimation of retained catheter is made based on the missing segment. A computed tomography (CT) scan of the lumbar spine was subsequently performed to identify the retained fragment. Concurrently, incident reports were filed, and the hospital's medicolegal team was notified.

Following completion of all investigations, a multidisciplinary meeting was convened to determine the most appropriate management. The recommended plan was then discussed with the patient, outlining the options of surgical retrieval versus conservative management. Patients were counselled on the risks and benefits of surgical intervention, expected outcomes, and potential long-term sequelae.

Surgical retrieval was performed within day 2 to 5 based on feasibility. Explorative techniques and including open laminotomy was performed to retrieve the retained catheter. Post operative, patients were monitored for neurological symptoms and wound healing prior to discharge and further monitored for 6 months. Conservatively treated patients were monitored for the same period. The secondary objective of this study was to share institutional experience and develop a standardized guideline for the management of retained epidural catheters. As this was a retrospective study and no identifiable patient information or materials were used, informed consent was not required, and the study did not constitute a breach of ethical standards.

Results

Case Presentations:

A brief description of the 9 cases series depicted below and summarized in Table 1.

Case 1:

A 22-year-old male underwent lower limb fixation under epidural anaesthesia. During catheter removal, approximately 5 cm of the catheter was noted to be missing. An MRI scan demonstrated a retained fragment within the spinal canal. An initial removal attempt was unsuccessful. Then, a CT scan was performed clearly delineating the fragment. Re-exploration attempt thereafter was successful.

Case 2:

A 32-year-old female undergoing lower limb surgery sustained catheter fracture during removal, leaving approximately 8 cm in situ. CT imaging localized the fragment to the paraspinal region outside the spinal canal. Surgical exploration enabled successful removal without sequelae.

Case 3:

A 26-year-old female underwent elective caesarean section with bilateral tubal ligation. Difficulty threading the epidural catheter resulted in fracture during removal, leaving a 1 cm fragment. CT localized the fragment to the L3/L4 interlaminar space. Patient consented for removal which was successfully removed at the 72–96-hour interval after the incident.

Case 4:

A 28-year-old male undergoing lower limb fixation when the anaesthetist had abruptly pulled the on the catheter resulting shearing at the Touhy needle leaving approximately 15 cm (Figure 1). It was confirmed to be within the spinal canal between L2 and L4 as per CT imaging. The retained catheter was coiled and located anterior to the cord and removal was successful.

Insert Figure 1 here.

Case 5:

A 60-year-old lady undergoing a total knee replacement had a difficult epidural insertion. There was a call to abandon the procedure and upon removal of the catheter, roughly 0.9cm (Figure 2) of catheter tip was missing. CT imaging had located the fragment at the L3/4 interlaminar space. Surgical removal was performed on postoperative day two. The patient developed superficial wound dehiscence that resolved with conservative wound care and antibiotics.

Insert Figure 2 here.

Case 6

A 79-year-old male with underlying diabetes was planned for foot debridement. The anaesthetist had difficulty epidural insertion leading to retained catheter approximately 3.5 cm at L1/L2 space. Due to active foot infection and poor surgical fitness, conservative management was opted. The patient had remained asymptomatic from the retained fragment during follow-up.

Case 7

A 25-year-old female in labour sustained catheter fracture during attempted epidural analgesia, leaving approximately 4 cm within the spinal canal and visualised with CT imaging. Laminotomy was performed for removal on day 4. She later reported mild mechanical low back pain with strenuous activity.

Case 8

A 27-year-old female in labour sustained catheter fracture leaving approximately 12 cm within the paravertebral musculature, extending anteriorly and abutting the inferior vena cava. CT imaging (Figure 3) had confirmed the location, and surgical removal was successfully performed at day 4.

Insert Figure 3 here

Case 9

A 77-year-old female undergoing hip fixation sustained fracture of an epidural catheter tip measuring less than 1 cm. CT imaging located the fragment within the spinal canal. After counselling, the patient declined surgical intervention. She has remained asymptomatic at 6 months of follow up.

Insert Table 1, Figure A-D here.

A total of 9 patients were referred to Spine team for retained epidural catheters. There were 6 females and 3 males with a mean age of 50.5 (range: 22-79). Six patients (66.7%) were being administered neuraxial anaesthesia for elective procedures and 3 others were undergoing emergency procedures. The epidural catheters were all administered at the lumbar region. Fortunately, none of the 9 patients had demonstrated acute symptoms after the event. Magnetic Resonance Imaging (MRI) was only performed for the first case. The remaining cases were managed with only Computed tomography (CT) scan imaging to identify location of the retained fragments. Location of the retained fragments were identified to be within the canal was at 77.8% (intra-canal, interlaminar = 7) and outside the canal (paraspinal= 2) by CT imaging.

Average length of the retained catheter was 5.6 cm whereby the shortest length of retained epidural catheter measured 0.9cm (Figure 2) to and longest 15 cm (Figure 1). Patient in case No. 8 had a 12cm catheter located paraspinal and reported migrated anteriorly and abutting the inferior vena cava (IVC) (Figure 3). Seven patients had undergone surgical retrieval and two opted for conservative management. There were no crossovers from the conservative to the surgical group. Case No.1 had failure in removal at the first attempt after only MRI images available. Subsequently a CT scan done, and reattempt to remove was successful. The other cases with surgical intervention had no intra-operative complications.

Two patients (22.2%) had post operative complications, one with a wound dehiscence which was managed as an outpatient with wound care and the other with low back pain managed with physiotherapy sessions. At 6 months follow-up, there were no further complications reported.

Based on experience derived from these cases, a consensus was achieved using a Delphi method to develop a management algorithm. The main objective of the algorithm is to provide a clear, standardized management for subsequent case referrals, applicable in all clinical scenarios be it in a tertiary or resource limited settings. The algorithm aims to establish a common framework among practitioners, facilitating consistent reporting of outcomes and promoting best medical practices. Additionally, this framework may support the standardization of care, thereby potentially reducing medicolegal risk

Discussion

Epidural catheters are designed to be flexible, stretch-resistant, biologically inert, and radiopaque to reduce complications during neuraxial anaesthesia (4). Despite these design features, catheter fracture may still occur, commonly due to shearing by the Tuohy needle during insertion or withdrawal (4; 16). Other contributing factors include difficult insertion, multiple attempts, excessive catheter advancement, knotting, patient movement, and degenerative spinal changes (6; 13; 17).

First and foremost, when faced with this complication, immediate disclosure to the patient is essential and constitutes both an ethical and medicolegal obligation (5; 14). Clinical assessment should be performed after resolution of anaesthesia to allow accurate neurological evaluation. Although most retained catheter fragments remain asymptomatic, acute symptoms such as radicular pain, neurological deficit, cerebrospinal fluid leak, or localized back pain require urgent intervention (6; 9; 18)

Accurate localization of the retained catheter fragment is pivotal in guiding management. Plain radiographs, ultrasound, CT, and MRI have previously been described for fragment identification (4; 19). Nevertheless, Computed Tomography (CT) imaging has consistently demonstrated superior sensitivity in identifying retained epidural catheter fragments and delineating their anatomical relationship to neural structures (4; 7; 14; 15; 19). In our series, CT imaging accurately localized retained fragment in all cases. Magnetic Resonance Imaging (MRI) scans, while useful for evaluating surrounding soft tissue pathology, it is less reliable for identifying catheter fragments and carries a theoretical risk of fragment migration or thermal injury in catheters containing metallic components (12). Therefore, a CT scan should be considered as the primary imaging modality in suspected retained epidural catheter fragments.

Management of symptomatic patients is generally straightforward, with surgical removal indicated in the presence of neurological deficits, cerebrospinal fluid leakage, exposed catheter fragments, or pain (6; 9; 18). As for asymptomatic patients, conservative management is widely adopted as the main stay treatment but remains controversial. The conservative narratives are justified by idea of the retained catheter is an inert object which is clinically silent where removal poses a procedural risk. Although epidural catheters are manufactured from inert materials, adverse tissue reactions have been reported, including abscess formation, granuloma development leading neurological compromise due to canal stenosis (5; 8). Moreover, retained fragments located within the spinal canal have been associated with nerve root compression, dural erosion, cerebrospinal fluid leakage, and delayed subdural hematoma (6; 7; 9; 10; 11).

From our experience and substantiated by previous reports, fragment length appears to weigh on the risk whereby longer retained fragments possibly coil around nerve roots, and smaller fragments have higher tendency to unpredictably migrate within the spinal canal (6; 9). Retained catheter locations are imperative as highlighted by Ugboma et al. where a retained catheter migration into the intrathecal space resulted in cerebrospinal fluid leakage, while Tarukado et al. described dural erosion caused by a retained catheter fragment. Thus, both authors recommended removal when fragments are retained within the spinal canal (6; 11). Nevertheless, surgical removal is not without risk, which include dural tears, infection, neurological injury, and wound complications (12; 13; 20). Despite the success of conservative management, Felix Corr et al do report a 39% crossover to surgical management due to various reasons raising questions if a delay was necessary. (21)

Age is a key factor and particularly in the paediatric patients due to their ongoing spinal growth and development. In view of that, retained epidural catheter fragments may carry a higher risk of migration, fibrosis, and dural erosion over time (22; 23; 24). Mitra and Fleischmann suggested that surgical removal may be a reasonable option to reduce long-term neurological sequelae in paediatric patients (13). However, surgical intervention requiring bony decompression carries a recognized risk of late spinal deformity in the developing spine and should be emphasised during doctor-patient discussion (25).

Currently there is no consensus for timing of removal. However early surgical intervention may be technically advantageous, as it allows utilization of the original puncture tract before fibrosis or adhesions develop. (16; 20). The optimal duration of follow-up for conservatively managed patients also remains unclear. Delayed complications have been reported from 12 up to 18 years after the initial event, suggesting that short-term observation may underestimate long-term risk (7; 26). Therefore, patients opting for conservative management must be counselled regarding the possibility of delayed complications as mentioned earlier. Recommendation would be if patients be on a structured surveillance and to be educated on the red flag signs.

Due to the rarity of retained epidural catheter fragments, there is no universally accepted management guidelines exist. Several authors have proposed individualized approaches based on fragment location, length, and symptoms (2; 3; 4; 27). Building upon these principles, we developed a management algorithm via a consensus derived through the Delphi technique (28). The experts comprised of senior spine surgeons from the Ministry of Health, Malaysia with more than 100 years of combined experience in spinal surgery. The consensus on treatment approach is summarized into a management algorithm as per Appendix 1.

Insert Appendix 1 here

In the algorithm, we had categorized into symptomatic or asymptomatic patients. The imaging of choice is a Computed Tomography (CT) scan. Besides being more accurate and reliable in delineating fractured fragments, it is also far more assessable in most health care facilities. Key decision variables include location of retained fragment (intra-canal vs extra-canal), retained fragment length and patient age group. Intra-canal fragments are strongly recommended for removal. The 72-hour mark for removal is a suggestion whereby balancing the necessary investigations timeframe and early intervention thus reducing the risk of migration. Conservative treatment is still an appropriate choice as conditions dictate. The algorithm highlights shared decision making in-line with respecting patients' autonomy after clear risk-benefit have been discussed with both surgical treatment and alternatives. The proposed algorithm (Appendix 1) provides a structured framework to support clinical decision-making in both tertiary and resource-limited settings. This structured framework is crucial in view of the medicolegal implications attached to these cases. A blueprint will provide a more effective way to communicate with the patients, relatives and the legal bodies if required.

Strength and Limitations

The nature of this complication and rarity of the retained epidural catheters leaves only a retrospective study feasible. Therefore, given more cross centre collaboration could prove beneficial in improving quality of the data collection, reduce bias and eventually further enhance clinical consensus in the management of this type of cases. Nevertheless, the consensus arrived in developing the algorithm is backed by years of experience and could prove a large steppingstone in the management of retained epidural catheters.

Conclusion

Retained fractured epidural catheters, though rare, can represent a serious complication with potential for delayed neurological and infective sequelae. While many patients remain asymptomatic, the unpredictability of long-term outcomes necessitates careful risk stratification and shared decision-making. A structured management algorithm facilitates consistent, evidence-based care while minimizing patient morbidity and medicolegal risk.

Bibliography

1. *Regional Anesthesia in the Patient Receiving Antithrombotic or Thrombolytic Therapy*. **Horlocker, Terese T.** s.l. : Regional Anesthesia and Pain Medicine, 2018, Vol. 43.
2. *Fractured epidural catheter with retained fragment in the epidural space: a case study and proposed management algorithm*. **Gompels, Ben, Tobin Rusby and Neil Slater.** s.l. : BJA, 2022.
3. *Broken epidural catheter: individualize your management*. **Kumar, Sanjay, et al.** s.l. : Ain-Shams Journal of Anesthesiology, 2023.
4. *Retained epidural catheter: an update*. **Meng, Kevin Tan Teck, et al.** s.l. : Malaysian Journal Of Anaesthesiology, 2023, Malaysian Journal Of Anesthesia.
5. *Talking with Patients about Other Clinicians' Errors*. **Thomas H. Gallagher, M.D, M.Mello, Michelle and Levinson, Wendy.** s.l. : The New England journal of medicine, 2013.
6. *The Breaking of an Intrathecally-Placed Epidural Catheter During Extraction*. **Ugboma, Stella, et al.** s.l. : ANESTH ANALG, 2002.
7. *Delayed Onset of Subdural Hematoma following Epidural Catheter Breakage*. **Ishikawa, Yoshimoto, et al.** s.l. : Global Spine Journal, 2016.
8. *Subcutaneous effusion resulting from an epidural catheter fragment*. **Demiraran, Y., I. Yucel and B. Erdogmus.** s.l. : British Journal of Anaesthesia, 2006, British Journal Of Anaesthesia.
9. *Radicular Pain due to retained fragment of epidural catheter*. **Blanchard, Nicolas, et al.** s.l. : American Society of Anesthesiologist, 1997, American Society of Anaesthesiologist.
10. *Lumbar Stenosis Complicating Retained Epidural Catheter tip*. **Staats, Peter S, M Shawn Stinson and Roland R Lee.** s.l. : American Society of Anesthesiologists, 1995.
11. *A Retained Epidural Catheter Fragment Treated by Surgery*. **Tarukado, Kiyoshi, et al.** 2015, Asian Spine Journal.
12. *Surgical Management of the Retained Epidural Catheter Fragment Complicated by Postoperative Phlegmon*. **Yu, Tina M, Mastoor Nasiri and Solmaz P Manuel.** s.l. : Journal of Anesthesia & Intensive Care Medicine, 2018, Journal of Anaesthesia & Intensive care medicine.
13. *Management of the sheared epidural catheter: is surgical extraction really necessary?* **Mitra, Raj and Katharine Fleischmann.** s.l. : Journal of Clinical Anesth, 2007.
14. *RETAINED BROKEN EPIDURAL CATHETER: WHAT TO DO?* **Kriti, et al.** s.l. : Journal of Indira Gandhi Institute Of Medical Sciences, 2020, Journal of Indira Gandhi Institute Of Medical Sciences.

15. *Imaging of retained surgical items: A pictorial review including new innovations.* **Kumar, G V Santhosh and Ramani, Subhash** . s.l. : Indian Journal of Radiology and Imaging, 2017, Indian Journal of Radiology and Imaging.
16. *Management of broken epidural catheter!!!* **Hippalgaonkar, Amruta Vinod, et al.** 2017, Saudi Journal of Anaesthesia.
17. *Breakage of an epidural catheter in the psoas muscle; case report.* **Elias, Sandra.** [ed.] Dareen Jammoul and Samantha Succar. s.l. : BMC Anesthesiology, 2025, BMC Anesthesiology, Vol. 25.
18. *Management of a Retained Epidural Catheter in a Pregnant Patient: A Case Report and Review of Literature.* **Tang, Kevin W., et al.** s.l. : Open Journal of Anesthesiology, 2024, Open Journal of Anesthesiology.
19. *A broken catheter in the epidural space.* **Anwari, Jamil S., Yahya Al-Wahbi and Saleh Al-Nahdi.** 2014, www.neurosciencejournal.org.
20. *Minimally Invasive Surgery to Remove a Broken and Retained Epidural Catheter Fragment.* **Walia, Sarthak, et al.** s.l. : Cureus, 2022.
21. *Management of Retained Epidural Catheter Fragments: A Narrative Review of Individual Patient Data.* **Corr, Felix, et al.** 2025, Journal of Clinical Medicine.
22. *A Pediatric Epidural Catheter Fracture Suspected to Be Caused by a Glue.* **Yagihara, Masahiro, et al.** 2024, Cureus.
23. *Breakage of a thoracic epidural catheter during its removal.* **Lee, Yong-Ho, et al.** s.l. : Korean Journal of Anesthesiol, 2010, Korean Society of Anesthesiologist.
24. *Pediatric Caudal Epidural Catheter Sequestration: An Unusual Complication.* **Lenox, W. Casey, et al.** s.l. : American Society of Anesthesiologist, 1995, American Society of Anesthesiologist.
25. *Late-onset spinal deformities in children treated by laminectomy and radiation therapy for malignant tumours.* **Jonge, Tama´s de, et al.** s.l. : European Spine Journal, 2005, Euro Spine Journal.
26. *The unexpected epidural: a case report.* **Pinciroli, Riccardo and Roberto Fumagalli.** s.l. : BMC Anesthesiology, 2015.
27. *Retained Epidural Catheter Fragment Requiring Surgical Removal in a Patient With Multiple Comorbidities: A Case Report.* **Lopez Saenz JG, Wang Kong CL, Salazar A, Hidalgo A, Vargas E.** s.l. : cureus, 2026. 10.7759/cureus.105932.
28. *Use of Delphi in health sciences research A narrative review.* **Shang, Zhida.** s.l. : Medicine (Baltimore), 2023.

Table 1: Summary of the 9 cases in the series.

Case	Age / Sex	Procedure (Elective/ Emergency)	Cause of Retained Catheter	Fragment Length	Location of Fragment	Imaging Modality	Management	Outcome / Complications
1	22 / M	Lower limb fixation (Elective)	Fracture during removal	5 cm	Spinal canal	MRI → CT	Surgical removal after re-exploration (Day 5)	Successful removal
2	32 / F	Lower limb fixation (Elective)	Fracture during removal	8 cm	Paraspinal region	CT	Surgical exploration (Day 5)	Successful removal without sequelae
3	26 / F	Elective LSCS + BTL (Elective)	Difficulty threading catheter	1 cm	L3/L4 interlaminar space	CT	Surgical removal (Day 3)	Successful removal
4	28 / M	Lower limb fixation (Elective)	Abrupt traction causing shearing at Tuohy needle	15 cm	Intracanal (L2–L4), anterior to cord	CT	Surgical removal (Day 4)	Successful removal
5	60 / F	Total knee replacement (Elective)	Difficult insertion; procedure abandoned	0.9 cm	L3/L4 interlaminar space	CT	Surgical removal (Day 2)	Superficial wound dehiscence resolved conservatively
6	79 / M	Foot debridement (Emergency)	Difficult epidural insertion	3.5 cm	L1/L2 space	CT	Conservative management	Remained asymptomatic
7	25 / F	Emergency Caesarean (Emergency)	Fracture during attempted epidural	4 cm	Spinal canal	CT	Laminotomy and removal (Day 4)	Mild mechanical low back pain
8	27 / F	Emergency Caesarean (Emergency)	Multiple attempts	12 cm	Paravertebral musculature abutting IVC	CT	Surgical removal (Day 4)	Successful removal
9	77 / F	Hip fixation (Elective)	Epidural catheter tip fracture upon removal	<1 cm	Spinal canal	CT	Conservative management	Asymptomatic at 6 months

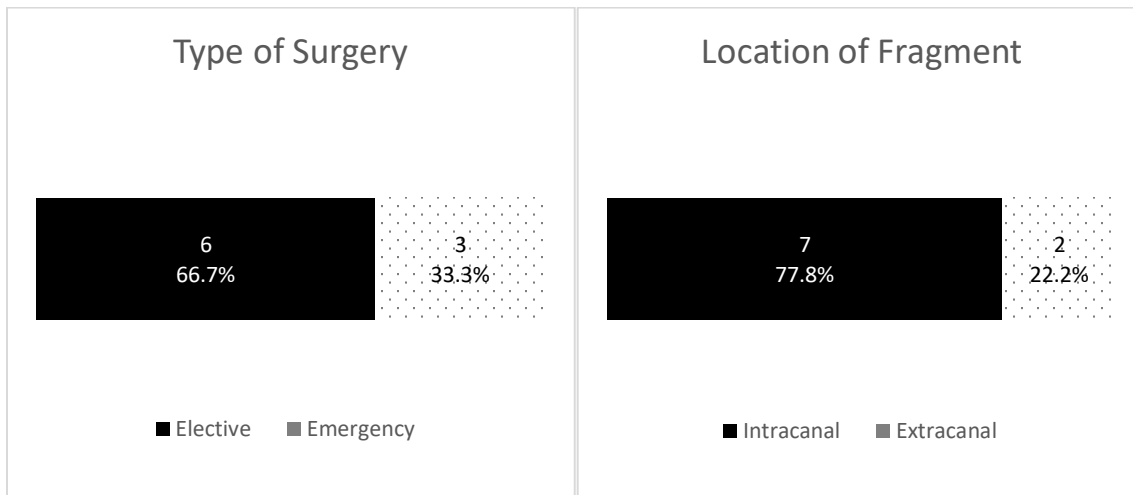


Figure A: Type of surgery

Figure B: Location of fragment

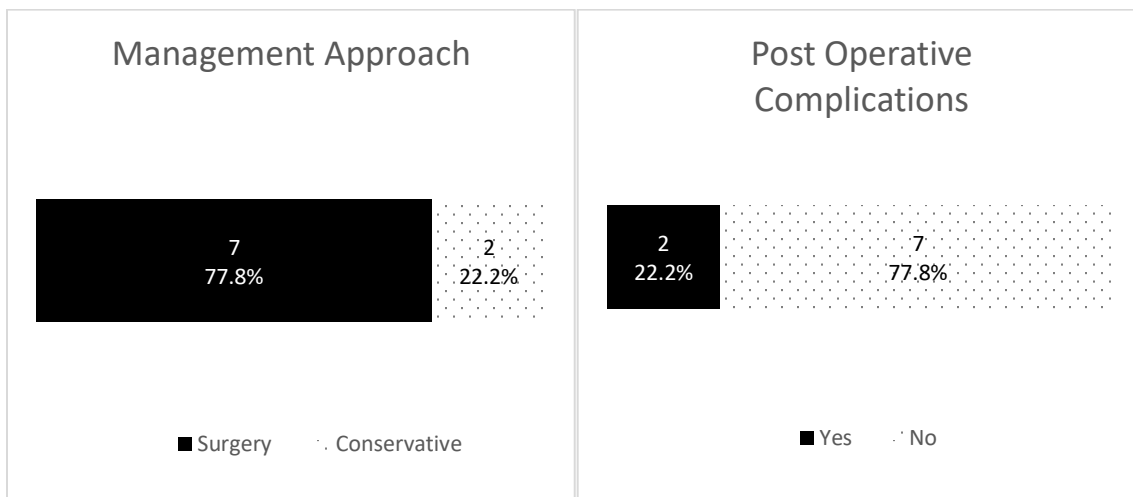


Figure C: Management Approach.

Figure D: Complications

Figure 1: Case 4; Image of removal of the longest retained catheter in our series at 15cm.

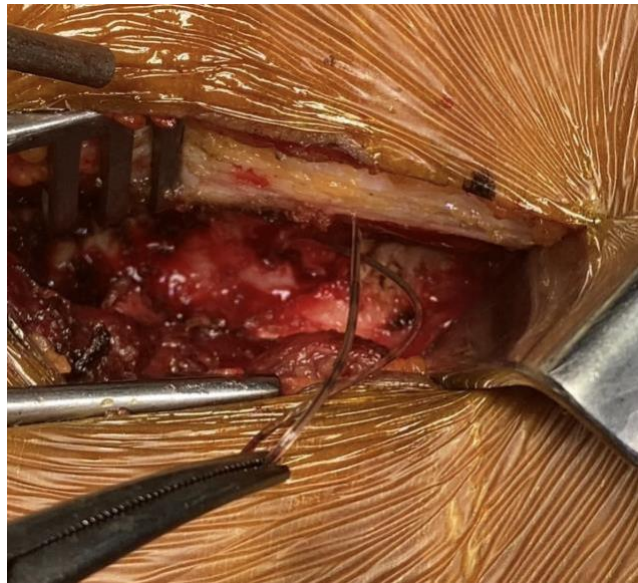

Figure 2: Case 5; Shortest retained catheter within our series at 0.9mm which was located via CT scan.

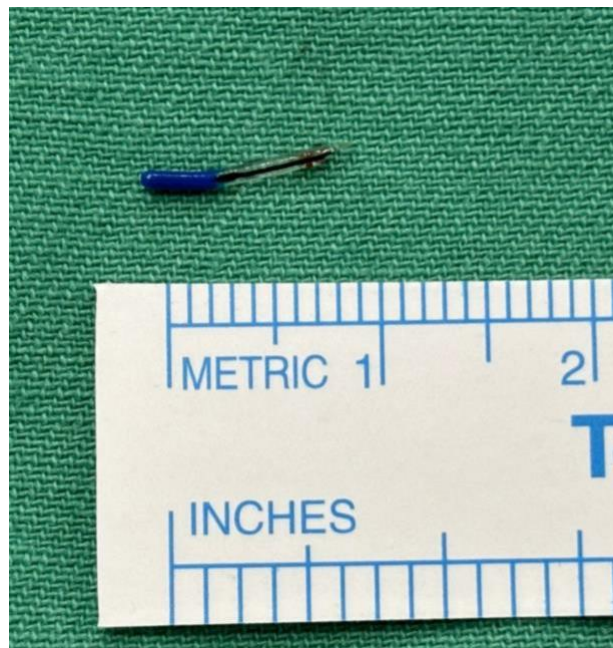

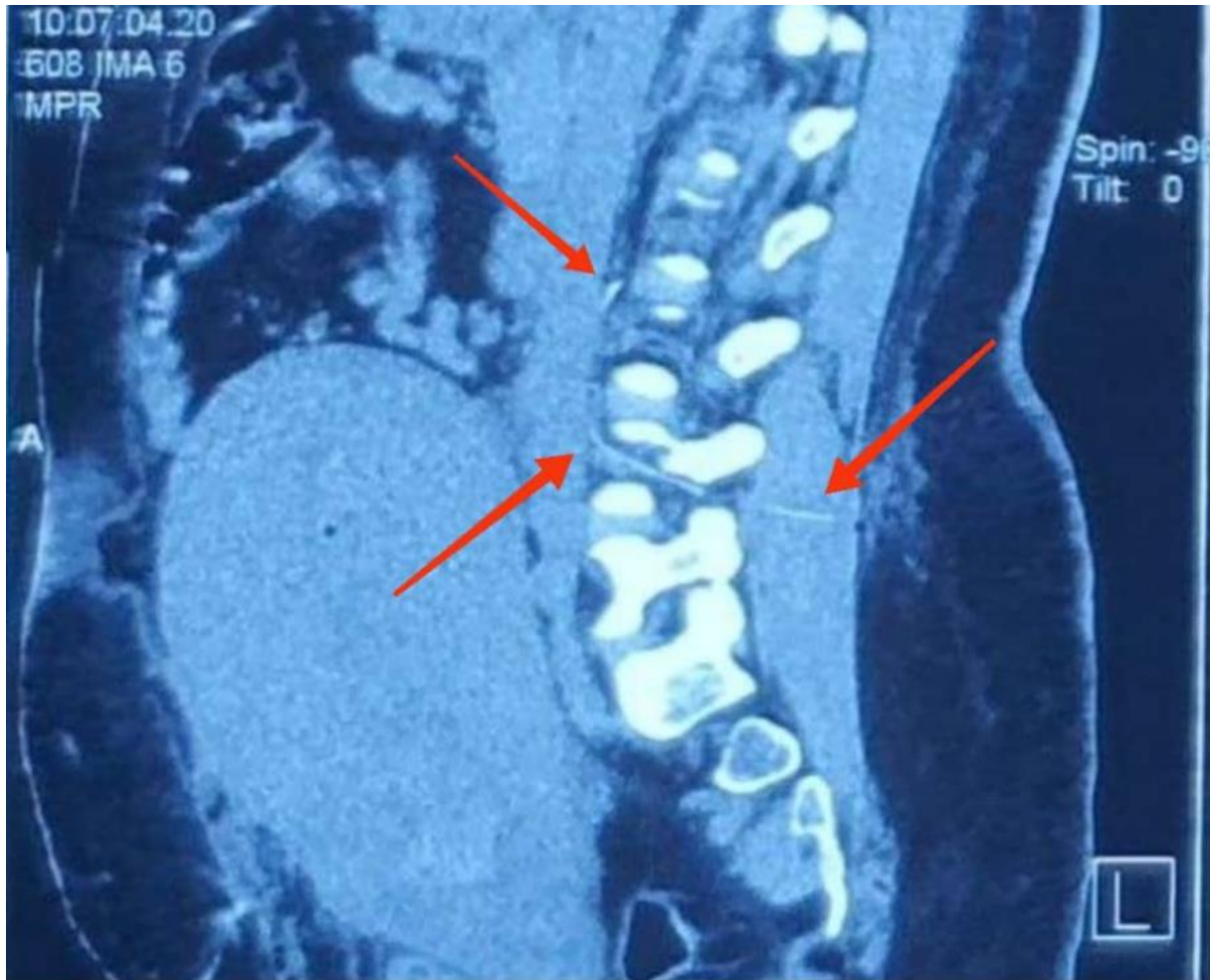


Figure 3: Case 8, 12 cm retained catheter. CT image, showing the catheter migrated anteriorly and abutting the inferior vena cava

Appendix 1: Algorithm for Retained Epidural Catheter

Referral

Clinical assessment:

1. Symptoms: Pain/Neurological deficit (MRI required)
2. Inspect entry site skin condition (eg: catheter remnant)
3. Establish estimated retained length.
4. Identify type of Catheter*

- Disclosure to patient/family on incident by Anaesthetic team.
- Incident report and inform hospital medicolegal team

Imaging: CT scan

- **Symptomatic**
- **Exposed catheter**

Asymptomatic

Follow up for Conservative Management:

Adult: 1 year

Paediatric: Up to 18 years old/Skeletal Maturity

Repeat Imaging if symptomatic

Remove
Timing < 72 H

- Located within spinal canal**
- OR
- >1 cm in length
- < 18 years old***

- Located outside spinal canal**
- AND
- <1 cm in length

Failure:
Symptomatic, attempt after repeat imaging.

Failure:
Asymptomatic

Conservative

*Caution with MRI in metal tip catheter
 ** As per CT imaging
 ***Patient/ Parents discretion after consulting on the pros and cons on surgical vs conservative treatment.

This flow chart is a recommended systemic management to retained epidural catheters. Clinicians are advised to apply based on individual scenarios.