

Subduodenal retroperitoneal paraganglioma mimicking a GIST: a case report

Abstract:

Retroperitoneal paragangliomas, which are rare (<3% of pheochromocytomas/paragangliomas), are non-secreting in 40–60% of cases and are often discovered incidentally due to mass effect. We report the exceptional case of a 66-year-old woman (outside the peak incidence age of 40–50 years) presenting with chronic low back pain and a history of major surgery (gastrectomy, cholecystectomy, thyroidectomy). Ultrasound revealed a 47 mm hypoechoic cystic paraumbilical mass, confirmed on CT scan by a hypervascularised necrotic subduodenal lesion suggestive of a GIST (Gastrointestinal Stromal Tumour).

A midline laparotomy allowed for complete R0 resection of a 58 mm multilobulated mass, with early ligation of the vascular pedicles. Histology confirmed a benign paraganglioma (chromogranin+, synaptophysin+, S100+, Ki-67 <3%, succinate dehydrogenase subunit B [SDHB] preserved). The postoperative course included a wall infection treated with IV antibiotics, with discharge on day 10 and follow-up at 1 year without recurrence (negative PET scan).

This case highlights the diagnostic pitfall of a paraganglioma mimicking a GIST (an error seen in 20–25% of incidentalomas >4 cm), the critical lack of preoperative metanephrine measurement (sensitivity >96%, grade IA recommendation from the European Network for the Study of Adrenal Tumours / European Society for Medical Oncology (ESMO/ENSAT), and the superiority of laparotomy for vascularised lesions >5 cm (recurrence 3–5% vs 15–20% with laparoscopy). Despite a benign phenotype, genetic sequencing is recommended (hereditary in 30–40% of cases). A multidisciplinary approach is essential for these rare presentations.

Keywords: Case Report, GIST, laparotomy, metanephrines, retroperitoneal paraganglioma

Consent: Informed consent obtained for publication and figures.

Introduction

Retroperitoneal paragangliomas (PGLs) are rare tumours arising from extra-adrenal sympathetic chromaffin cells, accounting for less than 3% of pheochromocytomas/paragangliomas (PPGLs) and 6–10% of abdominal localisations (incidence: 1–2/100,000/year). They occur mainly in young adults (peak incidence at 40–50 years) with a predominance of cephalic sites (85%), but extend from the neck to the pelvic floor [1, 2, 3, 5].

These tumours are functional in 30–50% of cases (catecholamine secretion: the triad of hypertension, sweating and palpitations), whilst 40–60% of abdominal forms remain non-secreting and are discovered incidentally due to mass effect [5,6].

A hereditary cause is found in 30–40% of cases (SDHx, VHL and RET genes; MEN2 syndrome (Multiple Endocrine Neoplasia type 2) and NF1 (Neurofibromatosis type 1)). Malignancy (10–20%), defined by lymph node, bone, lung or liver metastases, is particularly associated with SDHB mutations (succinate dehydrogenase subunit B) or a Ki-67 >3%, without histological markers

Multidisciplinary assessment precedes curative resection: metanephrine levels (sensitivity >96%), imaging (CT/PET), and genetic testing. In this context, we report an asymptomatic subduodenal retroperitoneal PGL mimicking a GIST (gastrointestinal stromal tumour), which was resected with R0 status without incident [3,7].

Case history

A 66-year-old woman has a history of surgery: gastrectomy for a stenosing ulcer, pulmonary tuberculosis treated in 2004, cholecystectomy in 2005, and thyroidectomy for a heteromultinodular goitre in 2008.

She attended A&E in November 2024 with chronic low back pain. Physical examination revealed tenderness around the umbilicus with no palpable mass. Blood pressure remained normal, with no cardiovascular or metabolic abnormalities.

An abdominal ultrasound detects a right paraumbilical lesion (47 × 40 × 20 mm), which is hypoechoic, heterogeneous and cystic, with no vascularisation. An abdominal CT scan confirmed a 47 mm hypodense, heterogeneous subduodenal retroperitoneal mass with peripheral enhancement and central necrosis (Figure 1). The suspected diagnosis was GIST.

No preoperative biochemical tests (metanephrines) were performed.

Transperitoneal median laparotomy revealed a 58 mm hypervascularised, multilobulated mass anterior to the right primary iliac vein. R0 resection was performed without haemodynamic complications, thanks to early ligation of the peritumoral vascular pedicles.

Histological examination of the specimen confirmed a paraganglioma (chromogranin+, synaptophysin+, S100+, Ki-67 <3%, SDHB intact). The postoperative course was marked by a wall infection, treated with intravenous antibiotic therapy. The patient was discharged on postoperative day 10. At 1-year follow-up, there was no recurrence (negative ultrasound and PET scans at 6 and 12 months).

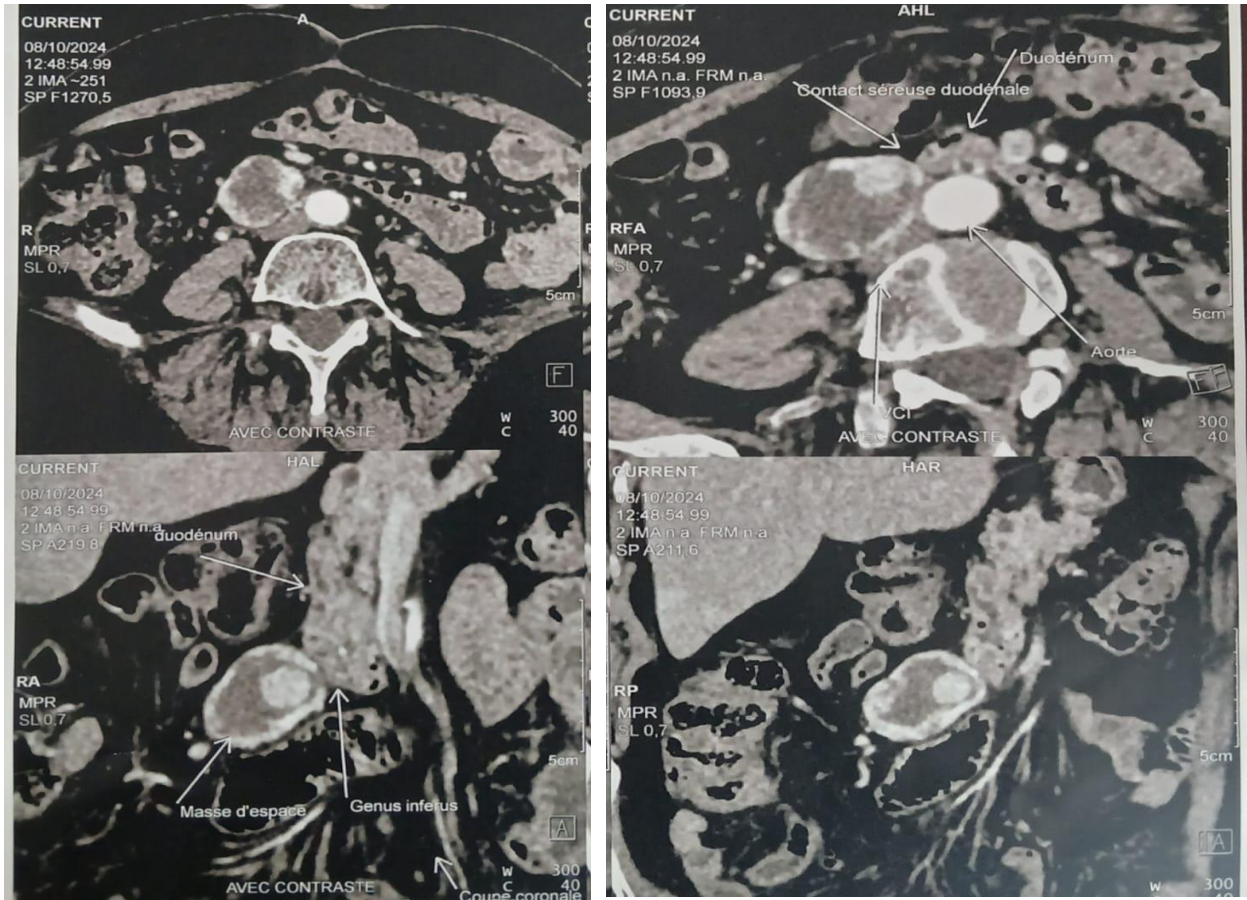


Figure 1: Axial arterial CT scan: a heterogeneous, contrast-enhancing mass in the subduodenal region.

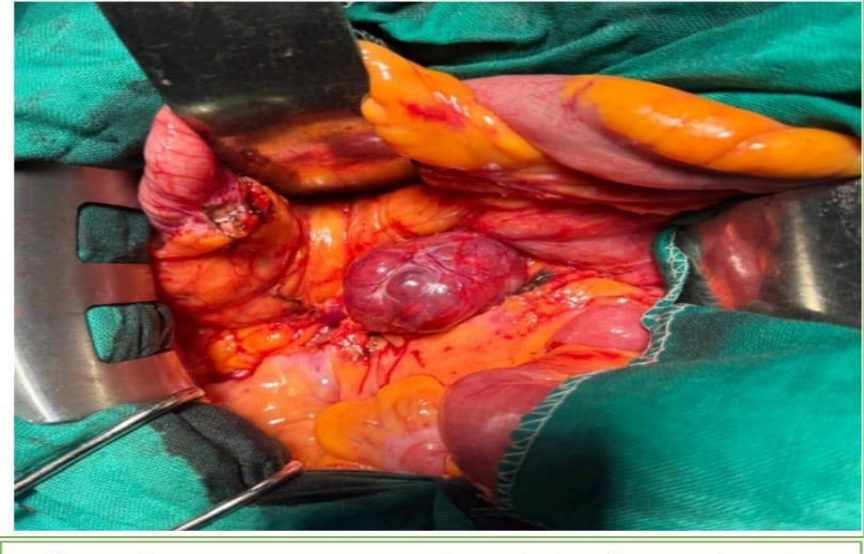


Figure 2: Intraoperative macroscopic appearance of the mass

Discussion

Retroperitoneal paragangliomas originate from sympathetic chromaffin cells. They account for 6–10% of abdominal PPGLs (incidence 1–2 per 100,000 per year)[8]. They are predominantly of the cephalic type (85%)[3]. Patients typically present between the ages of 40 and 50. The catecholaminergic triad (paroxysmal hypertension, sweating, palpitations) affects 50–90% of functional forms. Furthermore, 40–60% of abdominal PGLs remain non-secreting[5].

Our case report illustrates a rare variant: isolated chronic low back pain in a 66-year-old woman, outside the peak incidence period, accounting for less than 5% of musculoskeletal presentations [1,2,4].

Ultrasound revealed a 47 mm hypoechoic, cystic and avascular lesion.

CT showed a hypodense necrotic subduodenal mass with peripheral enhancement, suggestive of a GIST. This differential diagnosis applies to 20–25% of retroperitoneal masses larger than 4 cm.

This pitfall affects 15–30% of abdominal PGLs due to mass effect. Guidelines recommend metanephrines (sensitivity >96%) and PET-SSTR for functional characterisation [5,7,9]. Our non-secreting case confirms this risk of underdiagnosis [5].

We did not measure plasma or urinary metanephrines (grade IA recommendation, ENSAT/ESMO 2023–2024). This omission exposes the patient to the risk of an intraoperative haemodynamic crisis (1–13% without preparation vs <2% with alpha-blockers)[7].

In this case, the non-secretory profile and the absence of the clinical triad explain this decision. However, it contradicts the protocols for retroperitoneal incidentalomas [4]. R0 resection was tolerated without incident, but any incidentaloma larger than 4 cm requires a systematic work-up [10]. The transperitoneal midline laparotomy approach allows for meticulous mobilisation. We ligate the peritumoral pedicles early to achieve curative R0 resection. This strategy is suitable for GLP tumours larger than 5 cm and those with a rich blood supply. It reduces local recurrence to 3–5% at 5 years (vs 15–20% with laparoscopy, OR 4.2)[5,11]. Laparoscopy remains restricted to non-vascularised tumours smaller than 5 cm in specialist centres (10% risk of conversion)[4].

Immunohistochemistry confirms a benign profile: chromogranin A+, synaptophysin+, S100+, Ki-67 <3%, intact SDHB. This profile rules out histological malignancy and limits the risk of metastasis to less than 15% (vs 30–50% for mutated SDHB; HR 3.5)[12].

PPGLs are hereditary in 30–40% of cases (SDHx 20%, VHL 5–10%, MEN2/NF1). Post-operative genetic sequencing is essential (NGS sensitivity 95%), even in the absence of clinical syndrome, for family screening (heritability 15–25%)[1,2].

The absence of such sequencing constitutes a limitation of our study.

The prognosis shows a 10-year survival rate exceeding 95–98% following R0 resection. Wound infection (5–10% of laparotomies) does not affect this outcome [13].

As a case report, the nature of this study does not allow the results to be extrapolated to a wider population. However, it highlights a rare clinical presentation that warrants increased diagnostic vigilance.

Conclusion

This atypical subduodenal retroperitoneal PGL (a 66-year-old woman with low back pain mimicking a GIST) highlights three key surgical considerations. Routine biochemical testing for metanephrines (ENSAT/ESMO grade IA) is essential for retroperitoneal incidentalomas >4 cm (risk of crisis 1–13%). A midline laparotomy is required for vascularised PGLs >5 cm, ensuring R0 resection. Finally, post-operative genetic sequencing remains indicated despite a benign phenotype, for family screening.

A multidisciplinary approach optimises diagnosis, complete resection and follow-up of non-secreting retroperitoneal PGLs.

Consent: Informed consent obtained for publication and figures.

Conflicts of interest: The authors declare no conflicts of interest.

Authors' contributions: All authors contributed to the completion of this work; they have all read and approved the final version of the manuscript.

Reference :

1. Eid M, Foukal J, Sochorová D, Tuček Š, Starý K, Kala Z, et al. Management of pheochromocytomas and paragangliomas: Review of current diagnosis and treatment options. *Cancer Med.* 5 May 2023 ; 12(13) :13942–57.
2. Garcia-Carbonero R, Matute Teresa F, Mercader-Cidoncha E, Mitjavila-Casanovas M, Robledo M, Tena I, et al. Multidisciplinary practice guidelines for the diagnosis, genetic counselling and treatment of pheochromocytomas and paragangliomas. *Clin Transl Oncol.* 2021 ; 23(10) :1995–2019.
3. Lenders JWM, Duh QY, Eisenhofer G, Gimenez-Roqueplo AP, Grebe SKG, Murad MH, et al. Pheochromocytoma and Paraganglioma: An Endocrine Society Clinical Practice Guideline. *J Clin Endocrinol Metab.* 1 June 2014 ; 99(6) :1915–42.
4. Fassnacht M, Tsagarakis S, Terzolo M, Tabarin A, Sahdev A, Newell-Price J, et al. European Society of Endocrinology clinical practice guidelines on the management of adrenal incidentalomas, in collaboration with the European Network for the Study of Adrenal Tumours. *Eur J Endocrinol.* 20 July 2023 ; 189(1):G1-42.

5. Fassnacht M, Assie G, Baudin E, Eisenhofer G, De La Fouchardiere C, Haak HR, et al. Adrenocortical carcinomas and malignant pheochromocytomas: ESMO–EURACAN Clinical Practice Guidelines for diagnosis, treatment and follow-up. *Annals of Oncology*. Nov 2020 ; 31(11):1476–90.
6. Orphanet: Pheochromocytoma-paraganglioma [Internet]. [cited 31 Jan 2026]. Available from: <https://www.orpha.net/fr/disease/detail/573163>
7. de la Fouchardière C, Haissaguerre M, Decaussin-Petrucci M, Renaudin K, Deschamps F, Mirallié E, et al. Recommendations from the ENDOCAN-COMETE national network for the management of metastatic pheochromocytomas and paragangliomas. *Bulletin du Cancer*. 1 Oct 2023;110(10):1063–83.
8. Mete O, Asa SL, Gill AJ, Kimura N, de Krijger RR, Tischler A. Overview of the 2022 WHO Classification of Paragangliomas and Pheochromocytomas. *Endocr Pathol*. March 2022;33(1):90–114.
9. Mahmoud S, Salami M, Salman H. A rare serious case of retroperitoneal paraganglioma misdiagnosed as duodenal gastrointestinal stromal tumour: a case report. *BMC Surg*. 16 March 2020;20:49.
10. Tumour Board in Oncology Monthly: Management of Paraganglioma | NCCN [Internet]. [cited 31 Jan 2026]. Available from: <https://education.nccn.org/node/94356>
11. Shikhmagomedov SS, Rebrova DV, Krasnov LM, Fedorov EA, Chinchuk IK, Chernikov RA, et al. Surgical treatment of pheochromocytoma. *Probl Endokrinol (Mosk)*. 11 Nov 2023;69(5):39-44.
12. Comète's contributions to the genetics of pheochromocytoma – National Academy of Medicine | An institution in tune with its time [Internet]. [cited 31 Jan 2026]. Available from: <https://www.academie-medecine.fr/apports-de-comete-a-la-genetique-du-pheochromocytome/>
13. Li H, Abbas KS, Abdelazeem B, Xu Y, Lin Y, Wu H, et al. A Predictive Nomogram for Early Death in Pheochromocytoma and Paraganglioma. *Front Oncol*. 25 Feb 2022;12:770958.