

Rectal Tuberculosis Presenting with Chronic Rectal Bleeding in an Immunocompetent Patient .

Abstract

Rectal tuberculosis is a rare manifestation of gastrointestinal tuberculosis and an uncommon cause of chronic rectal bleeding, particularly in adolescents. Its clinical and endoscopic presentation is often nonspecific and may mimic inflammatory or neoplastic diseases. We report the case of a 15-year-old girl presenting with chronic rectal bleeding and mucoid discharge evolving over two months. Colonoscopy revealed an edematous, congested, and ulcerated rectal mucosa associated with a trilobed rectal polyp. Polymerase chain reaction testing for *Mycobacterium tuberculosis* performed on rectal biopsy specimens confirmed the diagnosis. Antitubercular therapy resulted in complete clinical resolution. This case highlights the importance of considering rectal tuberculosis in the differential diagnosis of chronic proctitis and rectal bleeding, especially in endemic areas, and emphasizes the diagnostic value of molecular testing on biopsy

Keywords : Rectal tuberculosis; Chronic rectal bleeding; Proctitis; Colonoscopy; *Mycobacterium tuberculosis*

Introduction

Gastrointestinal tuberculosis accounts for a small proportion of extrapulmonary tuberculosis, with the ileocecal region representing the most frequently involved site. Rectal involvement is particularly uncommon and constitutes only a minor fraction of anorectal inflammatory disorders. Owing to its nonspecific clinical, endoscopic, and radiological features, rectal tuberculosis may

closely mimic inflammatory bowel disease, infectious proctitis, or colorectal malignancy, often resulting in delayed diagnosis. Early recognition is crucial to prevent complications and avoid unnecessary invasive interventions. We report a rare case of rectal tuberculosis presenting as chronic rectal bleeding in an immunocompetent adolescent.

Case Presentation

A 15-year-old girl was admitted for evaluation of suspected inflammatory bowel disease. She had a two-month history of intermittent low-volume rectal bleeding occurring after defecation. The bleeding was associated with mucous discharge and false urges without significant tenesmus. Over time, she developed progressive asthenia and unintentional weight loss of approximately 11 kg. There was no history of abdominal pain, bowel obstruction, fever, night sweats, or known tuberculosis contact. She had no prior history of tuberculosis or immunodeficiency (**no history of recurrent hospital admissions, recurrent pulmonary or GI infections, Diabetes etc.**)

Initial laboratory investigations revealed microcytic anemia (hemoglobin 7.5 g/dL; MCV 66 fL), thrombocytosis (667,000/mm³), elevated inflammatory markers (CRP 40 mg/L; ESR 66 mm/h), and elevated fecal calprotectin (644 µg/g). Iron deficiency (ferritin 17 ng/mL) and mild hypoalbuminemia (34 g/L) were noted. HIV serology was negative.

Entero-MRI demonstrated regular circumferential thickening of the mid and upper rectum (maximum thickness 15 mm), without stenosis, as well as focal sigmoid wall thickening. Small

mesorectal lymph nodes (<5 mm) were present. The small bowel appeared normal. Abdominal ultrasound was unremarkable.

Colonoscopy revealed a flat infiltrative rectal lesion extending over 4 cm, located 10 cm from the anal verge, without luminal narrowing. A 14-mm pedunculated rectal polyp was also identified 4 cm from the anal verge, while the remainder of the colon and terminal ileum appeared normal. Histological examination of biopsies taken from the infiltrative rectal mucosa showed chronic nonspecific inflammatory changes with follicular lymphoid hyperplasia, without dysplasia, malignancy, granulomas, or caseous necrosis.

Due to persistent symptoms and inconclusive initial histology, additional molecular analysis was performed on the same rectal biopsy specimens. Polymerase chain reaction testing was positive for *Mycobacterium tuberculosis*, thereby establishing the diagnosis of rectal tuberculosis.

Chest X-ray and QuantiFERON testing were performed, and both were normal.

Standard antitubercular therapy (isoniazid, rifampicin, pyrazinamide, and ethambutol) was initiated, leading to marked clinical improvement with complete resolution of rectal bleeding and discharge. Follow-up confirmed sustained remission, consistent with previously reported favorable outcomes under early treatment.

Discussion

Rectal tuberculosis is an exceptionally rare form of gastrointestinal tuberculosis (GI-TB). According to the 2022 systematic review dedicated specifically to rectal tuberculosis, rectal involvement represents only a small fraction of colorectal tuberculosis cases, with the ileocecal region remaining the predominant site of infection (1). This rarity explains the frequent diagnostic delay and limited awareness among clinicians, particularly in immunocompetent individuals. The pathophysiology of gastrointestinal tuberculosis involves ingestion of infected sputum, hematogenous dissemination, direct spread from adjacent organs, or lymphatic extension (2). Rectal involvement is thought to result from lymphatic spread or direct mucosal implantation. Unlike pulmonary tuberculosis, localized rectal disease may occur without systemic manifestations, as highlighted in major reviews (2,3) and in reported cases of isolated rectal tuberculosis in immunocompetent hosts (4,5). Our patient had no constitutional symptoms and no evidence of immunodeficiency, reinforcing that rectal tuberculosis can occur in otherwise healthy adolescents.

Clinically, rectal tuberculosis is polymorphic. The 2022 systematic review emphasizes that symptoms may include rectal bleeding, mucus discharge, tenesmus, altered bowel habits, anorectal pain, or obstructive symptoms (1). Chronic rectal bleeding is not the most frequent presentation and may lead to suspicion of inflammatory bowel disease (IBD) or neoplasia. Several

case reports have documented tuberculosis presenting as a rectal mass or stricture in children and adolescents, mimicking malignancy or Crohn's disease (6,7). In pediatric abdominal tuberculosis, nonspecific symptoms and delayed diagnosis are frequent, especially in endemic regions (7). Endoscopically, rectal tuberculosis demonstrates heterogeneous features. Reported findings include ulcerations, nodular mucosa, strictures, pseudopolyps, or mass-like lesions (1,8).

These features closely resemble Crohn's disease or colorectal carcinoma. The diagnostic overlap with Crohn's disease is particularly problematic, as emphasized in classical analyses of anorectal tuberculosis (8).

Histopathological diagnosis remains challenging. Although granulomas are suggestive, they are neither sensitive nor specific. Caseous necrosis is inconsistently observed, and acid-fast bacilli are rarely identified due to the paucibacillary nature of intestinal tuberculosis (2). Earlier colonoscopic studies demonstrated that multiple biopsies significantly improve diagnostic yield (9).

Recent advances in molecular diagnostics have substantially improved diagnostic accuracy. The 2023 evidence-based review on abdominal tuberculosis highlights the role of nucleic acid amplification tests (NAAT), including GeneXpert and PCR, particularly when histology is inconclusive (3). A large clinical series evaluating PCR and GeneXpert in anorectal tuberculosis confirmed their added diagnostic value even in smear-negative cases (10). In our patient, PCR testing was decisive in establishing the diagnosis.

Rectal bleeding as a presenting symptom deserves particular attention. Although more commonly reported in colonic or ileal tuberculosis, cases of massive lower gastrointestinal bleeding have been described (11,12). These reports illustrate that tuberculosis should be considered in the differential diagnosis of unexplained lower gastrointestinal bleeding in endemic areas.

Delayed diagnosis may result in complications such as strictures or fistulas. Pediatric cases of rectal or rectosigmoid tuberculosis complicated by stricture have been documented (7).

Fortunately, antitubercular therapy remains highly effective, with favorable outcomes when initiated promptly (1,3,4,5).

Conclusion

Rectal tuberculosis, although uncommon, represents a significant etiological consideration in cases of chronic rectal bleeding and proctitis, including in adolescent patients and in the absence of systemic manifestations. It should be systematically included in the differential diagnosis of chronic proctitis, particularly in regions where tuberculosis remains endemic. Molecular diagnostic techniques performed on rectal biopsy specimens are of paramount importance, as they enhance diagnostic accuracy and contribute to reducing delays in establishing a definitive diagnosis.

References

1. Akbulut S, et al. Rectal tuberculosis: A systematic review. *Int J Surg.* 2022;97:106187.
2. Lawn SD, Zumla AI. Gastrointestinal tuberculosis. *Microbiol Spectr.* 2016;4(6):TNMI7-0014-2016.
3. Sharma V, Mandavdhare HS, Lamoria S, et al. Evidence-based approach to diagnosis and management of abdominal tuberculosis. *World J Gastroenterol.* 2023;29(5):695–716.

4. Khan R, Abid S, Jafri W, et al. Isolated rectal tuberculosis in an immunocompetent host. *Case Rep Gastroenterol.* 2021;15(2):450–456.
5. Ahmed S, et al. Isolated rectal tuberculosis diagnosed with empirical anti-tubercular therapy. *J Coll Physicians Surg Pak.* 2017;27(Suppl 3):S12–S14.
6. Sharma A, et al. Anorectal tuberculosis presenting as a chronic rectal mass in a child: A case report. *J Pediatr Surg Case Rep.* 2018;36:38–41.
7. Bhatnagar V, et al. Rectal stricture: A complication of tuberculosis. *J Pediatr Surg.* 1996;31(3):449–451.
8. Bhargava DK, Tandon HD, Chopra P, et al. Ano-perianal tuberculosis: solving a clinical dilemma. *Gut.* 2005;54(3):384–387.
9. Bhargava DK, Shrinivas, Chopra P, et al. Colonic tuberculosis diagnosed by colonoscopic biopsy. *Gastroenterology.* 1979;76(6):1307–1312.
10. Xie X, et al. Diagnosis of anorectal tuberculosis by PCR, GeneXpert and histopathology. *World J Gastrointest Surg.* 2021;13(4):355–365.
11. Marshall JB. Massive rectal bleeding from colonic tuberculosis. *Am J Gastroenterol.* 1996;91(7):1428–1430.
12. Rana SS, et al. Ileal tuberculosis presenting as massive rectal bleeding. *World J Gastroenterol.* 2009;15(24):3078–3080

Ethics Statement

Written informed consent for publication was obtained from the patient and her legal guardian.

Conflicts of Interest

The authors declare no conflicts of interest.

Funding

None.

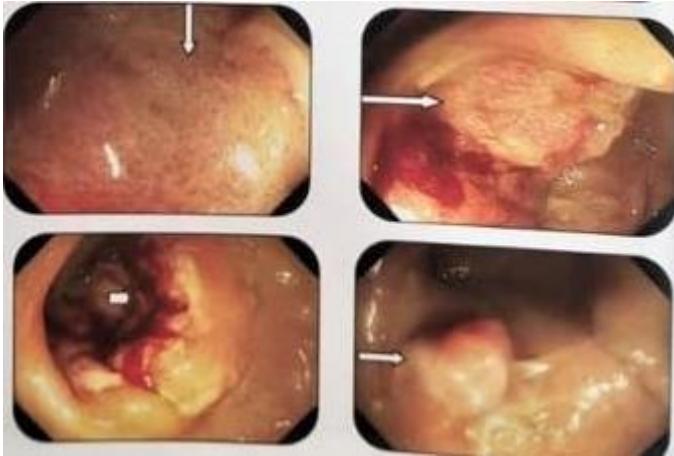


Figure 1 : First Colonoscopy revealed a rectal lesion, infiltrative, non-stenosing, located 10 to 14 cm from the anal verge. a low rectal polyp 14-mm sessile located 4 cm from the anal verge.

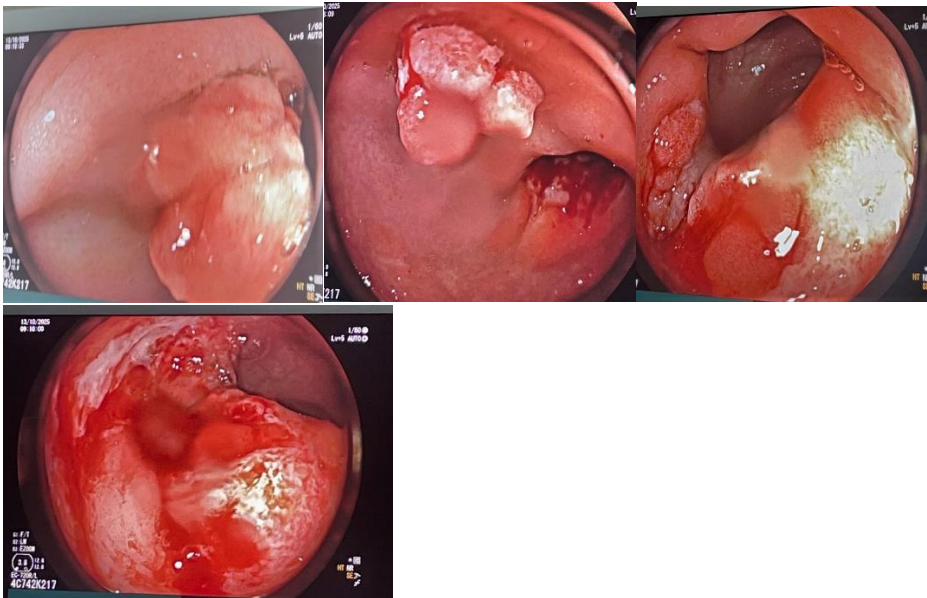


Figure 2 : Colonoscopy (2) revealed an edematous, congestive, and ulcerated rectal mucosa extending from 8 to 12 cm from the anal (right picture)
 -A trilobed rectal polyp identified at 7 cm from the anal margin (left)