

**A Five-Year Analysis of Male Breast Cancer- Significant Insights and Trends in a Low
Medium Income Country**

Abstract

Background: Male breast cancer (MBC) accounts for less than 1% of all breast cancers. Despite its rarity, evidence suggests an increasing incidence globally and in Nigeria. This study reviewed the clinicopathologic characteristics, risk factors, and treatment outcomes of MBC cases managed at the Oncological Surgery Division of the University College Hospital, Ibadan, Nigeria.

Methods: A retrospective study was conducted on all histologically confirmed MBC cases treated between January 2019 and December 2024. Data were extracted from oncology registers and case files, including sociodemographic, clinical, histopathological, and treatment details. Findings were summarised using descriptive statistics and presented as frequencies and percentages.

Results: Twelve patients were identified, representing 2.0% of all breast cancer cases in that period. Ages ranged from 44 to 81 years (mean = 64.5). The left breast was more commonly affected (66.7%), and 75% presented with a painless lump. Most patients (58.3%) had symptoms for 1–3 years, with the majority diagnosed at stage III (58.3%). Invasive ductal carcinoma was the predominant histological subtype (75%), while Luminal A was the most common molecular profile (41.7%). Treatment modalities included mastectomy (41.7%), chemotherapy, and limited radiotherapy. All patients were alive at the last follow-up.

Conclusion: Male breast cancer (MBC) is uncommon but significant in Nigeria. Many cases are diagnosed at a late stage, with invasive ductal carcinoma being the most prevalent type. These findings highlight the importance of raising awareness, improving early diagnosis, and enhancing access to immunohistochemistry and other therapies to better support affected men.

Keywords: Male, Breast Cancer, Oncology, Africa

Introduction

Male breast cancer (MBC) is a rare malignancy, accounting for less than 1% of all breast cancers worldwide (1). The ratio of male to female breast cancer (FBC) is approximately 1:100 (2). Incidence is highest in Israel, with an age-adjusted rate of 0.08 per 100,000 person-years, and lowest in Southeast Asia, particularly in Thailand, at 0.14 per 100,000 person-years (3). The rarity of MBC is largely attributed to the small amount of breast tissue in men and the hormonal environment (4).

Although uncommon, recent data suggest that the incidence is gradually rising in parallel with female breast cancer (5). MBC is typically diagnosed at more advanced stages than FBC, with nearly half of men presenting late compared with about one-third of women (6). Consequently, men often present with larger tumours, greater nodal involvement, and a higher likelihood of metastatic disease, all of which contribute to poorer outcomes (7).

The clinical presentation of MBC is similar to that of FBC. The most common manifestation is a painless, firm, subareolar breast mass. Other features include nipple retraction, ulceration, and nipple discharge, while some men present with axillary lymphadenopathy or metastatic symptoms (2,8,9). Because the male breast has little parenchyma, tumours are usually detected close to the nipple–areolar complex (10). The mean age at onset is 60-65 years, with the risk increasing significantly in the seventh decade (10).

Diagnosis follows the triple assessment model used in women, consisting of clinical evaluation, imaging, and histopathology (2). Clinical examination typically reveals a hard, irregular, and poorly mobile mass fixed to breast tissue (2,11). Ultrasonography is recommended for men under 25 years of age, while mammography is used for those 25 years

or older (12). Histological confirmation by core needle biopsy, with immunohistochemical testing for receptor status, is essential to guide therapy (13).

Several risk factors have been implicated in MBC. Advancing age remains the strongest risk factor, with most cases diagnosed after the age of 60. Black men appear to have a slightly higher incidence and worse prognostic profile compared to white men (14). A family history of breast or ovarian cancer is reported in up to 20% of cases, and BRCA2 mutations markedly increase susceptibility, as well as the risk of prostate and pancreatic cancers (15,16).

Hormonal imbalance also plays a major role, with conditions such as testicular abnormalities, orchitis, orchidectomy, and Klinefelter's syndrome significantly elevating risk. Men with Klinefelter's syndrome (47XXY karyotype) have a 50-fold increased risk of developing MBC (17). Other potential contributors include obesity, marijuana use, chronic liver disease, thyroid disorders, and exposure to estrogen-containing medications (18).

This study presents a five-year review of MBC cases managed at the University College Hospital, Ibadan, Nigeria, highlighting the clinical features, risk factors, management patterns, and outcomes in this population.

Methods

This was a retrospective descriptive study conducted at the Oncological Surgery Division of the University College Hospital, Ibadan, Nigeria, a tertiary health facility serving as a major referral center in Southwestern Nigeria. The study reviewed all histologically confirmed cases of male breast cancer managed at the hospital between January 2019 and December 2024. All male patients with a histopathological diagnosis of breast cancer within the study period were included. Female breast cancer cases and male patients with incomplete diagnostic information were excluded. A total of twelve (12) male patients met the inclusion criteria and were included in the analysis. Data were obtained from the oncology unit's patient register and patient's case files. Information retrieved included sociodemographic data (age, sex), clinical presentation (symptoms, duration, and laterality), risk factors, histopathological diagnosis, immunohistochemical profile, stage at diagnosis, treatment modalities and clinical outcomes. Data were collated and entered into Microsoft Excel 2019 for analysis. Results were summarized using descriptive statistics, and presented as frequencies and percentages. Findings were displayed in tables and figures for clarity. Ethical approval was not required for this study. Confidentiality and anonymity were maintained throughout data collation and analysis.

Results

Prevalance and age distribution

During the study period, twelve male patients were managed for breast cancer, accounting for 2.0% of all breast cancer cases seen at the center (Figure 1). The patients' ages ranged from 44 to 81 years, with a mean age of 64.5 years. The age group distribution is shown in Table 1, with the highest frequencies observed among those aged 40–49 years, 50–59 years, and 70–79 years (each 27.2%).

Table 1: Age group distribution of the patients

Age group [years]	Frequency	Percent (%)
40-49	3	27.2
50-59	3	27.2
60-69	1	9.1
70-79	3	27.2
80-89	2	18.2

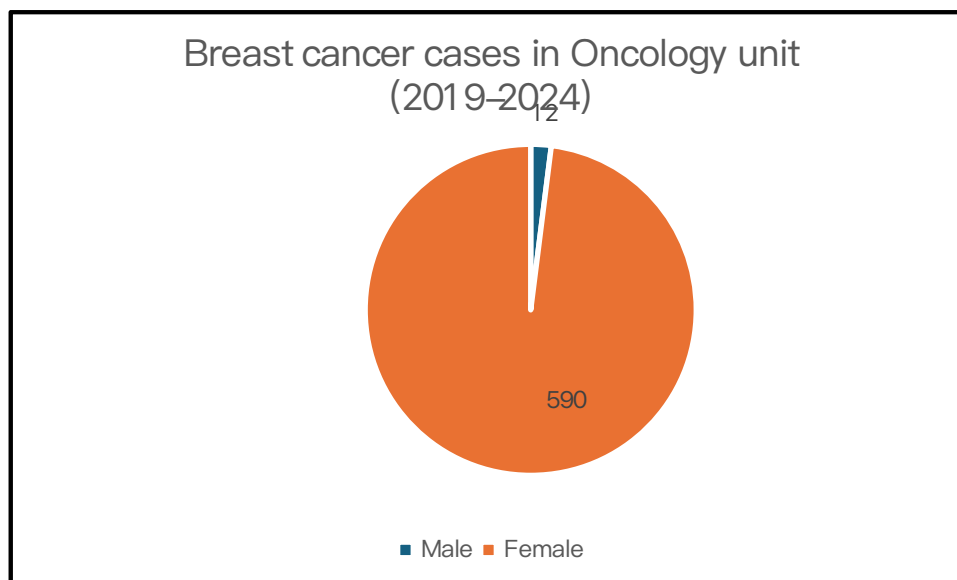


Figure 1: Distribution of breast cancer cases by gender

Laterality and clinical presentation

Disease involvement was more common on the left side, affecting eight patients (66.7%), while four (33.3%) had right-sided disease. Most patients (75%) presented with a painless breast lump, while three (25%) presented with ulceration, and five (41.7%) had axillary swelling (Table 2). The majority of patients (58.3%) had symptoms for 1–3 years before presentation, while 16.7% presented within a year and 25% had symptoms for more than three years. At the time of diagnosis, two patients had stage II disease, seven had stage III, and one had stage IV disease, indicating that most patients presented at an advanced stage (Table 3).

Variables	Classification	Frequency	Percent (%)
Symptoms	Breast lump	9	75
	Ulcer	3	25
	Axillary swelling	5	41.7
Duration of symptoms (years)	<1	2	16.7
	1-3	7	58.3
	>3	3	25

Table 2: Distribution and duration of symptoms

Variables	Classification	Frequency	Percent (%)
Identified risk factors	Family history	3	25
	Age	10	83.3
	Other malignancies	1	8.3
	None	2	16.7
Comorbidities	Retroviral disease	1	8.3
	Prostate cancer	1	8.3
	None	10	83.3

Table 3: Identified risk factors and comorbidities

Risk factors and comorbidities

Advancing age was the most prominent risk factor, with 10 patients (83.3%) older than 50 years (Table 3). Three patients (25%) reported a positive family history of breast cancer, and one patient (8.3%) had a history of another malignancy (prostate cancer) for which he had undergone bilateral orchidectomy. One patient (8.3%) was living with retroviral disease, while the remaining 10 patients (83.3%) had no comorbidity.

Histopathology and Immunohistochemistry

Invasive ductal carcinoma was the predominant histological subtype, diagnosed in nine patients (75%), while three cases were unspecified. Immunohistochemical analysis was available for eight patients: five (41.7%) were classified as Luminal A, and three (25%) as triple-negative breast cancer, while four (33.3%) did not undergo testing due to financial constraints (Table 4).

Variables	Classification	Frequency	Percent (%)
Immunohistochemistry	Luminal A	5	41.7
	Triple negative	3	25
	None	4	33.3
Treatment received	Mastectomy	5	41.7
	Wide local excision	1	8.3
	Adjuvant chemotherapy	3	25
	None	2	16.7

Table 4 : Immunohistochemistry and treatment received

Treatment and Outcome

Treatment modalities varied across patients. Three patients received neoadjuvant chemotherapy, five underwent modified radical mastectomy, one had a wide local excision, and three received adjuvant chemotherapy, while two did not receive any form of treatment (Table 4). This reflects the multimodal approach typically employed in managing breast cancer. At the time of the last documented follow-up, all patients were alive, although one required repeated admissions for the management of malignant pleural effusion.

Discussion

Male breast cancer (MBC) is a rare malignancy, accounting for less than 1% of all breast cancers globally and about 0.3% of cancers in men (19), though its incidence appears to be gradually increasing. In Nigeria and other parts of sub-Saharan Africa, the reported prevalence of MBC varies widely across regions, reflecting potential differences in genetics, environmental exposures, and access to healthcare. Against this background, our study

provides an updated account of the clinicopathologic features, immunohistochemical profiles, and treatment patterns of male breast cancer in a tertiary institution in Southwestern Nigeria, contributing valuable data to the evolving understanding of this uncommon disease.

In this study, male breast cancer accounted for 2.0 % of all breast cancer cases. This prevalence is lower than that reported in Zaria (20,21), Jos (22), and Oshogbo (23), where higher proportions of male breast cancer have been documented. However, it is comparable to findings from Benin (24), Lagos (25,26), Ile-Ife (27), and Enugu (28), where the reported prevalence ranges from 1.6% to 2.4%. The result differs slightly from the previous report by Ajani et al. (29) from this same facility between 2009 and 2018, which documented a prevalence of 1.7%, suggesting a modest upward trend in this centre, possibly reflecting increased awareness and improved diagnostic reporting. When compared with international data, the prevalence observed in our study is higher than that reported in Korea (30) and the United States (31), reflecting the geographical, genetic, and environmental variations in the epidemiology of male breast cancer. The higher prevalence reported in some Northern Nigerian centers may also be related to the greater burden of chronic liver disease in those regions, as hepatic dysfunction is known to increase circulating estrogen levels and predispose to male breast carcinogenesis (20).

This study shows a wide age range among patients affected (44 to 81 years), with a mean age of 64.5 years. Compared to the earlier study by Ajani et al. (29), which reported 22 years as the youngest age in their cohort, our study recorded 44 years as the youngest. This is notably higher than reports by Akosa et al., Kidmas et al., Ezeome et al., and Dogo et al., who documented age ranges of 32–79, 12–85, 25–84, and 19–80 years, respectively (22,28,32,33). The mean age observed in this study is higher than that of the earlier cohort from this facility, where a mean age of 60.3 years was reported (29), and also higher than findings by Oguntola et al. and Ezeome et al. (23,28), who documented mean ages of 60.5 years, and by Ahmed et

al. and Kidmas et al. who reported 59 and 57.9 years, respectively (20,22). However, it is similar to the reports by Adisa et al. and Olu-Eddo and Momoh, who found mean ages of 64.7 and 64.4 years, respectively (24,27).

Our study showed a predominance of left-sided involvement among male breast cancer cases. This contrasts with the report by Ajani et al. (29) from this same center, where 52% of cases were right-sided. However, it is consistent with the observations of Ahmed et al., Ezeome et al., and Olu-Eddo and Momoh (20,24,28), who also reported a higher frequency of left-sided disease. In contrast, Kidmas et al. (22) documented right-sided predominance in their series. Notably, Olu-Eddo and Momoh (24) also reported bilateral involvement in some of their patients, highlighting the variability in laterality patterns across Nigerian studies.

Age, family history of breast cancer, and other malignancies were identified as major risk factors which is consistent with established evidence (34). Multiple studies have demonstrated a strong genetic predisposition in male breast cancer, with BRCA2 mutations being particularly implicated (35–37). The predominance of invasive ductal carcinoma—although three cases were unspecified—aligns with the findings of Ajani et al. (29), who documented 88% of cases as invasive ductal carcinoma, and with other reports (20,28,34). This pattern also mirrors that of female breast cancer in Nigeria, where invasive ductal carcinoma predominates (38,39). Although four patients in this study could not undergo immunohistochemistry due to financial constraints, the predominance of the Luminal A subtype (41.7%) tallies with findings from Kornegoor et al. (40), emphasizing the hormone receptor–positive nature of most male breast cancers.

All patients in this study presented with clinical stages II to IV, with stage III disease being the most common, consistent with the findings of Ahmed et al., Ihekwaba, and Hassan and Mabogunje (20,21,41). Most of our patients presented with a painless breast lump (75%),

while ulcerated masses and axillary swelling were observed in 25% and 41.7% of cases, respectively, similar to those of Ahmed et al, who reported breast lump (79%), breast ulceration (43.9%), and nipple discharge (8.8%) as the commonest presenting symptoms (20). However, no case of nipple discharge was recorded in our series. In contrast, a study among Tanzanian patients documented breast ulceration in up to 90% of cases (42), reflecting regional variation in presentation and diagnostic timing.

Treatment modalities varied among the patients. Three patients received neoadjuvant chemotherapy, five underwent modified radical mastectomy, one had a wide local excision, and three received adjuvant chemotherapy, while two patients did not receive any form of treatment. This variation underscores the multimodal approach commonly adopted in the management of breast cancer, combining surgery, chemotherapy, radiotherapy, and hormonal therapy as appropriate (20,22,43–45).

Strengths and Limitations

This study contributes to the limited body of literature on male breast cancer in Nigeria, particularly as it builds upon previous data from the same institution, allowing for trend comparison over time. It also provides a comprehensive analysis encompassing clinical presentation, histopathological subtypes, and treatment modalities. On the other hand incomplete immunohistochemistry data due to financial constraints among some patients may have introduced bias in the subtype distribution analysis. Despite these limitations, the study offers meaningful insights into patterns of presentation and management within the continent.

Conclusion

Male breast cancer, while rare, poses a significant clinical challenge in Nigeria, with a prevalence rate of 1.8% as shown in this study. The findings confirm that invasive ductal carcinoma is the most common histological subtype, while Luminal A is the leading molecular subtype. Unfortunately, most patients are diagnosed at an advanced stage, highlighting the ongoing issue of late presentations. This situation emphasizes the urgent need to boost public and professional awareness, promote earlier diagnoses, and enhance access to both diagnostic and treatment facilities. Additionally, strengthening cancer registries and fostering multi-institutional collaborations will help identify and address the gaps in the understanding and management of male breast cancer in sub-Saharan Africa.

COMPETING INTERESTS DISCLAIMER:

Authors have declared that they have no known competing financial interests OR non-financial interests OR personal relationships that could have appeared to influence the work reported in this paper.

References

1. Jain S, Gradishar WJ. Male breast cancer. In: *The Breast* [Internet]. Elsevier Inc; 2018 [cited 2025 Oct 27]. p. 974-980.e2. Available from: <https://www.scopus.com/pages/publications/85054302940>
2. Ambareen S, Rani K, H.Kerketta Z, Murari K. Male Breast Cancer: A Retrospective Analysis of Clinical and Pathological Features at a Tertiary Care Center. *Asian Pac J Cancer Care* [Internet]. 2024 Jan 2 [cited 2025 Oct 27];9(1):3–7. Available from: <https://waocp.com/journal/index.php/apjcc/article/view/1040>
3. Fouhi ME, Mesfioui A, Benider A. Male breast cancer: a report of 25 cases. *Pan Afr Med J*. 2020;37:343.
4. Yalaza M, İnan A, Bozer M. Male Breast Cancer. *J Breast Health*. 2016 Jan;12(1):1–8.
5. Ottini L, Palli D, Rizzo S, Federico M, Bazan V, Russo A. Male breast cancer. *Crit Rev Oncol Hematol*. 2010 Feb;73(2):141–55.
6. Co M, Lee A, Kwong A. Delayed presentation, diagnosis, and psychosocial aspects of male breast cancer. *Cancer Med* [Internet]. 2020 Mar 13 [cited 2025 Oct 27];9(10):3305–9. Available from: <https://pmc.ncbi.nlm.nih.gov/articles/PMC7221437/>
7. Rudan I, Rudan N, Basić N, Basić V, Rudan D, Jambrisak Z. Differences between male and female breast cancer. III. Prognostic features. *Acta Medica Croat Cas Hravatske Akad Med Znan*. 1997;51(3):135–41.
8. Cardoso F, Bartlett JMS, Slaets L, van Deurzen CHM, van Leeuwen-Stok E, Porter P, et al. Characterization of male breast cancer: results of the EORTC

- 10085/TBCRC/BIG/NABCG International Male Breast Cancer Program. *Ann Oncol Off J Eur Soc Med Oncol*. 2018 Feb 1;29(2):405–17.
9. Liu N, Johnson KJ, Ma CX. Male Breast Cancer: An Updated Surveillance, Epidemiology, and End Results Data Analysis. *Clin Breast Cancer*. 2018 Oct;18(5):e997–1002.
 10. Hotko YS. Male breast cancer: clinical presentation, diagnosis, treatment. *Exp Oncol*. 2013 Dec;35(4):303–10.
 11. Mainiero MB, Lourenco AP, Barke LD, Argus AD, Bailey L, Carkaci S, et al. ACR Appropriateness Criteria Evaluation of the Symptomatic Male Breast. *J Am Coll Radiol JACR*. 2015 Jul;12(7):678–82.
 12. Thomas M, Al Kashroom H, Reddy S, Zaccarini D, Willer K. Male Breast Cancer: Imaging Considerations for Diagnosis and Surveillance. *J Clin Med Res [Internet]*. 2024 May [cited 2025 Oct 27];16(5):197–207. Available from: <https://pmc.ncbi.nlm.nih.gov/articles/PMC11161189/>
 13. Expert Panel on Breast Imaging:, Niell BL, Lourenco AP, Moy L, Baron P, Didwania AD, et al. ACR Appropriateness Criteria® Evaluation of the Symptomatic Male Breast. *J Am Coll Radiol JACR*. 2018 Nov;15(11S):S313–20.
 14. Sellers L, Miller R, Aggarwal A. Diagnosis and management of breast cancer in men. *Trends Urol Mens Health [Internet]*. 2016 May [cited 2025 Oct 27];7(3):23–6. Available from: <https://wchh.onlinelibrary.wiley.com/doi/10.1002/tre.522>

15. Woods RW, Salkowski LR, Elezaby M, Burnside ES, Strigel RM, Fowler AM. Image-based screening for men at high risk for breast cancer: Benefits and drawbacks. *Clin Imaging*. 2020 Mar;60(1):84–9.
16. Liede A, Karlan BY, Narod SA. Cancer risks for male carriers of germline mutations in BRCA1 or BRCA2: a review of the literature. *J Clin Oncol Off J Am Soc Clin Oncol*. 2004 Feb 15;22(4):735–42.
17. Scagliotti MF, Boietti BR, Knoblovits P. Prevalence of men’s health history in male breast cancer patients. *Endocrinol Diabetes Nutr*. 2023;70(6):415–20.
18. Abdelwahab Yousef AJ. Male Breast Cancer: Epidemiology and Risk Factors. *Semin Oncol*. 2017 Aug;44(4):267–72.
19. Ter-Zakarian A, Agelidis A, Jaloudi M. Male Breast Cancer: Evaluating the Current Landscape of Diagnosis and Treatment. *Breast Cancer Targets Ther* [Internet]. 2025 Jul [cited 2025 Oct 27];Volume 17:567–72. Available from:
<https://www.dovepress.com/male-breast-cancer-evaluating-the-current-landscape-of-diagnosis-and-t-peer-reviewed-fulltext-article-BCTT>
20. Ahmed A, Ukwenya Y, Abdullahi A, Muhammad I. Management and Outcomes of Male Breast Cancer in Zaria, Nigeria. [cited 2025 Oct 23]; Available from:
<https://onlinelibrary.wiley.com/doi/10.1155/2012/845143>
21. Hassan I, Mabogunje O. Cancer of the male breast in Zaria, Nigeria. *East Afr Med J*. 1995 Jul;72(7):457–8.
22. Kidmas AT, Ugwu BT, Manasseh AN, Iya D, Opaluwa AS. Male breast malignancy in Jos University Teaching Hospital. *West Afr J Med*. 2005;24(1):36–40.

23. Oguntola AS, Aderonmu AOA, Adeoti ML, Olatoke SA, Akanbi O, Agodirin SO. Male breast cancer in LAUTECH Teaching Hospital Osogbo, South Western Nigeria. *Niger Postgrad Med J*. 2009 Jun;16(2):166–70.
24. Olu-Eddo AN, Momoh MI. Clinicopathological study of male breast cancer in Nigerians and a review of the literature. *Niger Q J Hosp Med*. 2010;20(3):121–4.
25. Orah N, Daramola A, Daramola A. HISTOLOGIC AND IMMUNOHISTOCHEMICAL CHARACTERISTICS OF MALE BREAST CANCER AT THE LAGOS UNIVERSITY TEACHING HOSPITAL. *Niger Med Pract*. 2018 Jan 17;70.
26. Ajayi DO, Osegbe DN, Ademiluyi SA. Carcinoma of the male breast in West Africans and a review of world literature. *Cancer*. 1982 Oct 15;50(8):1664–7.
27. Adisa TA, Ogbonnaya C, Mordi C, Ajonbadi H, Adekoya OD. Seen but not heard: the voice of women at work and the mediating role of culture. *Int J Hum Resour Manag* [Internet]. 2024 Nov 12 [cited 2025 Jan 7];35(20):3496–523. Available from: <https://www.tandfonline.com/doi/full/10.1080/09585192.2024.2421345>
28. Ezeome E, Emegoakor C, Chianakwana G, Anyanwu S. The pattern of male breast cancer in eastern Nigeria: a 12 year review. *Niger Med J*. 2010 Jan 1;51:26–9.
29. Ajani MA, Odetola SS, Awosusi BL, Fatunla EO, Salami AA. Histopathological analysis of male breast cancer in Southwestern Nigeria: A single-center retrospective study. *J Clin Sci* [Internet]. 2021 Apr [cited 2025 Oct 27];18(2):113–6. Available from: https://journals.lww.com/10.4103/jcls.jcls_66_20
30. Hong JH, Ha KS, Jung YH, Won HS, An HJ, Lee GJ, et al. Clinical Features of Male Breast Cancer: Experiences from Seven Institutions Over 20 Years. *Cancer Res Treat*

[Internet]. 2016 Oct 15 [cited 2025 Oct 27];48(4):1389–98. Available from: <http://e-crt.org/journal/view.php?doi=10.4143/crt.2015.410>

31. Jemal A, Siegel R, Xu J, Ward E. Cancer Statistics, 2010. *CA Cancer J Clin* [Internet]. 2010 Sep 1 [cited 2025 Oct 27];60(5):277–300. Available from: <http://doi.wiley.com/10.3322/caac.20073>
32. Akosa A, Van Norden S, Tettey Y. Hormone receptor expression in male breast cancers. *Ghana Med J*. 2005 Mar;39(1):14–8.
33. Dogo D, Gali BM, Ali N, Nggada HA. Male breast cancer in north eastern Nigeria. *Niger J Clin Pract*. 2006 Dec;9(2):139–41.
34. Korde LA, Zujewski JA, Kamin L, Giordano S, Domchek S, Anderson WF, et al. Multidisciplinary Meeting on Male Breast Cancer: Summary and Research Recommendations. *J Clin Oncol* [Internet]. 2010 Apr 20 [cited 2025 Oct 27];28(12):2114–22. Available from: <https://ascopubs.org/doi/10.1200/JCO.2009.25.5729>
35. Couch FJ, Farid LM, DeShano ML, Tavtigian SV, Calzone K, Campeau L, et al. BRCA2 germline mutations in male breast cancer cases and breast cancer families. *Nat Genet*. 1996 May;13(1):123–5.
36. Thorlacius S, Tryggvadottir L, Olafsdottir GH, Jonasson JG, Ogmundsdottir HM, Tulinius H, et al. Linkage to BRCA2 region in hereditary male breast cancer. *Lancet Lond Engl*. 1995 Aug 26;346(8974):544–5.
37. Wooster R, Bignell G, Lancaster J, Swift S, Seal S, Mangion J, et al. Identification of the breast cancer susceptibility gene BRCA2. *Nature*. 1995 Dec 21;378(6559):789–92.

38. Wemimo RM, Eziagu UB, Sulaiman OA, Abiodun AE, Idowu NA, Ayinde AA, et al. Immunohistochemical and Clinicopathological Characteristics of Invasive Breast Carcinoma in Nigeria. *Oman Med J* [Internet]. 2023 Sep 28 [cited 2025 Oct 27];38(5). Available from: <https://omjournal.org/articleDetails.aspx?coType=1&aId=3560>
39. Adeniji AA, Dawodu OO, Habeebu MY, Oyekan AO, Bashir MA, Martin MG, et al. Distribution of Breast Cancer Subtypes Among Nigerian Women and Correlation to the Risk Factors and Clinicopathological Characteristics. *World J Oncol* [Internet]. 2020 [cited 2025 Oct 27];11(4):165–72. Available from: <http://www.wjon.org/index.php/WJON/article/view/1303>
40. Kornegoor R, Verschuur-Maes AHJ, Buerger H, Hogenes MCH, De Bruin PC, Oudejans JJ, et al. Molecular subtyping of male breast cancer by immunohistochemistry. *Mod Pathol* [Internet]. 2012 Mar [cited 2025 Oct 27];25(3):398–404. Available from: <https://linkinghub.elsevier.com/retrieve/pii/S0893395222017409>
41. Ihekwa FN. The management of male breast cancer in Nigerians. *Postgrad Med J*. 1993 Jul;69(813):562–5.
42. Amir H, Hirji KF. Carcinoma of the male breast in Tanzania. *J Natl Med Assoc*. 1992 Apr;84(4):337–40.
43. Atalay C, Kanlioz M, Altinok M. Prognostic factors affecting survival in male breast cancer. *J Exp Clin Cancer Res CR*. 2003 Mar;22(1):29–33.
44. Bourhafour M, Belbaraka R, Souadka A, M'rabti H, Tijami F, Errihani H. Male breast cancer: a report of 127 cases at a Moroccan institution. *BMC Res Notes* [Internet]. 2011

Dec [cited 2025 Oct 27];4(1):219. Available from:

<https://bmcrenotes.biomedcentral.com/articles/10.1186/1756-0500-4-219>

45. Olayide A, Isiaka A, Ganiyu R, Samuel O, Halimat A, Olalekan O, et al. Breast Cancer Treatment and Outcomes in Nigeria: A Systematic Review and Meta-analysis. *Asian Pac J Cancer Care* [Internet]. 2023 Jul 1 [cited 2025 Oct 27];8(3):591–8. Available from:

<http://waocp.com/journal/index.php/apjcc/article/view/1074>