

Original Research Article

Clinical Outcomes of Nasoalveolar Moulding in Bilateral Cleft Lip and Palate

ABSTRACT

Introduction: Nasoalveolar Moulding (NAM) is a pre-surgical technique designed to reshape the alveolus, lip, and nose in infants with cleft lip and palate. The objectives of NAM for bilateral cleft lip and palate include: retracting the premaxilla using extraoral traction via lip taping, preserving the arch form with a passive appliance, developing clinically significant columellar tissue, and achieving harmonious nasal tip projection.

Aim and objective: To assess effectiveness of nasoalveolar moulding on alveolus and nose in bilateral cleft lip and palate.

Study design: Descriptive study

Place and Duration of Study: IGIMS, Patna. Between March 2022 and March 2024

Material and Method: This descriptive study comprised 10 infants with bilateral cleft lip and palate (BCLP), undergoing nasoalveolar moulding (NAM). The mean age of the infants at the start of the study was <6 weeks, impression was taken over which NAM appliance was fabricated and adjusted weekly depending upon progress of the treatment. Nasal stents were incorporated once the cleft width was reduced to 6 mm. Duration of treatment extends to 25 to 29 weeks. Post NAM impression was taken, alveolar and nasal measurements were recorded.

Result: Right & left Alveolar cleft width, mid-palatal arch width decreases significantly. Columellar length, right & left nasal height increase due to tissue elongation. Right & left nasal width and bialar width decreases significantly.

Conclusion: NAM therapy should be considered an integral part of the multidisciplinary approach to managing cleft lip and palate, improving not only the surgical outcomes but also the overall quality of life for affected infants.

Key words: *Nasoalveolar moulding, Bilateral cleft lip and palate, surgical challenges*

INTRODUCTION

Efforts to ease the surgical challenges of cleft lip and palate have a long history, with records from the 16th century detailing attempts to improve outcomes for patients with bilateral cleft lip and palate (BCLP). The original research on neonatal moulding of the nasal cartilage was performed by Matsuo using silicone tubes to mould the nostrils.

The core principle of reducing deformities prior to surgery has persisted over time and extends into orthodontics. The modern school of presurgical orthopaedic treatment in cleft lip and palate was started by McNeil in 1950.¹ The concept of PNAM (Presurgical Nasoalveolar Moulding) was developed based on the understanding that an infant's cartilage is highly mouldable due to high levels of maternal oestrogen in their bloodstream. This allows the cartilage to reshape permanently. Oestrogen causes an increase in hyaluronic acid. The abundant amount of hyaluronic acid causes disconnection of intercellular material resulting in a lack of elasticity.²

Hoffman described utilizing the head as extraoral anchorage using a head cap with arms extended to the face to retract the premaxilla and narrow the cleft.³ The idea of using an intraoral device to move cleft alveolar segments into position is attributed to **McNeil**. He proposed that pressure forces created by "functional" orthopaedic appliances, which are within the limits of tolerance, will act to stimulate bone growth in an anterior direction.⁴ The active retraction of premaxilla as advocated by him was surrounded by controversy. In response to controversy associated with active retraction of the premaxilla, **Hotz** described the use of a passive orthopaedic plate (Zurich appliance) to slowly align the cleft segments.⁵ **Matsuo** following the successful application of moulding therapy to correct deformed auricular cartilage applied the same method to correct unilateral cleft lip nasal structures.⁶

Presurgical infant orthopaedics is an umbrella term that covers any treatment of an infant's cleft deformity before the definitive primary lip surgery.⁷ Presurgical infant orthopaedics (PSIO) was developed, incorporating methods like maxillary plates, lip taping, and the Nasoalveolar Moulding (NAM) technique introduced by Grayson for treating both unilateral and bilateral cleft patients. Nasoalveolar Moulding (NAM) is a technique to pre-surgically mould the alveolus, lip and nose in infants born with cleft lip and palate.⁸

Objectives of Nasoalveolar Moulding for bilateral cleft lip and palate are retraction of the premaxilla with extraoral traction by lip taping, maintenance of the arch form using passive appliance, create a clinically appreciable columellar tissue and harmonize the nasal tip projection.⁹

NAM is widely practiced in various regions, including the U.S. and parts of Europe, its use remains controversial. Surveys indicate that around 30-50% of cleft teams adopt NAM, yet the evidence supporting this technique is mixed. American Cleft Palate–Craniofacial Association and Canadian Society of plastic surgeons revealed nasoalveolar moulding is used at least occasionally by 38 % and greater than half the time by 24 % of surgeons.¹⁰

Proponents claim it improves nasal symmetry, reduces the severity of clefts, and minimizes the need for additional surgeries, while opponents argue that its long-term benefits are inconsistent, and the burden it places on families can outweigh its advantages¹¹. **Most studies, including a systematic review, find no significant long-term differences in speech, facial growth, or facial aesthetics in these children.**¹²

Thus, while NAM remains one of the most practiced infant orthopaedic techniques, the medical community has yet to reach a consensus on its effectiveness, leaving the scientific debate unresolved. This ongoing discourse underscores the need for standardized treatment protocols and more robust long-term studies to determine NAM's true impact on patients with cleft lip and palate

AIMS AND OBJECTIVES

To assess effectiveness of Naso-alveolar moulding on alveolus and nose in infants with bilateral cleft lip and palate.

MATERIAL AND METHOD

This study was designed as a **descriptive study** and received approval from the Institutional Ethics Committee of IGIMS, Patna. This **descriptive study** comprised 10 infants with bilateral cleft lip and palate (BCLP), undergoing nasoalveolar moulding (NAM). The mean age of the infants at the start of the study was <6 weeks days, with the treatment duration extending to 25 to 29 weeks. Inclusion Criteria was infants diagnosed with non-syndromic bilateral cleft lip and palate reported within six weeks of birth. Infants whose families provided informed consent for treatment were included in the study. **Exclusion criteria was consent not obtained, medically unfit for treatment and unilateral, incomplete or submucous cleft.**

Initial Patient Evaluation and Impression Procedure

Each participant underwent a comprehensive initial evaluation by the multidisciplinary cleft craniofacial team. Upon receiving clearance, pre-treatment (T0) impressions of both the intraoral and extraoral structures were obtained. This procedure was performed under the supervision of an anaesthetist and a paediatric surgeon to ensure the safety and comfort of the infant. The impressions were taken using a custom-made tray with putty impression material. After impression, the materials were meticulously disinfected and poured using Orthocal, a Class III dental stone, to ensure the precision of the model. Pre- NAM cast is shown in Figure 1.



Figure 1. Pre Nasoalveolar Moulding Maxillary and Nasal cast

Fabrication and Adjustment of the NAM Appliance

The NAM appliance fabricated in this study followed the protocol established by Grayson et al. (1999).¹³The appliance consisted of an acrylic plate, with two retention buttons (Figure 2). The buttons were placed at a **30- to 40-degree** angle to the occlusal surface of the alveolar ridges to achieve proper retention and avoid unseating of the appliance from the palate.

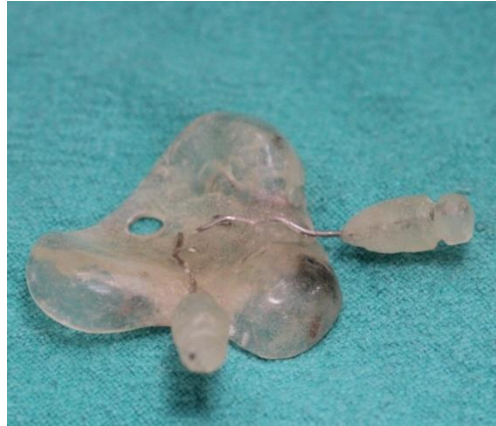

Figure 2. Nasoalveolar Moulding plate with two retention buttons

The two nasal stents incorporated once the cleft width had been reduced to 6mm. The stents were made up of 0.36 inch, round stainless-steel wire and takes the shape of a 'Swan Neck'.¹⁴ (Figure 3)

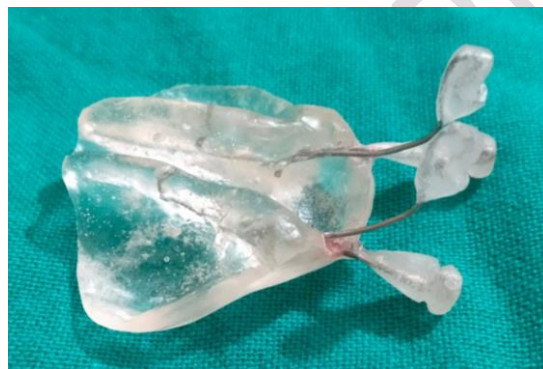

Figure 3. Stent added in Nasoalveolar Moulding plate

The appliance was subjected to weekly adjustments based on the infant's progress, as assessed by the clinical team. The premaxilla was repositioned by modifying the PNAM plate, in conjunction with external taping and elastic forces. The alar cartilage was gradually advanced towards the nasal tip through the incremental addition of acrylic material to the nasal stent. When 2 to 3 mm of columella have been produced, the two nasal stents are connected by a band of soft acrylic resin. Total timing for Naso-alveolar moulding was 4-5 month. Post NAM records (T1) were taken before lip repair. Post NAM plaster model is shown in (Figure 4). All measurements were done using pointed beak digital vernier calliper (Figure 5).

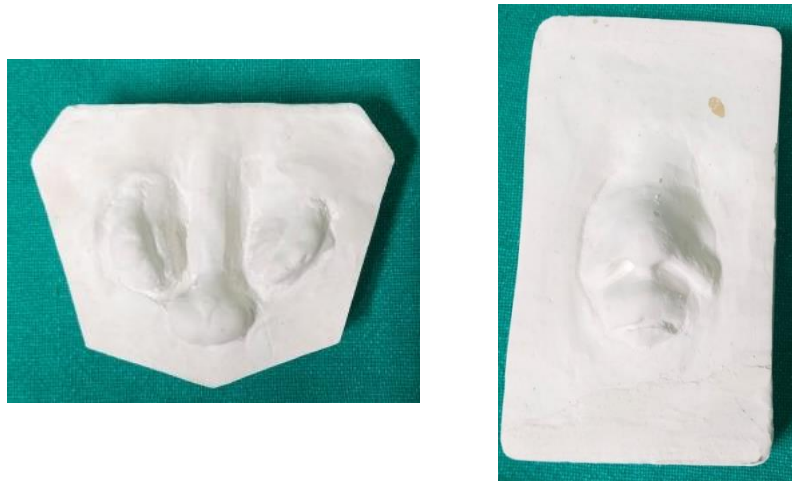

Figure 4. Post Nasoalveolar Moulding Maxillary and Nasal cast



Figure 5. Digital calliper with pointed beak

Description of parameters measured on maxillary cast (Figure 6)

- 1) Alveolar cleft width in right side in BCLP - RACW
- 2) Alveolar cleft width in left side in BCLP - LACW
- 3) Mid-palatal arch width - PP'

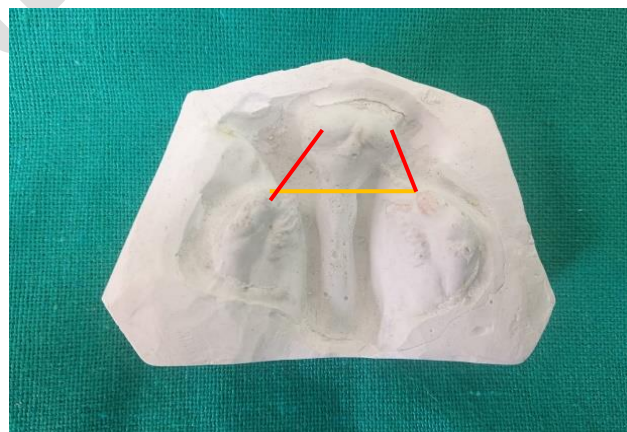


Figure 6. Parameter for Maxillary cast measurement

Description of parameters measured on nasal cast (Figure 7)

1. Columellar length - CL
2. Nasal width (right) - RNW
3. Nasal width (left) - LNW
4. Nasal height (right) - RNH
5. Nasal height (left) - LNH
6. Bialar width - BAW


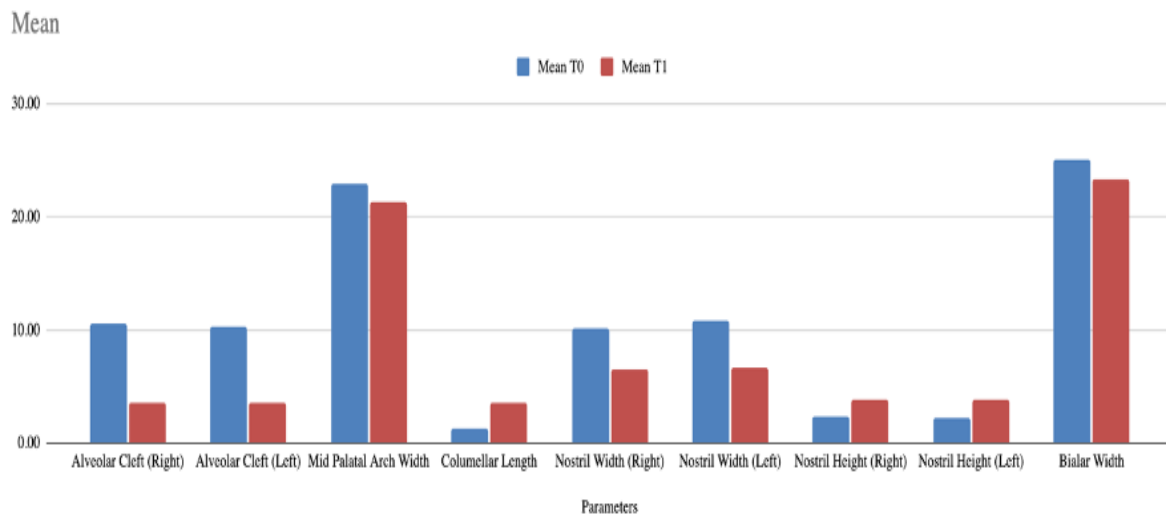


Figure 7. Parameter for Nasal measurement

RESULT



Graph 1 : This bar graph compared the mean values of various parameters between two time points (T0 and T1).

The data from Graph 1 showed a clear trend of significant improvements in craniofacial parameters following treatment. There was a substantial reduction in alveolar cleft widths, indicating successful narrowing of the clefts. Additionally, columellar length increased, improving nasal symmetry and structure. The nostril widths decreased while nostril heights increased, contributing to better nasal balance and overall facial proportionality. The bialar width also showed a reduction, further enhancing the symmetry of the nasal base.

Right Alveolar Cleft	Mean	Std. Error Mean	t	p-value	Difference		95% Confidence Interval of the Difference	
					Mean	Std. Error Mean	Lower	Upper
T0	10.56 ± 1.17	0.26	24.014	0.001	6.96 ± 1.33	0.29	6.35	7.56
T1	3.60 ± 0.85	0.18						

Table 1 : This table showed the mean, standard deviation, and statistical differences in the right alveolar cleft width at two time points, T0 and T1.

The right alveolar cleft width decreased significantly from a mean of **10.56 ± 1.17 mm (T0)** to **3.60 ± 0.85 mm (T1)**. The difference between the two measurements was **6.96 ± 1.33 mm**, with a p-value of **0.001**, indicating a highly statistically significant result. This reduction suggests that the treatment was effective in reducing the right alveolar cleft, with a **95% Confidence Interval (CI)** of **6.35 mm to 7.56 mm**.

Left Alveolar Cleft	Mean	Std. Error Mean	t	p-value	Difference		95% Confidence Interval of the Difference	
					Mean	Std. Error Mean	Lower	Upper
T0	10.27 ± 2.06	0.45	19.425	0.001	6.77 ± 1.60	0.35	6.04	7.49
T1	3.50 ± 0.74	0.16						

Table 2 : The table presented the mean, standard deviation, and standard error of the left alveolar cleft width at T0 and T1, along with the difference between these two measurements.

For the left alveolar cleft, the width decreased from 10.27 ± 2.06 mm (T0) to 3.50 ± 0.74 mm (T1). The mean difference was 6.77 ± 1.60 mm, with a p-value of **0.001**, which again points to a significant effect of the treatment. The **95% CI** for the difference was **6.04 mm to 7.49 mm**, confirming the reliability of the intervention in reducing the cleft width on the left side.

Mid Palatal Arch Width	Mean	Std. Error Mean	t	p-value	Difference		95% Confidence Interval of the Difference	
					Mean	Std. Error Mean	Lower	Upper
T0	22.95 ± 1.83	0.40	5.574	0.001	1.60 ± 1.32	0.29	1.00	2.21
T1	21.34 ± 1.46	0.32						

Table 3 : It displayed the mean, standard deviation, and statistical differences for mid-palatal arch width at T0 and T1.

The mid-palatal arch width reduced slightly from 22.95 ± 1.83 mm (T0) to 21.34 ± 1.46 mm (T1), with a mean difference of 1.60 ± 1.32 mm and a p-value of **0.001**. Although the reduction was smaller than in the alveolar clefts, it was statistically significant, with a **95% CI** of **1.00 mm to 2.21 mm**. This indicated that the intervention moderately affected the mid-palatal arch width.

Columellar Length	Mean	Std. Error Mean	t	p-value	Difference		95% Confidence Interval of the Difference	
					Mean	Std. Error Mean	Lower	Upper
T0	1.23 ± 0.29	0.06	-27.837	0.001	-2.36 ± 0.39	0.08	-2.53	-2.18
T1	3.59 ± 0.34	0.07						

Table 4 : The table provided measurements of columellar length at T0 and T1, including mean, standard deviation, and the significance of the differences.

The columellar length increased from 1.23 ± 0.29 mm (T0) to 3.59 ± 0.34 mm (T1), showing a mean difference of -2.36 ± 0.39 mm, with a highly significant p-value of **0.001**. The **95% CI** for the difference was **2.18 mm to 2.53 mm**, reflecting that the intervention resulted in a substantial lengthening of the columella, enhancing nasal structure and symmetry.

Right Nostril Width	Mean	Std. Error Mean	t	p-value	Difference		95% Confidence Interval of the Difference	
					Mean	Std. Error Mean	Lower	Upper
T0	10.36 ± 1.99	0.44	9.016	0.001	3.90 ± 1.98	0.43	3.00	4.80
T1	6.46 ± 0.74	0.16						

Table 5: This table presented the right nostril width's mean, standard deviation, and statistical differences between T0 and T1.

The right nostril width decreased from **10.36 ± 1.99 mm (T0)** to **6.46 ± 0.74 mm (T1)**, with a mean difference of **3.90 ± 1.98 mm**. The p-value of **0.001** indicated that this reduction was statistically significant, and the **95% CI** ranged from **3.00 mm to 4.80 mm**. This suggested that the treatment effectively narrowed the right nostril, contributing to improved nasal symmetry.

Left Nostril Width	Mean	Std. Error Mean	t	p-value	Difference		95% Confidence Interval of the Difference	
					Mean	Std. Error Mean	Lower	Upper
T0	10.93 ± 1.79	0.39	11.822	0.001	4.27 ± 1.65	0.36	3.51	5.02
T1	6.67 ± 0.59	0.13						

Table 6 : The table showed the mean, standard deviation, and comparison between T0 and T1 for the left nostril width.

The left nostril width showed a reduction from **10.93 ± 1.79 mm (T0)** to **6.67 ± 0.59 mm (T1)**. The mean difference was **4.27 ± 1.65 mm**, with a p-value of **0.001**, indicating statistical significance. The **95% CI** for the change was **3.51 mm to 5.02 mm**, demonstrating that the treatment consistently reduced the nostril width on the left side as well.

Right Nostril Height	Mean	Std. Error Mean	t	p-value	Difference		95% Confidence Interval of the Difference	
					Mean	Std. Error Mean	Lower	Upper
T0	2.29 ± 0.62	0.14	-14.098	0.001	-1.57 ± 0.51	0.11	-1.80	-1.33
T1	3.85 ± 0.42	0.09						

Table 7 : The mean, standard deviation, and differences in the right nostril height between T0 and T1 were presented in this table.

The right nostril height increased from 2.29 ± 0.62 mm (T0) to 3.85 ± 0.42 mm (T1), with a mean difference of -1.57 ± 0.51 mm. The p-value was 0.001, indicating a significant change. The 95% CI ranged from 1.33 mm to 1.80 mm, showing that the intervention was effective in increasing the height of the right nostril.

Left Nostril Height	Mean	Std. Error Mean	t	p-value	Difference		95% Confidence Interval of the Difference	
					Mean	Std. Error Mean	Lower	Upper
T0	2.21 ± 0.52	0.11	-15.757	0.001	-1.65 ± 0.48	0.10	-1.87	-1.43
T1	3.86 ± 0.41	0.09						

Table 8: The table provided a comparison of the left nostril height between T0 and T1, including statistical differences and confidence intervals.

The left nostril height also increased, from 2.21 ± 0.52 mm (T0) to 3.86 ± 0.41 mm (T1), with a mean difference of -1.65 ± 0.48 mm and a p-value of 0.001. The 95% CI for this difference was 1.43 mm to 1.87 mm, indicating a significant improvement in left nostril height due to the treatment.

Bialar Width	Mean	Std. Error Mean	t	p-value	Difference		95% Confidence Interval of the Difference	
					Mean	Std. Error Mean	Lower	Upper
T0	25.29 ± 1.81	0.40	4.996	0.001	1.93 ± 1.77	0.39	1.13	2.74
T1	23.36 ± 1.76	0.38						

Table 9: This table showed the mean, standard deviation, and statistical differences in the bialar width between T0 and T1.

The bialar width decreased slightly from 25.29 ± 1.81 mm (T0) to 23.36 ± 1.76 mm (T1), with a mean difference of 1.93 ± 1.77 mm and a p-value of 0.001. The 95% CI for the reduction was 1.13 mm to 2.74 mm, reflecting that the treatment caused a small but significant reduction in the overall width of the nasal base.

DISCUSSION

The main purpose of our moulding technique was to mould the nasal cartilage and narrow down the alveolar cleft so that primary cheiloplasty would be easier. The assessment of the intraoral casts showed that PNAM therapy led to a significant reduction in the premaxilla's protrusion and, where applicable, its deviation. The cleft width was greatly reduced by PNAM, which in turn aided in realigning the premaxilla and bringing it into alignment with the dental alveolar segments.

This adjustment facilitated the repositioning of the premaxilla, aligning it more effectively with the dental alveolar segments. Spengler et al also found similar result in his study.¹⁵ In this study significant reduction in right and left alveolar cleft width was observed after the intervention, with a mean decrease of 6.96 ± 1.33 mm and 6.77 ± 1.60 mm respectively.

Mid palatal arch width shows significant reduction after NAM therapy at (T0 to T1) 1.60 ± 1.3 mm which is different from the study by GRILL, who found increased by 2.7 mm ($P = 0.01$), but similar to study by Aslan et al found decreased 3.0 ± 2.75 mm.^{16,17}

The assessment of the extraoral casts showed that PNAM therapy led to a marked improvement in nasal symmetry. Columellar length were also significantly improved to 3.50 ± 0.74 mm ($P = 0.001$). This

indicates that NAM therapy significantly lengthens the columella. **Mobin et al** also found in his study that nasoalveolar moulding more effectively increases columellar height.¹⁸

Right and left nostril height was significantly increased. Mean increase by 1.57 ± 0.51 mm and increase of 1.65 ± 0.48 mm respectively found. Right and Left Nostril width significantly reduces to mean decrease of 3.90 ± 1.83 mm and 4.27 ± 1.65 mm respectively. **Grill et al** also found similar result in his study.¹⁹

A significant reduction in bialar width was observed after NAM therapy, with a mean decrease of 1.93 ± 1.77 mm ($P = 0.001$). NAM therapy demonstrates that changes in nasal shape remain stable, with reduced scar tissue and improved lip and nasal form.¹⁶ This improvement reduces the need for additional surgeries by addressing complications such as excessive scar formation, oronasal fistulas, and deformities in the nose and lips.¹⁹

CONCLUSION

In conclusion, NAM therapy serves as a critical adjunct to cleft lip and palate surgery, offering substantial preoperative benefits by modifying soft and hard tissues to create a more favourable environment for surgical repair. The therapy's ability to reduce the cleft width, optimize arch shapes, and improve nasal and columellar dimensions enhances the effectiveness of subsequent surgical interventions, leading to superior outcomes. Thus, NAM therapy should be considered an integral part of the multidisciplinary approach to managing cleft lip and palate, improving not only the surgical outcomes but also the overall quality of life for affected infants.

Ethical Approval:

As per international standards or university standards written ethical approval has been collected and preserved by the author(s).

Consent

As per international standards or university standards, respondents' written consent has been collected and preserved by the author(s).

Disclaimer (Artificial intelligence)

Option 1:

Author(s) hereby declare that NO generative AI technologies such as Large Language Models (ChatGPT, COPILOT, etc.) and text-to-image generators have been used during the writing or editing of this manuscript.

Option 2:

Author(s) hereby declare that generative AI technologies such as Large Language Models, etc. have been used during the writing or editing of manuscripts. This explanation will include the name, version, model, and source of the generative AI technology and as well as all input prompts provided to the generative AI technology

Details of the AI usage are given below:

- 1.
- 2.
- 3.

REFERENCE

1. RM G. Hullihen SP. Pioneer oral and plastic surgeon. *Plast Reconstr Surg.* 1973;52:250-7.
2. Murthy PS, Deshmukh S, Bhagyalakshmi A, Srilatha KT. Pre surgical nasoalveolar moulding: changing paradigms in early cleft lip and palate rehabilitation. *Journal of international oral health: JIOH.* 2013 Apr;5(2):70.
3. Berkowitz S. A comparison of treatment results in complete bilateral cleft lip and palate using a conservative approach versus Millard-Latham PSOT procedure. *Semin Orthod* 1996; 2(3):169–84.
4. Berkowitz S, editor. *Cleft lip and palate: diagnosis and management.* Chapter 20:455-467; Chapter 21:473-507 Springer Science & Business Media; 2006 May 20.
5. Hotz M, Perko M, Gnoinski W. Early orthopaedic stabilization of the praemaxilla in complete bilateral cleft lip and palate in combination with the Celesnik lip repair. *Scandinavian Journal of Plastic and Reconstructive Surgery.* 1987 Jan 1;21(1):45-51.
6. Matsuo K, Hirose T, Otagiri T, Norose N. Repair of cleft lip with nonsurgical correction of nasal deformity in the early neonatal period. *Plastic and reconstructive surgery.* 1989 Jan;83(1):25-31.

7. Grayson BH, Garfinkle JS. Early cleft management: The case for nasoalveolar molding. *American Journal of Orthodontics and Dentofacial Orthopedics*. 2014 Feb 1;145(2):142
8. Grayson BH, Shetye PR. Presurgical nasoalveolar moulding treatment in cleft lip and palate patients. *Indian Journal of Plastic Surgery*. 2009 Oct;42(S 01): S56-61.
9. Grayson BH, Wood R. Preoperative columella lengthening in bilateral cleft lip and palate. *Plastic and reconstructive surgery*. 1993 Dec 1;92(7):1422-3.
10. Abbott MM, Meara JG. Nasoalveolar molding in cleft care: is it efficacious? *Plastic and reconstructive surgery*. 2012 Sep 1;130(3):659-66.
11. Levy-Bercowski D, Abreu A, DeLeon E, Looney S, Stockstill J, Weiler M, Santiago PE. Complications and solutions in presurgical nasoalveolar molding therapy. *The Cleft palate-craniofacial journal*. 2009 Sep;46(5):521-8.
12. Mossey P, Little J. Addressing the challenges of cleft lip and palate research in India. *Indian Journal of Plastic Surgery*. 2009 Oct;42(S 01):S9-18.
13. Grayson BH, Maull D. Nasoalveolar molding for infants born with clefts of the lip, alveolus and palate. *Clinics in plastic surgery*. 2004 Apr 1;31(2):149-58.
14. Grayson BH, Santiago PE, Brecht LE, Cutting CB. Presurgical nasoalveolar molding in infants with cleft lip and palate. *The cleft palate-Craniofacial journal*. 1999 Nov;36(6):486-98.
15. Spengler AL, Chavarria C, Teichgraeber JF, Gateno J, Xia JJ. Presurgical nasoalveolar molding therapy for the treatment of bilateral cleft lip and palate: a preliminary study. *The Cleft palate-craniofacial journal*. 2006 May;43(3):321-8.
16. Grill FD, Rau A, Bauer FX, Hellmundt F, Hilmer B, Roth M, Behr AV, Wolff KD, Loeffelbein DJ, Ritschl LM. The absolute and relative effects of presurgical nasoalveolar moulding in bilateral cleft lip and palate patients compared with nasal growth in healthy newborns. *Journal of Cranio-Maxillofacial Surgery*. 2019 Jul 1;47(7):1083-91.
17. Aslan BI, Gülsen A, Findikçioğlu K, Uzuner D, Üçüncü N. Effects of nasoalveolar molding therapy on alveolar and palatal cleft deformities in unilateral and bilateral cleft lip and palate. *Journal of Craniofacial Surgery*. 2018 Mar 1;29(2):e179-84.
18. Mobin SS, Karatsonyi A, Vidar EN, Gamer S, Groper J, Hammoudeh JA, Urata MM. Is presurgical nasoalveolar molding therapy more effective in unilateral or bilateral cleft lip–cleft palate patients? *Plastic and reconstructive surgery*. 2011 Mar 1;127(3):1263-9.

19. Maull DJ, Grayson BH, Cutting CB, Brecht LL, Bookstein FL, Khorrambadi D, Webb JA, Hurwitz DJ. Long-term effects of nasoalveolar molding on three-dimensional nasal shape in unilateral clefts. *The Cleft palate-craniofacial journal*. 1999 Sep;36(5):391-7.

UNDER PEER REVIEW