

## The clinical and histopathological characteristics of breast lesions in Western Sudan

### Abstract

**Background:** Presenting advanced breast cancer in Sudan is a significant challenge. Consequently, the objective of this investigation was to evaluate the breast lesion pattern in Western Sudan. **Methodology:** This study was a retrospective descriptive analysis carried out in two major entities that offer histopathology services in the northern region of Kordofan State. The study encompassed a total of 190 patients, with 110 of them having malignant lesions and 79 having benign breast lesions. **Results:** Among the 110 cases of breast cancer, 59% were classified as invasive ductal carcinoma (DC), 12.7% as infiltrating DC, and 9% as invasive lobular carcinoma (LC). We identified 37.9% of the 79 non-cancerous growths as fibroadenoma, 25.3% as fibrocystic changes, and 6.3% as Phyllodes tumors. **Conclusion:** In Sudan, the advanced presentation of breast cancer is common. When a patient presents with a lump, the likelihood of a malignant diagnosis is higher. Breast cancer is a significant concern for younger Sudanese women, particularly those under the age of 45 years.

**Keywords:** breast cancer, fibroadenoma, fibrocystic change, ductal carcinoma, lobular carcinoma

### Introduction

Breast cancer is a widespread issue that affects many people around the world. The concerning increase in breast cancer cases highlights the importance of comprehensive disease management. Implementing a comprehensive cancer screening program and maintaining effective diagnostic and treatment protocols are crucial for successful management. There is variation in clinical outcomes based on the subtype of breast cancer. The presence of diverse characteristics in breast cancer emphasizes the importance of advanced molecular testing to detect it early and improve the chances of survival [1]. In recent decades, three notable patterns have emerged in breast cancer mortality. Several low- and middle-income nations (LMICs) are experiencing stable or increasing death rates, while certain high-income countries are consistently achieving significant reductions in mortality rates of over 2% per year. Research indicates that prioritizing primary health care-based breast cancer control and cancer treatment capability can have a positive impact on epidemiological outcomes and overall population health [2]. It is worth noting that breast cancer is not commonly seen in individuals under the age of 40. However, recent epidemiologic data has shed light on a concerning trend: the increasing occurrence of breast cancer among young women in the United States, leading to unfavorable long-term outcomes. Young breast cancers tend to be more advanced and aggressive, so it is advisable to consider multimodal therapy. Factors such as increased risks of local recurrence and mutations associated with hereditary cancer predisposition can influence local therapy [3]. In normal gynecologic care, benign breast disease is quite common. Signs such as a breast lump, nipple discharge, or soreness could potentially be indicative of cancer. After ruling out breast

cancer, gynecologists diagnose and treat benign breast conditions. Conservative treatment is usually sufficient for the majority of benign breast lesions. However, in cases where there is a higher risk involved, additional screening imaging and surgical removal may be necessary. Pharmacologic therapy may be beneficial for certain conditions [4]. Current practice involves diagnosing the majority of breast abnormalities detected through imaging using a percutaneous core needle biopsy (CNB). Malignant lesions diagnosed through CNB commonly undergo excision and multimodality therapy. There is a lack of agreement regarding the best approach to managing patients with high-risk and selected benign CNB lesions [5]. Breast cancer is a prevalent form of cancer that affects women worldwide, including in Sudan. Breast cancer affected 3.9 women per 100,000. The most prevalent histological diagnosis among the breast cancer patients was invasive breast carcinoma of no special type (NST), accounting for 79.5% (3517/4423) of cases. Areas in Sudan, such as the Nile River, Northern, Red Sea, White Nile, Northern, and Southern Kordofan states, have been identified as having a high risk of breast cancer [6]. Getting insights into the underlying biology of breast lesions and maintaining a strong level of suspicion for breast cancers upon patient presentation is crucial for both the patient and the surgeon. By enabling early detection, this technology can be utilized to forecast forthcoming breast disorders and so, facilitate patient surveillance. Thus, the objective of this study was to evaluate the pattern of breast lesions in Western Sudan.

## **Materials and Methods**

This study was a retrospective descriptive analysis conducted in two recognized centers that offer histopathology services in the northern region of Kordofan State: Kordofan Histopathology Center and El-Obeid International Hospital. The study involved a total of 190 patients, with 110 having malignant lesions and 79 having benign breast lesions. An extensive analysis was conducted on histopathology reports spanning from January 2019 to April 2024. We relied exclusively on the patients' earlier diagnoses as documented in their files.

All patients were confirmed by conventional histopathology. Conventional histopathology was assessed by consultant histopathologist. The histopathological examination of biopsy specimens were done to achieve the diagnostic process role, by giving benign or malignant lesions subtypes.

## **Ethical consideration**

Officials from both the Kordofan Histopathology Center and El-Obeid International Hospital have granted permission to retrieve the samples.

## **Statistical analysis**

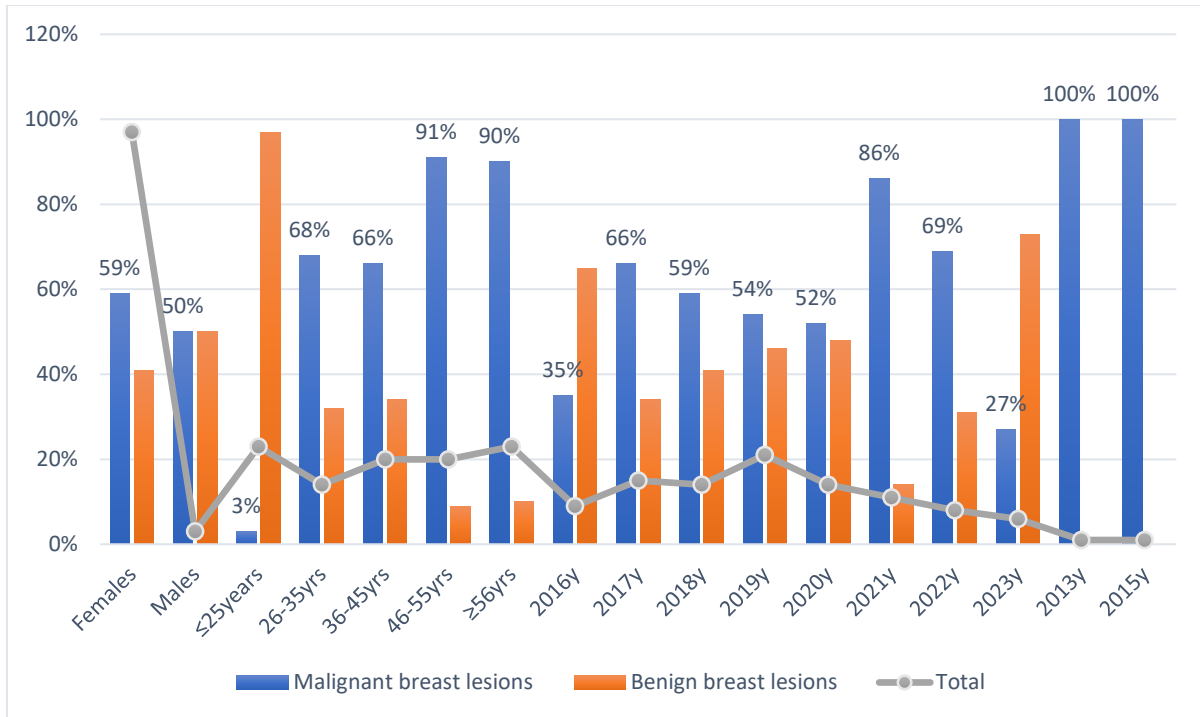
We collected and organized all the demographic data, clinical information, and histopathological data into a data sheet. The data was loaded into the SPSS program version 24 and Microsoft Excel 2016 for analysis. An analysis was conducted to generate frequencies, charts, and cross-tabs.

## Results

Of the 190 patients with breast lumps examined in this study, 184 (96.8%) were female and 6 (3.2%) were male. Their ages ranged from 14 to 90 years, with an average of  $42.3 \pm 16.5$ . Out of 190 study participants, 111 (58%) had breast cancer, whereas the remaining 79 (42%) had benign breast lesions. Malignant lesions were most common in patients aged  $\geq 56$  years, followed by 46–55 and 36–45 years, accounting for 36/110 (32.7%), 32/110 (29%), and 23/110 (20.9%), respectively. The majority of patients with benign lesions were aged  $\leq 25$  years, followed by 36–45 and 26–35 years, accounting for 38/65 (58.4%), 12/65 (18.4%), and 8/65 (12.3%), respectively. The study compared the relative risk (RR) and 95% confidence interval (95%CI) of breast cancer risk under 45 years to that of benign lesions. P-value = 5.7403 (2.8080 to 11.7345),  $P < 0.0001$ . The most malignant cases were diagnosed in 2019, 2017, and 2021, accounting for 21/110 (19%), 19 (17.2%), and 18 (16.3%), respectively. The majority of patients with benign lesions were diagnosed in the years 2019, 2020, 2018, and 2016, accounting for 18/79 (22.8%), 13 (16.5%), and 11 (13.9%), respectively, as shown in Table 1 and Figure 1.

**Table 1. Distribution of the study population by breast lesion type and patients' characteristics**

Variable	Malignant breast lesions	Benign breast lesions	Total
<b>Sex</b>			
Females	108	76	184
Males	3	3	6
Total	111	79	190
<b>Age</b>			
$\leq 25$ years	2	38	40
26-35	17	8	25
36-45	23	12	35
46-55	32	3	35
56+	36	4	40
Total	110	65	175
<b>Year of diagnosis</b>			
2016	6	11	17
2017	19	10	29
2018	16	11	27
2019	21	18	39
2020	14	13	27
2021	18	3	21
2022	11	5	16
2023	3	8	11
2013	1	0	1
2015	1	0	1
Total	110	79	189



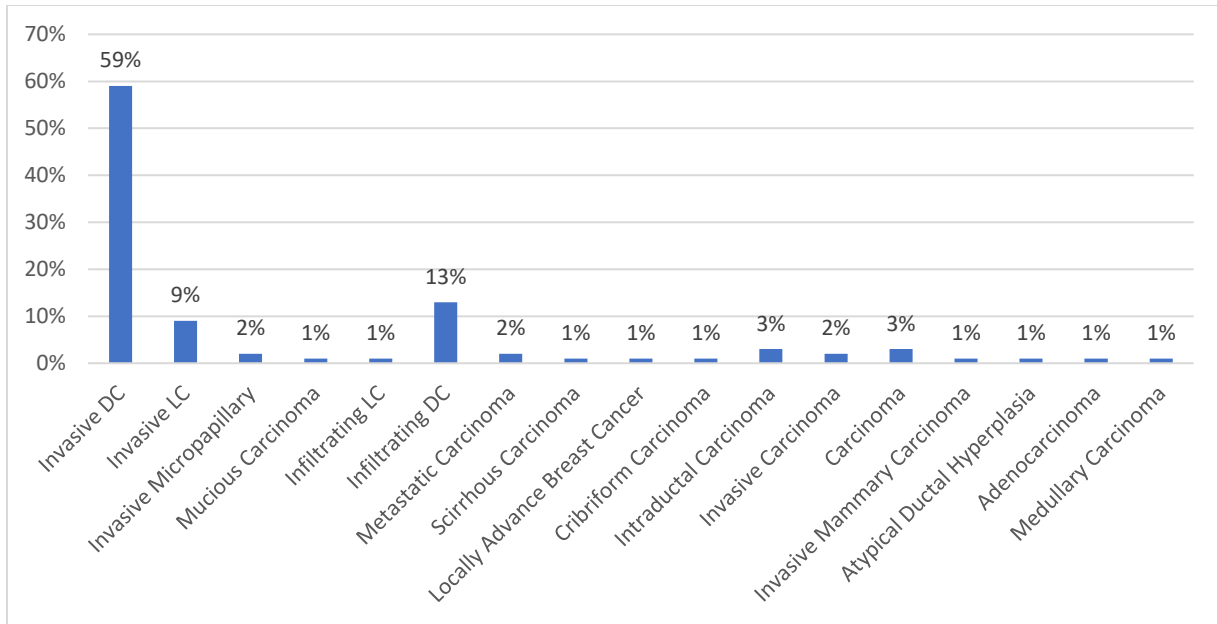
**Figure 1. Description of the study population according to breast lesion type and patient characteristics**

There were 110 breast cancers in the study (Table 2, Figures 2 and 3). Of those, 65 (59%) were invasive ductal carcinoma (DC), 14 (12.7%) were infiltrating DC, and 10 (9% were invasive lobular carcinoma). Among the 79 benign lesions, 30 (37.9%) were fibroadenoma, 20 (25.3%) were fibrocystic changes, and 5 (6.3%) were Phyllodes tumors.

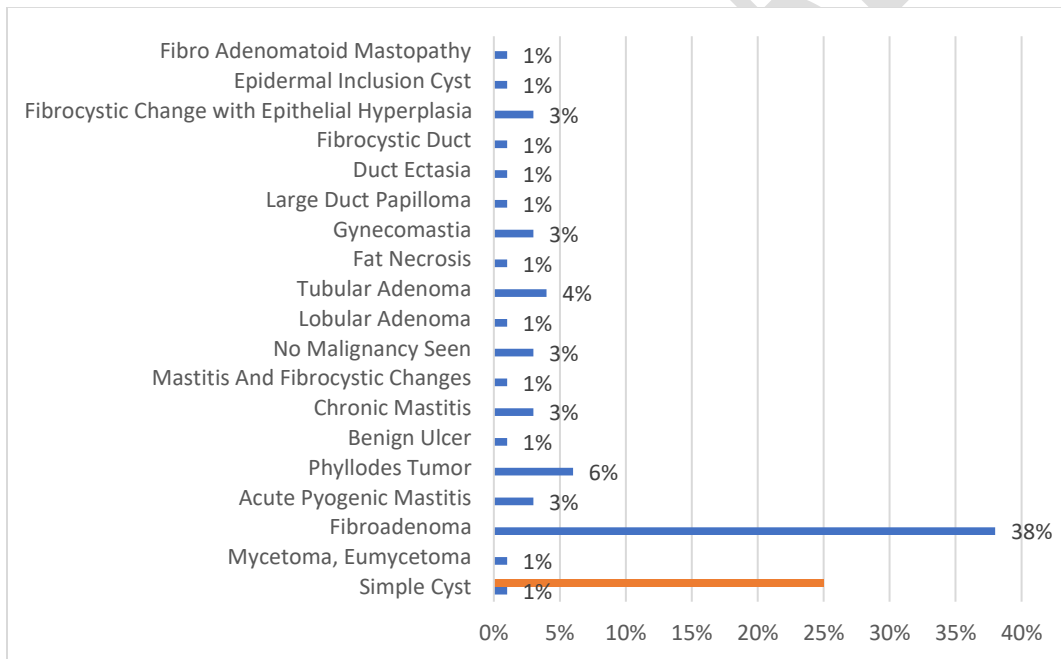
**Table 2 presents the patterns of breast lesions.**

Variable	Malignant lesions	Benign lesions	Total
Invasive Ductal Carcinoma	65	0	65
Invasive Lobular Carcinoma	7	0	7
Invasive Micropapillary	2	0	2
Mucinous Carcinoma	1	0	1
Infiltrating Lobular Breast Carcinoma	1	0	1
Invasive Lobular Carcinoma	3	0	3
Infiltrating Ductal Carcinoma	14	0	14
Metastatic Carcinoma	2	0	2
Scirrhous Carcinoma	1	0	1

Locally Advance Breast Cancer	1	0	1
Cribriform Carcinoma	1	0	1
Intraductal Carcinoma	3	0	3
Invasive Carcinoma	2	0	2
Carcinoma	3	0	3
Invasive Mammary Carcinoma	1	0	1
Atypical Ductal Hyperplasia	1	0	1
Adenocarcinoma	1	0	1
Medullary Carcinoma	1	0	1
Fibrocystic Change	0	20	20
Simple Cyst	0	1	1
Mycetoma, Eumycetoma	0	1	1
Fibroadenoma	0	30	30
Acute Pyogenic Mastitis	0	2	2
Phyllodes Tumor	0	5	5
Benign Ulcer	0	1	1
Chronic Mastitis	0	2	2
Mastitis And Fibrocystic Changes	0	1	1
No Malignancy Seen	0	2	2
Lobular Adenoma	0	1	1
Tubular Adenoma	0	3	3
Fat Necrosis	0	1	1
Gynecomastia	0	2	2
Large Duct Papilloma	0	1	1
Duct Ectasia	0	1	1
Fibrocystic Duct	0	1	1
Fibrocystic Change with Epithelial Hyperplasia	0	2	2
Epidermal Inclusion Cyst	0	1	1
Fibro Adenomatoid Mastopathy	0	1	1
Total	110	79	189



**Figure 2. Patterns of the malignant breast lesions**



**Figure 3. Patterns of the benign breast lesions**

## Discussion

The current study's findings suggest a greater prevalence of malignant breast lesions than benign ones. The new findings are interesting because they show a significant spread of breast cancer among younger adults when comparing older and younger patients in both categories. Despite an increase in breast cancer prevalence with age, around 7 to 10% of women diagnosed with

breast cancer are under the age of 40. This subgroup of individuals has distinct risk factors, tumor biology, clinical results, and psychosocial difficulties such as fertility preservation, family planning, and job reintegration. However, age should not be the sole determinant of treatment aggressiveness; other considerations, such as the biologic aggressiveness of the tumor, potential long-term toxicities, and the patient's preferences, must also be addressed. Fertility preservation strategies should be discussed with the patient before beginning any cancer treatment. Despite the fact that a considerable proportion of breast cancer patients are under the age of 40, few clinical trials have focused on disease features and outcomes in this population, and the majority of medicines commonly delivered to these younger women were studied in older patients. Furthermore, young women with breast cancer are more likely to experience sexual and psychological discomfort, and doctors must address these concerns in order to adequately accompany patients along the lengthy diagnostic and treatment journey [7]. In this study, 1.6% of the male patients had breast cancer. Male breast cancer (MBC) is uncommon, accounting for less than 1% of all breast cancer cases, but its prevalence has increased globally. Risk factors include a longer lifespan, obesity, testicular illnesses and cancers, and BRCA2 germline mutations. BRCA2 carriers have 80 times the risk as the general population. Men are more likely than women to develop breast cancer later in life. Histologically, MBC is often grade 2, hormone receptor positive, and HER2 negative, with no distinct type of carcinoma, although in situ and invasive papillary carcinomas are prevalent. The reporting and staging processes are comparable to those for female breast cancer. Metastatic lesions in the male breast can occur and should be distinguished from original carcinomas. Until recently, MBC was assumed to be comparable to the typical ER-positive postmenopausal female equivalent. However, developments in MBC research and trials have revealed important distinctions between the two. This review gives an up-to-date overview of MBC's biology, genetics, and histology in contrast to female breast tumors, as well as differential diagnosis from histological mimics [8].

The most common breast cancer subtype in this study was invasive ductal carcinoma, followed by lobular carcinoma. This histologic type accounts for 50–75% of all invasive breast cancers. Invasive lobular cancer accounts for 10% to 15% of all breast cancers and spreads throughout the breast in a single-file pattern [9, 10]. Invasive lobular cancer is the second most frequent histological type of breast cancer, behind invasive ductal carcinoma. Patients with invasive lobular carcinoma had a greater rate of mastectomy, surgical margin, and distant metastases compared to IDC patients [11]. The most common benign breast lesion found in this investigation was fibroadenoma. A fibroadenoma is a painless, unilateral, benign (non-cancerous) breast tumor that appears as a solid lump rather than fluid. It is more frequent in women aged 14 to 35 but can occur at any age [12]. Fibroadenomas are categorized as simple, complicated, large, myxoid, or juvenile. They appear as smooth, rubbery, movable masses when palpated. Fibroadenomas are distinguished by solid, spherical, well-defined masses with or without lobulated characteristics on ultrasonography and mammography. They are often treated conservatively, while clinical pathways suggest referral for a triple examination. Surgical intervention is suggested by one or more of the following characteristics: the presence of symptoms, a diameter higher than 2 cm, rapid growth rate, complex features, illness recurrence, or patient worry [13]. Furthermore, several patients in this study had fibrocystic alterations. Fibrocystic breast disease

is the most common benign form of breast illness, affecting millions of people worldwide. Certain hormonal aspects influence how this condition functions, is evaluated, and is treated. Benign breast disease refers to a variety of non-malignant conditions, including tumors, injuries, mastalgia, and nipple discharge. The aforementioned benign lesions are not connected with an increased risk of malignancy; nonetheless, they are related to a 50% risk of developing breast cancer in certain histological and clinical circumstances. Clinical examination reveals a palpable lump in both benign and malignant breast diseases. Clinical signs include dimpling of the skin (peau d'orange), thickness, discomfort, and nipple discharge [14]. Fibrocystic alterations are frequently observed in clinically symptomatic patients and during imaging workups for screening-detected abnormalities. The term "fibrocystic changes" refers to a broad range of distinct benign pathologic conditions. Recognizing traditionally benign fibrocystic abnormalities, such as cysts and layered calcifications, might help avoid unneeded follow-ups and biopsies. Imaging abnormalities such as solid masses, nonlayering calcifications, and architectural deformation may necessitate a core needle biopsy for diagnosis. In these circumstances, understanding the various appearances of fibrocystic alteration helps to determine radiologic-pathologic concordance. Fibrocystic changes are often treated conservatively [15].

**conclusion:** the advanced presentation of breast cancer is a common occurrence in Sudan. When a patient presents with a lump, the diagnosis of malignancy is more likely. Breast cancer is commonly found in Sudanese women who are younger than 45 years old.

### **Ethical Approval**

The human ethics council at the Prof. Medical Research Consultancy Center approved the study protocol, in addition to adhering to the Helsinki declaration, which was last revised in 2013. Approval Number: HREC 0015/PMRCC.9/24).

### **Consent**

As per international standards or university standards, patient(s) written consent has been collected and preserved by the author(s).

### **Disclaimer (Artificial intelligence)**

Option 1:

Author(s) hereby declare that NO generative AI technologies such as Large Language Models (ChatGPT, COPILOT, etc) and text-to-image generators have been used during writing or editing of manuscripts.

**Option 2:**

Author(s) hereby declare that generative AI technologies such as Large Language Models, etc have been used during writing or editing of manuscripts. This explanation will include the name, version, model, and source of the generative AI technology and as well as all input prompts provided to the generative AI technology

Details of the AI usage are given below:

- 1.
- 2.
- 3.

## References

1. Kashyap D, Pal D, Sharma R, Garg VK, Goel N, Koundal D, Zaguia A, Koundal S, Belay A. Global Increase in Breast Cancer Incidence: Risk Factors and Preventive Measures. *Biomed Res Int.* 2022 Apr 18;2022:9605439. doi: 10.1155/2022/9605439.
2. Trapani D, Ginsburg O, Fadelu T, Lin NU, Hassett M, Ilbawi AM, Anderson BO, Curigliano G. Global challenges and policy solutions in breast cancer control. *Cancer Treat Rev.* 2022 Mar;104:102339. doi: 10.1016/j.ctrv.2022.102339.
3. Tesch ME, Partridge AH. Treatment of Breast Cancer in Young Adults. *Am Soc Clin Oncol Educ Book.* 2022 Apr;42:1-12. doi: 10.1200/EDBK\_360970.
4. Pleasant V. Benign Breast Disease. *Clin Obstet Gynecol.* 2022 Sep 1;65(3):448-460. doi: 10.1097/GRF.0000000000000719.
5. Harbhajanka A, Gilmore HL, Calhoun BC. High-risk and selected benign breast lesions diagnosed on core needle biopsy: Evidence for and against immediate surgical excision. *Mod Pathol.* 2022 Nov;35(11):1500-1508. doi: 10.1038/s41379-022-01092-w.
6. Elbasheer MMA, Alkhidir AGA, Mohammed SMA, Abbas AAH, Mohamed AO, Bereir IM, Abdalazeez HR, Noma M. Spatial distribution of breast cancer in Sudan 2010-2016. *PLoS One.* 2019 Sep 16;14(9):e0211085. doi: 10.1371/journal.pone.0211085.
7. Rossi L, Mazzara C, Pagani O. Diagnosis and Treatment of Breast Cancer in Young Women. *Curr Treat Options Oncol.* 2019 Nov 27;20(12):86. doi: 10.1007/s11864-019-0685-7.

8. Fox S, Speirs V, Shaaban AM. Male breast cancer: an update. *Virchows Arch*. 2022 Jan;480(1):85-93. doi: 10.1007/s00428-021-03190-7.
9. Menon G, Alkabban FM, Ferguson T. Breast Cancer. [Updated 2024 Feb 25]. In: StatPearls [Internet]. Treasure Island (FL): StatPearls Publishing; 2024 Jan-. Available from: <https://www.ncbi.nlm.nih.gov/books/NBK482286/>
10. Sung H, Ferlay J, Siegel RL, Laversanne M, Soerjomataram I, Jemal A, Bray F. Global Cancer Statistics 2020: GLOBOCAN Estimates of Incidence and Mortality Worldwide for 36 Cancers in 185 Countries. *CA Cancer J Clin*. 2021 May;71(3):209-249. doi: 10.3322/caac.21660.
11. Chen BF, Tsai YF, Lien PJ, Lin YS, Feng CJ, Chen YJ, Cheng HF, Tseng LM, Huang CC. Clinical characteristics and treatment outcomes of invasive ductal and lobular carcinoma: analyses of 54,832 taiwan cancer registry index cases. *Breast Cancer Res Treat*. 2023 Oct;201(3):547-560. doi: 10.1007/s10549-023-07044-5.
12. Ajmal M, Khan M, Van Fossen K. Breast Fibroadenoma. 2022 Oct 6. In: StatPearls [Internet]. Treasure Island (FL): StatPearls Publishing; 2024 Jan-. PMID: 30570966.
13. Hudson-Phillips S, Graham G, Cox K, Al Sarakbi W. Fibroadenoma: a guide for junior clinicians. *Br J Hosp Med (Lond)*. 2022 Oct 2;83(10):1-9. doi: 10.12968/hmed.2022.0070.
14. Malherbe K, Khan M, Fatima S. Fibrocystic Breast Disease. 2023 Aug 8. In: StatPearls [Internet]. Treasure Island (FL): StatPearls Publishing; 2024 Jan-. PMID: 31869073.