

**Original Research Article**  
**Phytochemical Screening and Wound Healing Ability of Ethanol Extract of (*Moringaoleifera* Lam.) Leaves on Excisional Wound in Guinea Pig (*Caviaporcellus*)**

**ABSTRACT**

**Aims:** To evaluate the qualitative and quantitative screening of *Moringaoleifera* Lam. leaves and to investigate the healing potential of its ethanol extract on full-thickness excisional wound in a guinea pig model.

**Place and Duration of Study:** The plant sample was collected from Naraha Rural Municipality- 05, Siraha district, Nepal, and all laboratory works were carried out in Natural Products Research Laboratory, Thapathali, Kathmandu from 3 March 2023 to 1 December 2023.

**Methodology:** The leaves extract was prepared by cold extraction process at 80% ethanol. Then, the preliminary phytochemical test of the extract was performed. The total phenolic contents using the Folin-Ciocalteu method, the total flavonoid content using aluminium chloride colorimetric assay, and the antioxidant potential of the extract were also determined using diphenylpicrylhydrazyl (DPPH) reagent. Sixteen guinea pigs were used to create four full-thickness wounds on each with 1.5 cm × 1.5 cm dimensions on the lumbodorsal area. The wounds were randomly divided into four groups: A: control with no treatment, B: treated with 5% extract ointment, C: treated with 10% extract ointment and D: treated with standard (5% povidone iodine). The wound healing rate and gross evaluation of ten animals were calculated on various days of treatments whereas excisional biopsies of six animals were evaluated histopathologically.

**Results:** The extract exhibited total phenolic, total flavonoid contents, and antioxidant values of 229.14±3.61 mg GAE/g, 22.97±0.45 mg QE/g, and 606.55 µg/mL respectively. Wound healing rates of four wounds were significant on day 8, 11 and 14 ( $p < .05$ ) but non-significant on days 1, 3, and 5. Similarly, 10 % extract was found to be more effective than 5% extract, 5% povidone iodine for improvement on border and crust formation scores on wound due to faster maturation of granulation tissue, early angiogenesis, collagen deposition, and epidermis formation, and lesser acute inflammatory cells.

**Conclusion:** *M. oleifera* can be another cheap and effective alternative for wound treatment.

**Keywords:** Abramov's score, anti-oxidant value, excisional wound model, medicinal plants, wound healing rate (WHR)

## 1. INTRODUCTION

“Wound healing is a complex dynamic process, resulting in the restoration of integrity of normal anatomic structure, function, and appearance. It consists of four highly integrated, overlapping, and programmed phases: a) coagulation and hemostasis, beginning

immediately after injury b) inflammation which begins shortly thereafter c) proliferation, which starts within days of the injury and possesses the major healing processes and d) tissue remodeling or resolution, in which scar tissue formation takes place, and which may last up to a year or more"[1–3]. "Each of these events must happen precisely and timely in an orderly manner. Any disruptions or obstacles in any of these events will eventually lead to delayed wound healing or non-healing chronic wounds"[1].

"*Moringa oleifera* Lam. (Family: Moringaceae, English: Drumstick tree, Sanskrit: Shrigru), also called Sitalchini, Munga, Sahijan, or Saijan in Nepal, is a small deciduous tree usually 5–10 m tall with a light, feathery canopy. It is a highly drought-tolerant, fast-growing, multi-purpose tree native to tropical and subtropical regions of South Asia"[4]. "It can grow from warm tropical to sub-tropical up to an altitude of 3,000 feet"[5]. "The Terai, Siwalik, and Middle Mountain regions are the best-suited regions for the cultivation of *M. oleifera*"[6,7].

*M. oleifera* has been traditionally documented for wound healing purposes [8]. "Other traditional uses include applications such as a poultice on the abdomen to expel intestinal worms, rubbing over the breasts to prevent milk flow, orally consumed to treat gonorrhea, and treating dropsy along with lime. Efficacy studies of drumstick leaves have shown the plant as an antiseptic, antimicrobial, antispasmodic, antiulcer, antitumor, antihyperthyroidism, antihypertensive, diuretic, antidiabetic, antianxiety and hepatoprotective agent"[8,9,10]. "The phytochemical contents present in drumstick leaves are polyphenol, phenolic acids, vitamins, carotenoids, isothiocyanates, benzyl isothiocyanate, tannins, saponins, flavonoids, alkaloids, glucosinolates, oxalates, triterpenoids, secondary metabolites, such as anthraquinones and phytates, which are beneficial bioactive compounds for antimicrobial and antioxidant activity that help to fight against free radicals' molecules that cause oxidative stress, cell damage and inflammation"[8,9]. "Its leaf extracts have higher antioxidant activity, free-radical-scavenging capacity and higher inhibition of lipid, protein, and DNA oxidation than that of flowers and seeds"[11].

“Research on wound pathophysiology and the efficiency of new pharmacological interventions has several obstacles”[12,13]. Biopsy studies defining coordinated histological changes during the healing process of acute wound healing animal models can help in development of preclinical drugs. “Despite recent efforts, there currently remains no satisfactory method to treat or prevent the underhealing or overhealing of wounds. The inundation of the wound closure market with new products and drugs highlights the massive need for an ideal wound healing therapy, and the absence of the existence of such a treatment. Chronic wounds represent a significant and expanding biomedical burden, while the global market for anti-fibrotic therapies is over 10 billion USD”[8].

But there is a risk of losing the use, conservation and management of traditional medicine over allopathic, expensive, imported medicines. So, the sustainable use, continuous practice, and safeguarding of traditional knowledge is essential. Also, modern pharmaceutical practice needs analytical evaluation of medicinal herbs through pre-clinical and clinical trials for their scientific, continuous uses [14]. This paper aims to evaluate the qualitative and quantitative phytochemical screening of *Moringaoleifera* Lam. leaves and to investigate the healing potentials of full-thickness excision wound in Guinea pig (*Caviaporcellus*) compared with that of standard drug, 5% povidone iodine.

## **2. MATERIAL AND METHODS**

### **2.1 Plant Collection and Extraction**

“The plant was collected from Naraha Rural Municipality- 05 having latitude 26°45'49.86252” N and longitude 86°16'23.66652” E, Siraha district, Madhesh province, eastern part of Nepal. Then, the plant was identified and authenticated by a botanist at the National Herbarium and Plant Laboratories (KATH), Godawari. The extraction of plant materials was carried out using a cold extraction process”[15,16]. “The plant leaves were cleaned of extraneous materials, shade dried, and ground into fine powder using an electric blender. The powdered plant material was macerated with 80% ethanol for 72 hours with

intermittent agitation. Ethanol was used as an extraction solvent to produce extracts since polyphenols and tannins having antimicrobial activities, are best extracted in ethanol and even methanol, being good for phenols cannot be used, being toxic for in-vivo studies”[17,18]. Then, the solution was filtered through Whatman grade 1 filter paper and the residues were macerated further two times with the recovered alcohol. The filtrates were concentrated using a rotary vacuum evaporator under reduced pressure at a temperature of 40–45°C to obtain a dark green extract. Then the extract was dried to remove excess alcohol and stored in the refrigerator at 4 °C until further use.

## 2.2 Qualitative Phytochemical Screening

“The qualitative preliminary phytochemical screening was performed using standard methods for the presence of various bioactive metabolites like alkaloids, glycosides, flavonoids, tannins, phenols, saponins, carbohydrates, and steroids”[15,19].

## 2.3 Determination of Total Phenolic Content, Total Flavonoid Content and Antioxidant Activity

“The total phenolic content was determined using the Folin-Ciocalteu method, taking Gallic acid as standard for the calibration curve with a little modifications [20]. Briefly, 20 µL triplicates of 1 mg/mL plant sample solution were loaded in a 96-well plate. Gallic acid of various concentrations of 10, 20, 30, 40, 50, 60, 70 and 80 µg/mL were loaded in triplicate; used as standard control. Then, 100 µL of the Folin-Ciocalteu(FC) reagent was added to each well containing gallic acid and plant sample. An initial absorbance of the plate was taken at 765 nm using a microplate reader. After initial reading, 80 µL of sodium carbonate ( $\text{Na}_2\text{CO}_3$ ) was added separately to each well and incubated for 15 minutes. Then the final absorbance was taken at 765 nm in (Epoch2, BioTek, Instruments, Inc, USA) microplate reader”[21,22]. Then, the standard curve of the gallic acid was plotted and the TPC content in the extract was calculated using the following formula:

$$C = cV/m \quad (1)$$

Where, C = Total phenolic content expressed as milligrams of gallic acid equivalent per gram of dry weight (mg GAE/g) of the extract, c = Concentration of gallic acid derived from the calibration curve (mg/mL), V = Volume of the extract solution (mL), m = Weight of the extract in grams (g).

Total flavonoid content was also determined by Aluminium chloride colorimetric assay using quercetin as standard [21,23]. In brief, 130  $\mu$ L of different concentrations i.e., 10, 20, 40, 60, 80, 100  $\mu$ g/mL of quercetin was loaded triplicates in 96 well plate. Similarly, 20  $\mu$ L of the plant sample (1000  $\mu$ g/mL) was loaded in triplicates; and 110  $\mu$ L of distilled water was added to each well-containing plant sample. Then, 60  $\mu$ L of ethanol was added to each well containing test sample and quercetin. The initial reading was taken at 415 nm wavelength in a microplate reader. Then, 5  $\mu$ L of  $\text{AlCl}_3$  and 5  $\mu$ L of potassium acetate were added to each plate, incubated in the dark for 30 minutes and the final reading of the plate was taken at the same wavelength i.e., 415 nm. The total flavonoid content in the extract was calculated and was expressed as milligrams of quercetin equivalent per gram of dry weight (mg QE/g) of the extract.

The antioxidant assay was estimated using the DPPH (1,1-diphenyl-2-picrylhydrazil) radical scavenging method [24,25]. For it, 10  $\mu$ L of different concentrations of Vitamin C as positive control and plant extract were loaded triplicates in 96 well plate. 90  $\mu$ L of methanol was loaded to each well and initial absorbance was measured at 517 nm wavelength. After the initial reading, 10  $\mu$ L of 0.1 mM DPPH solution was added to each well and incubated for 30 minutes in the dark. After incubation, the final reading was taken and the percentage inhibition of DPPH radicals by the plant extract was calculated as:

$$\% \text{ inhibition} = \frac{A_c - A_s}{A_c} * 100 \quad (2)$$

Whereas,  $A_c$  = absorbance of control,  $A_s$  = absorbance of sample extract

## 2.4 Herbal Cream Preparations

Herbal creams (10% w/w and 5% w/w) were prepared by mixing accurately weighed dried extract (10 g and 5 g) with cream base respectively to prepare a smooth paste, gradually incorporating more cream base until formed homogeneous cream, finally were transferred in a suitable container.

## **2.5 Animal Studies**

Sixteen male guinea pigs (400 to 550 g) were selected randomly. They were kept individually in a separate cage with free access to food and water under standard conditions, 25±1°C room temperature, and natural light/dark cycles.

### **2.5.1 Acute Full Thickness Excision Wound Model**

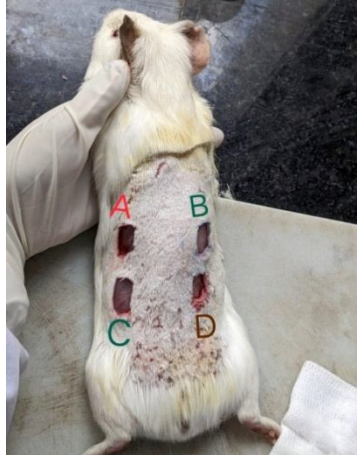The animals were anesthetized with ketamine (50 mg/kg) and xylazine (5 mg/kg), then the hair was clipped on the dorso-lumbar area with an electric shaver. The shaved area was disinfected and four square full-thickness excision wounds in the lumbar area were created with dimensions of 1.5 cm × 1.5 cm by a surgical blade in each guinea pig [26]. Six animals were euthanized using sodium pentobarbital at 200mg/kg body weight (IP) for sample collection of four wounds for histopathological analysis on the 14<sup>th</sup> day whereas 10 animals were used for evaluating gross examination of wound healing on 1, 3, 5, 8, 11 and 14 days.

#### **2.5.1.1 Studied groups**

Immediately after surgery, the wounds were randomly divided into four groups.

- Group A: negative control, the full thickness wound was not treated with anything.
- Group B: the full-thickness wound was treated with 5% w/w *M. oleifera* extract ointment.
- Group C: the full-thickness wound was treated with 10% w/w *M. oleifera* extract ointment.

- Group D: positive control, the full thickness wound was treated with 5 % povidone iodine which was regarded as a standard drug for wound healing.



**Figure 1: Random division of wounds into four groups**

From the day of the operation until 14 days after surgery, 0.1 ml of povidone iodine, 5 % w/w extract ointment, and 10 % w/w extract ointment were applied **topically** once daily. The animals were kept separately in aluminum cages with uncovered wounds during the whole of the experimental period. The animal cages were cleaned daily to prevent secondary infection.

### **2.5.2 Wound Healing Rate Determination**

The rate of wound healing (WHR) was measured on days 1, 3, 5, 8, 11, and 14 by covering the wound with a transparent plastic sheet and then the border outline was drawn around the wound [26–28]. The wound healing rate was calculated using the following formula [29,30]:

$$WHR (\%) = [(W_o - W_u) / W_o] \times 100 \quad (4)$$

Where,  $W_o$ : Original wound area and  $W_u$ : Unhealed wound area

### **2.5.3 Gross Evaluation of Wound Healing**

A wound healing score card was prepared based on clinical observations [29]. All wounds were grossly evaluated on days 1, 3, 5, 8, 11, and 14 by observing dryness, border, and crust formation on the wound.

#### **2.5.4 Histopathological Evaluation**

Six animals were euthanized on day 14 days for histopathological evaluation of wound healing treated by *M. oleifera* extract ointments. A healthy skin around the edges of the healed wounds (5 mm) was collected from each wound of every guinea pig, and fixed in 10% formalin. Then, the tissue samples were processed through the ascending order of ethanol, cleared by xylene, and impregnated with paraffin wax. After embedding in paraffin (molding), 5 micron thick sections were provided in a semi-automatic microtome. Slides were stained by using hematoxylin and eosin using the standard protocol[31].

“The histological images were assessed according to the Abramov criteria method using OPTIKA PROVIEW, version: x64, 4.8.15674.20191008. This modified histologic scoring system mainly focuses on the amount of acute and chronic inflammatory infiltrates, the amount and maturation of granulation tissue, collagen deposition, reepithelialization, and neovascularization”[29,32].

#### **2.6 Data Analysis**

The overall mean of WHR was expressed in Mean±SE. One-way ANOVA (Analysis of Variance) test was used to calculate the overall differences among treatment groups in Microsoft Excel 2021 at a .05 level of significance ( $\alpha$ ) and significant ANOVA was followed by Post- hoc Tukey’s HSD (Honest Significant Difference) test in IBM SPSS (Statistical Package for Social Sciences) version 26, at 95 % of confidence level.

### **RESULTS AND DISCUSSION**

#### **3.1 Result of Phytochemical Screening of *M. oleifera* Leaves Extract**

The phytochemical screening of hydroethanolic extract of *Moringa oleifera* leaves showed the presence of bioactive constituents like alkaloids, flavonoids, polyphenols, steroids, glycosides, anthocyanin, terpenoids, and tannins/ phenols which is in agreement with the previous study which determined the quality and quantity of some bioactive compounds in *M. oleifera* leaf by using HPLC method for the first time estimated in the

Kurdistan region [33] and also in agreement with the phytochemical study made in Nigeria [9,34].

**Table 1: Result of phytochemical screening of *M. oleifera* leaves**

SN	Phytochemicals screening	Methods	Presence
1	Fixed oils/ Volatile oil	Spot method	Volatile
2	Alkaloids	Hager's test Mayor's test	+++ +++
3	Flavonoids	Lead acetate test Shinoda test	++ +++
4	Steroids	Salkowiski's test	++
5	Glycosides	Fehling's test	++
6	Anthocyanin	Anthocyanin test	+
7	Terpenoids	Chloroform test	+++
8	Saponin	Froth test	-
9	Tannin/ Phenolic	FeCl <sub>3</sub> test	+
10	Carbohydrate	Molish test	++
11	Protein	Ninhydrin test	-

Note; +: positive, ++: mildly positive, +++: strongly positive and -: negative

## 2.2 Result of TPC, TFC, and Antioxidant Assay

The TPC and TFC assay of plant extract were 229.14±3.61 mg GAE/g and 22.97±0.45 mg QE/g respectively. The antioxidant assay (IC<sub>50</sub>) of plant extract was 606.55µg/mL with standard Vitamin C having 37.45µg/mL. In contrast to our findings, mean total polyphenols contents in young and mature leaves were found to be 1.12±0.04 gGAE/

100 gm and  $1.17 \pm 0.04$  gGAE/ 100 gm respectively using 70% ethanol by Fombang and Mbofung in 8 different localities in Cameroon which are very lesser than the findings made in our study [21]. It may be due to the higher concentration of ethanol (80%) solvent used during maceration in our study and the leaves being from different localities.

### **2.3 Result of WHR**

The WHR increased gradually during the acute inflammatory phase for 5% extract ointment, 10% extract ointment, and 5 % povidone iodine-treated wounds until day 3. In contrast, for the control group of wounds, WHR increased gradually until day 8. Likewise, the proliferative phase and the remodeling phase increased with more speed until day 14 in 5% extract, 10%, and 5% povidone iodine groups whereas, there was a gradual increase in the control group of wounds. Increased WHR rate in treatment wounds can also be related to increased presence of flavonoid compounds and their antiseptic, antimicrobial activities against *E. coli*, *P. mirabilis*, *S. aureus*, *B. cereus*, and *E. aerogenes* to prevent secondary wound infections [34]. Flavonoids increase the synthesis and cross-linking of collagen, increase the synthesis of DNA, and hence reduce cell necrosis to promote wound healing [35]. Also, flavonoids like Vicenin- 2, kaempferol, and quercetin present in leaves act as anti-microbial, and anti-oxidants which help in cell viability, proliferation, and wound scratch test assays [36]. Similarly, alkaloids act as fibroblast precursors and help in the higher production of growth factors by the skin stromal cells and phenolic acid contributes to vascularization, re-epithelization, collagen synthesis, and wound contraction [37,38].

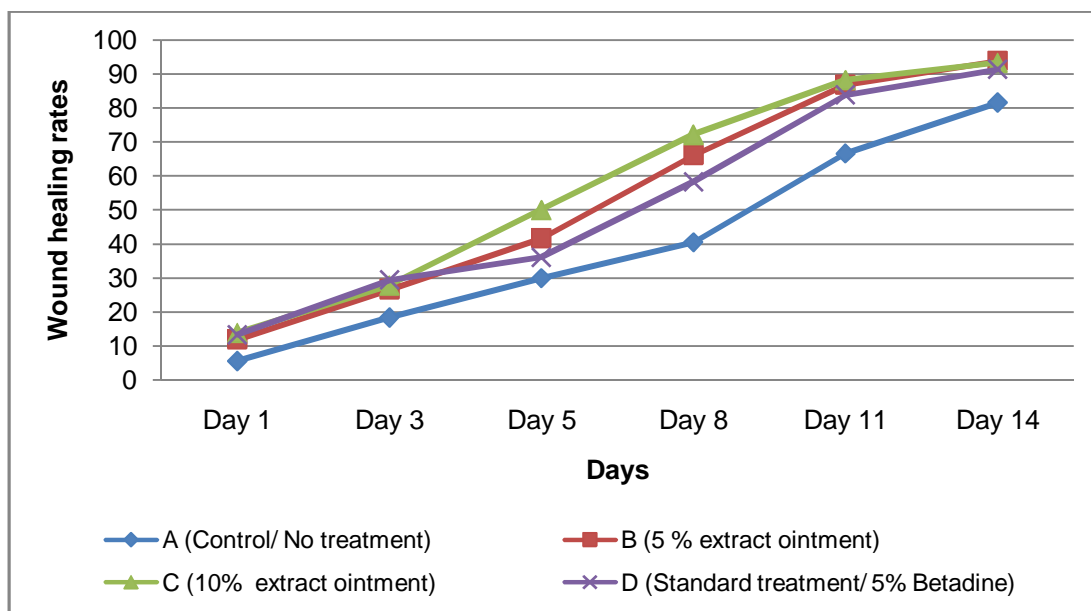


Figure 2: Line graph showing average wound healing rate on different days

## 2.4 Wound Healing Rates on Various Days after Wound Creation

The mean wound healing rates of four different wounds (A, B, C, and D) were significant to each other on days 8, 11, and 14 ( $P$  value  $\leq .05$ ) whereas the mean wound healing rates of four different wounds (A, B, C and D) were non-significant to each other on day 1, 3 and 5 ( $P$  value  $\geq 0.05$ ) as shown in Table 1. These findings are in agreement with the research in which the aqueous extract of *M. oleiferabark* showed a significant increase in the percentage closure of excision wounds by enhanced epithelialization[39].

Table 2: WHR in Guinea Pigs on various days after wound creation

Treatments	Day 1	Day 3	Day 5	Day 8	Day 11	Day 14
	Mean $\pm$ SE	Mean $\pm$ SE	Mean $\pm$ SE	Mean $\pm$ SE	Mean $\pm$ SE	Mean $\pm$ SE
A: Control	5.55 $\pm$ 1.43	18.33 $\pm$ 2.99	30.00 $\pm$ 5.62	40.55 $\pm$ 7.72	66.67 $\pm$ 6.83	81.67 $\pm$ 2.88
B: 5%	11.89 $\pm$ 4.19	26.67 $\pm$ 2.84	41.67 $\pm$ 4.99	66.11 $\pm$ 4.86	86.95 $\pm$ 1.76	93.89 $\pm$ 1.16*
C:10%	13.89 $\pm$ 4.08	27.78 $\pm$ 5.43	50.00 $\pm$ 6.14	72.22 $\pm$ 4.89	88.3 $\pm$ 1.54*	93.47 $\pm$ 1.09*
D: Standard	13.34 $\pm$ 3.53	29.45 $\pm$ 3.42	36.11 $\pm$ 4.40	58.33 $\pm$ 5.19	83.89 $\pm$ 1.54*	91.39 $\pm$ 1.78*
Pvalue	.32	.18	.07	.00	.00	0.000

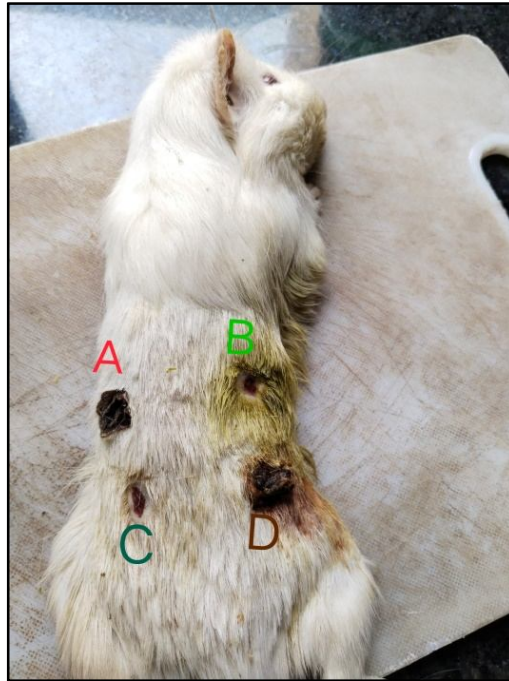
Note: \* means highly significant with control (no treatment) group,  $P < .05$

Mean  $\pm$  SE= Mean values  $\pm$  Standard error of mean of ten animals

## 2.5 Gross Evaluation of Wounds of Guinea Pigs on Various Days

All studied animals survived during the study period without any complications. In treatment groups (B and C), wound surfaces were moist, and smaller, primary crust fell off earlier followed by the formation of a secondary crust. Necrotic tissue covered most of the surface of the wounds in the control group (A) and became visible in the wound areas from the early days in the control group, while necrotic tissue were not seen on wounds treated with the extract ointment. The new epithelium was obvious at the edges of the wound with a pinkish color in the treatment (5 % and 10 % extracts) groups as shown in Figure 3.

It was found to have no improvement in the dryness score of wounds treated with *M. oleifera* extract ointment. However, wounds treated with 5% and 10% extract ointment were found to have an improvement on border since day 8. Similarly, wounds treated with 10% extract ointment were found to have improved in crust formation score since day 5 with the highest score till the end of the study period. Also, wound C i.e. wounds treated with 10% *M. oleifera* extract ointment were found to form a secondary crust earlier than other groups of wounds. These findings are in agreement with the research conducted in the Kurdistan region, Iraq, which concluded that leaves of *M. oleifera* potentially exert wound healing activity in rats due to the presence of diverse bioactive compounds [33]. Also, it is very rich in phenolic contents which act as anti-microbial, anti-oxidant, and anti-inflammatory contributing to vascularization, re-epithelization, collagen synthesis, and wound contraction [24,40].



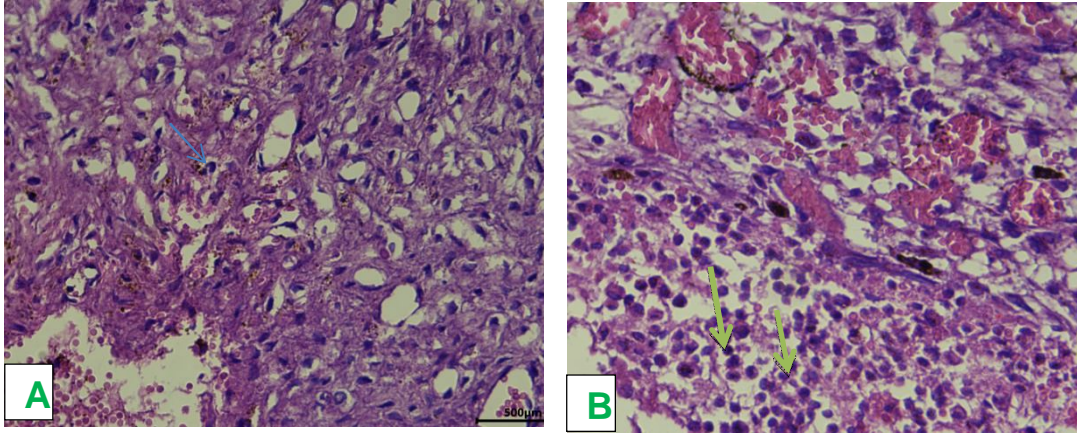
**Figure 3: Gross evaluation of wounds**

*Note: A: control wound with no treatment, B: wound treated with 5% M. oleifera extract ointment, C: wound treated with 10% M. oleifera extract ointment and D: wound treated with 5% povidone iodine*

## **2.6 Histopathological Evaluation of Various Wounds of Different Days**

### **2.6.1 Acute Inflammation Grading**

In Figure 4, A represents a section of the control wound with no treatment showing some neutrophils (blue arrow) even at 14 days of wound incision whereas B represents a section of the wound treated with 10% extract ointment showing more mononuclear cells like lymphocytes, plasma cells, and macrophages signifying towards chronic inflammation.



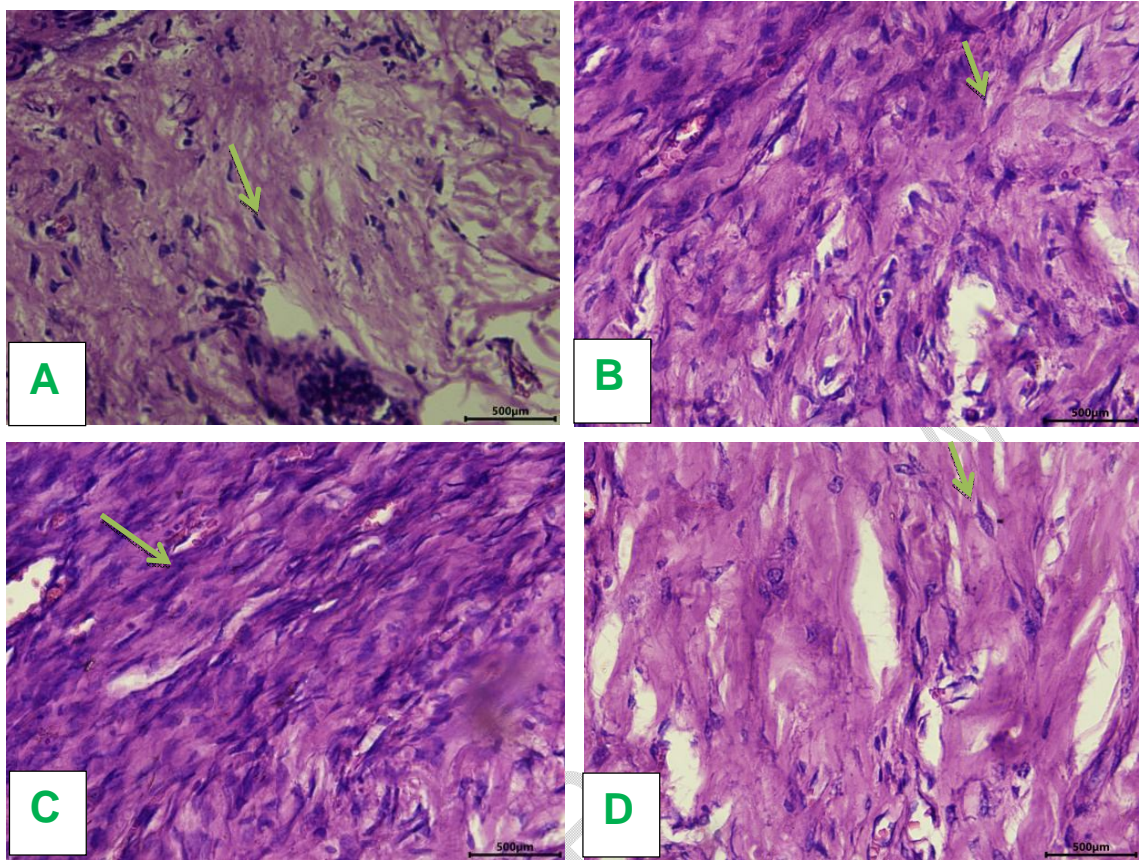
**Figure 4: Histology of skin biopsy showing acute inflammation score, (H & E, Mag; x40)**

### **2.6.2 Granulation Tissue Fibroblast Maturation**

Fibroblasts of granulation tissue were scored based on their shape and alignments. Mature fibroblasts were regarded as thin, usually arranged in compacted parallel layers whereas immature fibroblasts were stellate-shaped/ spindle shape having a nucleus and less organized. It was found that ointment-treated wounds had earlier fully matured fibroblasts whereas 5% extract ointment-treated wounds got fully matured fibroblast on day 11. Similarly, 5% povidone iodine-treated wounds got matured fibroblast on day 14 whereas control group with no treatment had no matured fibroblast during this study period.

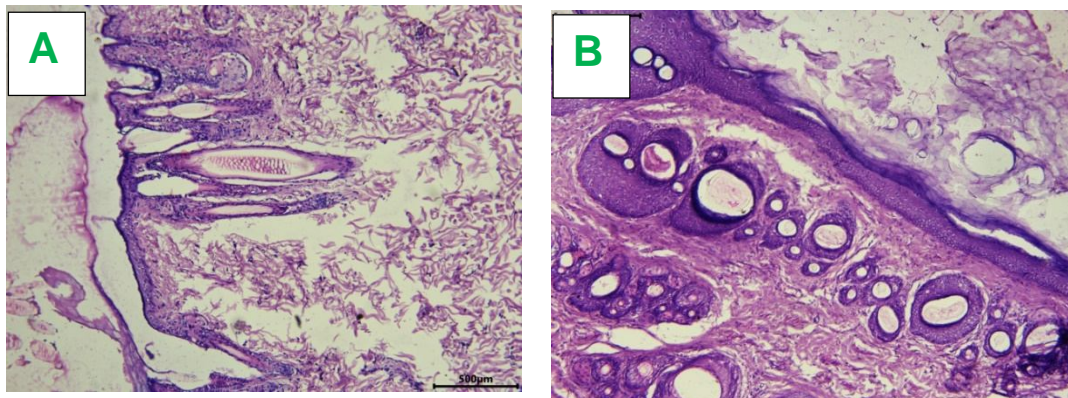
### **2.6.3 Collagen Formation Grading**

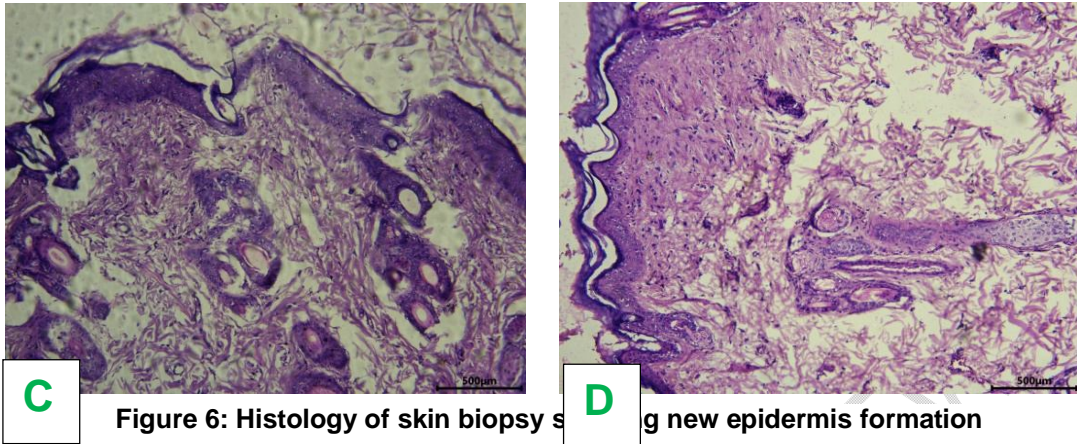
Immature collagens were thin, delicate, randomly oriented, and less intensely stained with H&E stain whereas mature collagens were thick, densely packed, well organized, and stained more intensely with H&E stain. Control wound (A) showed immature fibroblasts and less collagen formation (H & E, Mag; x40) whereas wound C (10% extract) had the most immense matured fibroblasts placed parallel and more collagen formation (H & E, Mag; x40) than in Wound B (5% extract) and wound D (5% povidone iodine) as shown in Figure 5.



**Figure 5: Histology of skin biopsy showing fibroblast and collagen deposition**  
**2.6.5 Epidermis Formation Grading**

In figure 6, control wound (A) showed the least re-epithelialization and whereas wound C (10% extract treated group) had the highest epithelial formation than in wound B (5% treated group) and wound D (5% Povidone iodine treated group). "Our results are in agreement with the research conducted to evaluate the healing properties of *M. oleifera* leaves extracts in excision wounds infected with two organisms, methicillin-resistant *Staphylococcus aureus* (MRSA) or *P. aeruginosa* in diabetic rats where it was found that the extracts helped to improve wound contraction and decreased epithelialization period with an increase in antioxidant enzyme activities, capillary density and collagen" [40].

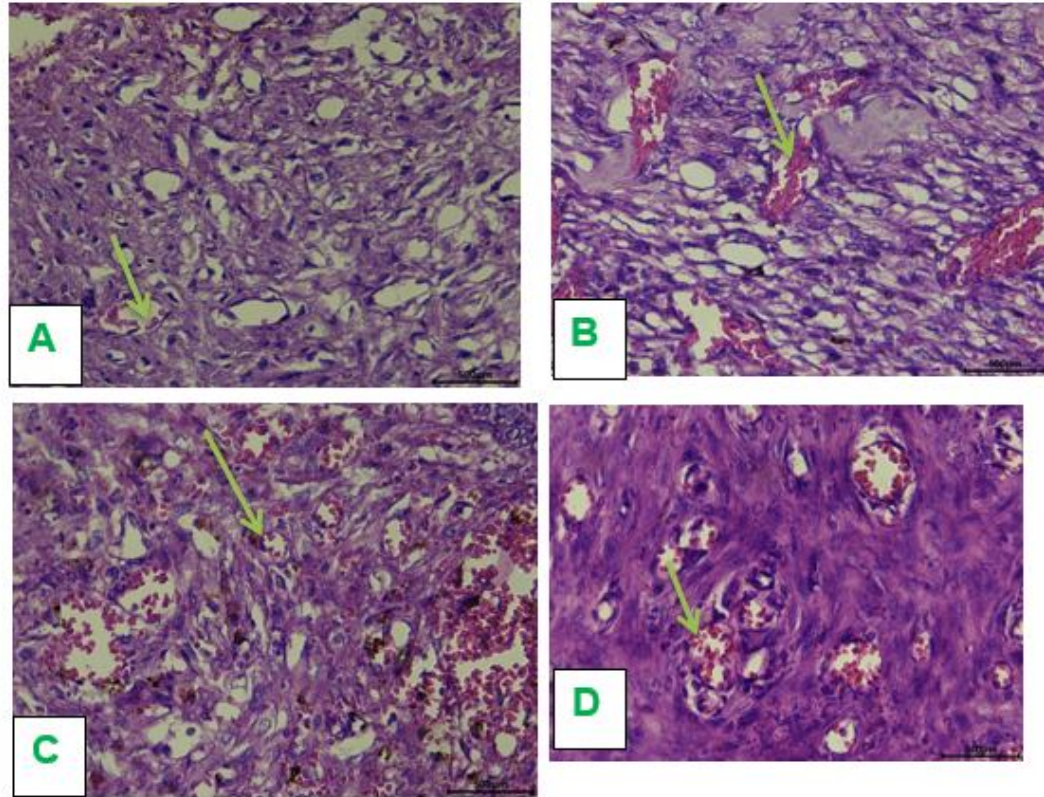




#### 2.6.4 Neovascularization Grading

Controlwound (A) showed the least neovascularization whereas wound C (10% extract ointment treated group) had the highest neovascularization than in Wound B (5% *M. oleifera* extract ointment treated group) and wound D (5% povidone iodine treated group) as shown in Figure 7.

UNDER PEER REVIEW



**Figure 7: Histology of skin biopsy showing neovascularization**

## **CONCLUSION**

From this study, it can be concluded that the healing potential of *Moringa oleifera* Lam. leaves is dose-dependent since 10% extract was found more effective than 5% extract, and 5% extract was found to be more effective than standard and control groups. Grossly, it helps in the improvement of border and crust formation on wounds especially from day 5. Histopathologically, the leaf extract shows improved wound repair showing faster maturation of granulation tissue, early angiogenesis, collagen deposition, and epidermis formation. Improved gross and histological changes in guinea pigs are due to bioactive phytochemicals especially polyphenols, flavonoids, and anti-oxidants present in its leaves. Hence, *M. oleifera* leaves can be another cheap and effective alternative for wound treatment over

expensive allopathic drugs due to their anti-inflammatory, antioxidant, and growth factor stimulation contributing to improved wound healing outcomes.

#### COMPETING INTERESTS

Authors have declared that they have no known competing financial interests OR non-financial interests OR personal relationships that could have appeared to influence the work reported in this paper.

#### ETHICAL APPROVAL

All authors hereby declare that "Principles of Laboratory Animal Care" (NIH publication No. 85-23, revised 1985) were followed. All experiments have been examined and approved by the Nepal Veterinary Council (NVC) under Ref. no. Ethical 315/2079/80.

#### Disclaimer (Artificial intelligence)

All authors hereby declare that no generative AI technologies such as Large Language Models (ChatGPT, COPILOT, etc) and text-to-image generators have been used during writing or editing of manuscripts.

#### REFERENCES

1. Guo S, DiPietro LA. Factors affecting wound healing. *J Dent Res.* 2010;89(3):219–29.
2. Rivera AE, Spencer JM. Clinical aspects of full-thickness wound healing. *Clinics in Dermatology.* 2007;25(1):39–48.
3. Velnar T, Bailey T, Smrkolj V. The wound healing process: An overview of the cellular and molecular mechanisms. *J Int Med Res.* 2009;37(5):1528–42.
4. Devkota S, Bhusal KK. *Moringa oleifera*: A miracle multipurpose tree for agroforestry and climate change mitigation from the Himalayas – A review. Yildiz F, editor. *Cogent Food & Agriculture.* 2020;6(1):1805951.
5. Cuong P. Rediscovering hidden treasures of neglected and underutilized species for Zero hunger in asia future smart food working for zero hunger. In 2018.181–193.
6. Kunwar RM, Baral B, Luintel S, Uprety Y, Poudel RC, Adhikari B, A et al. Ethnomedicinal

landscape: distribution of used medicinal plant species in Nepal. J Ethnobiology Ethnomedicine. 2022;18(1):34.

7. Uprety Y, Poudel RC, Shrestha KK, Rajbhandary S, Tiwari NN, Shrestha UB, et al. Diversity of use and local knowledge of wild edible plant resources in Nepal. J Ethnobiology Ethnomedicine. 2012 Dec;8(1):16.

8. Mohammad Shafie N, Raja Shahrman Shah RNI, Krishnan P, Abdul Haleem N, Tan TYC. Scoping Review: Evaluation of *Moringa oleifera* (Lam.) for potential wound healing in *in vivo* studies. Molecules. 2022;27(17):5541.

9. Posmontier B. The medicinal qualities of *Moringa oleifera*. Holistic Nursing Practice. 2011;25(2):80–7.

10. Fuglie LJ, Church World Service NY, Alternative Action for African Development D. The miracle tree: *Moringa oleifera*, natural nutrition for the tropics [Internet]. Dakar (Senegal) CWS; 1999 [cited 2023 Mar 29]. Available from: [https://scholar.google.com/scholar\\_lookup?title=The+miracle+tree%3A+Moringa+oleifera%2C+natural+nutrition+for+the+tropics&author=Fuglie%2C+L.J.&publication\\_year=1999](https://scholar.google.com/scholar_lookup?title=The+miracle+tree%3A+Moringa+oleifera%2C+natural+nutrition+for+the+tropics&author=Fuglie%2C+L.J.&publication_year=1999)

11. Uprety A. Moringa and mint: The magic plants [Internet]. The Himalayan Times. 2018 [cited 2023 Jun 12]. Available from: <https://thehimalayantimes.com/opinion/moringa-and-mint-the-magic-plants>

12. Meier K, Nanney LB. Emerging new drugs for wound repair. Expert Opinion on Emerging Drugs. 2006;11(1):23–37.

13. Zielins ER, Brett EA, Luan A, Hu MS, Walmsley GG, Paik K, et al. Emerging drugs for the treatment of wound healing. Expert Opinion on Emerging Drugs. 2015;20(2):235–46.

14. Shrestha B, Pandey B. Status of research on medicinal plants in Nepal: A Review. ResearchGate. 2018;1.<https://www.researchgate.net/publication/325645362>

15. Harborne AJ. Phytochemical methods: A guide to modern techniques of plant analysis [Internet]. 1998 [cited 2024 Jan 18]. Available from: <https://link.springer.com/book/9780412572609>

16. Seyfe S, Toma A, Esaiyas A, Debela E, Fikru A, Eyado A. Phytochemical screening and *in vivo* antimalarial activities of crude extracts of *Lantana trifolia* root and *Premna oligotricha* leaves in *Plasmodium berghei* infected mice. JMPR. 2017;11(47):763–9.
17. Nortjie E, Basitere M, Moyo D, Nyamukamba P. Extraction methods, quantitative and qualitative phytochemical screening of medicinal plants for antimicrobial textiles: A review. Plants (Basel). 2022;11(15):2011.
18. Nobossé P, Fombang EN, Mbofung CMF. Effects of age and extraction solvent on phytochemical content and antioxidant activity of fresh *Moringa oleifera* L. leaves. Food Sci Nutr. 2018;6(8):2188–98.
19. Mishra C, Tripathi I. Phytochemical screening of some medicinal plants of Chitrakoot region. Indian Journal of Applied Research. 2015;5(12):56–60.
20. Singleton VL, Rossi JA. Colorimetry of total phenolics with phosphomolybdic-phosphotungstic acid reagents. Am J Enol Vitic. 1965;16(3):144–58.
21. Fombang EN, Mbofung CMF. Particular benefits can be attributed to *Moringa oleifera* lam leaves based on origin and stage of maturity. JEBAS. 2015;3(6):541–55.
22. Mujic I, Dudaš S, Zivkovic J, Tomlin J, Zekovic Z, Alibabic V, et al. Determination of total phenolic compounds in cultivars of *Castanea sativa* Mill. Acta Horticulturae. 2009;815. 63 p.
23. Nobossé P, Fombang EN, Mbofung CMF. Effects of age and extraction solvent on phytochemical content and antioxidant activity of fresh *Moringa oleifera* L. leaves. Food Science & Nutrition. 2018;6(8):2188–98.
24. Ghimeray AK, Jin C, Ghimire BK, Cho DH. Antioxidant activity and quantitative estimation of azadirachtin and nimbin in *Azadirachta indica* A. Juss grown in foothills of Nepal. African Journal of Biotechnology [Internet]. 2009 [cited 2023 Mar 29];8(13). Available from: <https://www.ajol.info/index.php/ajb/article/view/60994>
25. Jadid N, Hartanti SR, Abdulgani N, Wikanta W, Sulthoni FR. *In vitro* antioxidant activity of methanolic extract of *Piper retrofractum* Vahl. 2015;
26. Talebpour Amiri F, Shahani S, Enayatifard R, Ghasemi M, Hanafi N. Licorice cream

- promotes full-thickness wound healing in Guinea pigs. JRP. 2018;22(1):84–94.
27. Majeske C. Reliability of wound surface area measurements. Physical Therapy. 1992;72(2):138–41.
28. Recommended Anesthesia | University of Kentucky Research [Internet]. [cited 2023 Apr 2]. Available from: <https://www.research.uky.edu/division-laboratory-animal-resources/recommended-anesthesia>
29. Jamadagni PS, Jamadagni S, Mukherjee K, Upadhyay S, Gaidhani S, Hazra J. Experimental and histopathological observation scoring methods for evaluation of wound healing properties of *Jatyadi ghrita*. Ayu. 2016;37(3–4):222–9.
30. Mehrabani M, Seyyedkazemi SM, Nematollahi MH, Jafari E, Mehrabani M, Mehdipour M, et al. Accelerated burn wound closure in mice with a new formula based on traditional medicine. Iran Red Crescent Med J. 2016;18(11):e26613.
31. Gal P, Kilik R, Mokry M, Vidinsky B, Vasilenko T, Mozes S, et al. Simple method of open skin wound healing model in corticosteroid-treated and diabetic rats: standardization of semi-quantitative and quantitative histological assessments. Vet Med. 2008;53(12):652–9.
32. Abramov Y, Golden B, Sullivan M, Goldberg RP, Sand PK. Vaginal incisional wound healing in a rabbit menopause model: A histologic analysis. Int Urogynecol J. 2012(12):1763–9.
33. Tofiq SA, Hoshayr A., Othman HH. Wound healing activities of *Moringa oleifera* leaves extract cultivated in Kurdistan region-Iraq. JJBS. 2021;14(04):637–45.
34. fowoyo p, oladoja e. phytochemical screening, nutritional composition and antimicrobial activity of *Moringa oleifera* seed and leaf extract against selected gastrointestinal pathogens. IOSR Journal of Pharmacy and Biological Sciences. 2015;10:116–24.
35. Lodhi S, Jain A, Jain AP, Pawar RS, Singhai AK. Effects of flavonoids from *Martynia annua* and *Tephrosia purpurea* on cutaneous wound healing. Avicenna J Phytomed. 2016;6(5):578–91.
36. Sermkaew N, Plyduang T. Self-micro emulsifying drug delivery systems of *Moringa*

*oleifera* extract for enhanced dissolution of kaempferol and quercetin. *Acta Pharm.* 2020;70(1):77–88.

37. Budovsky A, Yarmolinsky L, Ben-Shabat S. Effect of medicinal plants on wound healing. *Wound Repair Regen.* 2015;23(2):171–83.

38. Kaparekar PS, Anandasadagopan SK. The potential role of bioactive plant-based polyphenolic compounds and their delivery systems—as a promising opportunity for a new therapeutic solution for acute and chronic wound healing. *Curr Pharmacol Rep.* 2022;8(5):321–38.

39. Lambole V, Kumar U. Effect of *Moringa oleifera* Lam. on normal and dexamethasone suppressed wound healing. *Asian Pacific Journal of Tropical Biomedicine.* 2012;2(1, Supplement):S219–23.

40. Al-Ghanayem AA, Alhussaini MS, Asad M, Joseph B. *Moringa oleifera* leaf extract promotes healing of infected wounds in diabetic rats: Evidence of antimicrobial, antioxidant and proliferative properties. *Pharmaceuticals.* 2022;15(5):528.

UNDER PEER REVIEW