

# Clinical study on the occurrence Prevalence and pattern of pigmentary keratitis in pugs

## ABSTRACT

**Aim:** To study the clinical occurrence and pattern of pigmentary keratitis (PK) in pugs.

**Place and Duration of Study:** Department of Veterinary Surgery and Radiology, College of Veterinary Science, Guru Angad Dev Veterinary and Animal Sciences University, Ludhiana, Punjab, India, during the year 2020-21.

**Methodology:** This study was conducted on 200 eyes of hundred Pug breed of dogs presented for ailments other than ocular affections to study the prevalence of PK. Digital photographs of the eyes were used to study and score the corneal pigmentation (CP) and classify them into various patterns based on a previously established grading system.

**Results:** CP was detected in a total of 96 Pugs (192 eyes) in the study population, with a ~~and the~~ mean age ~~of of the animals was~~  $5.27 \pm 0.29$  years. The severity of pigmentation was mild for ~~29 eyes~~ (15.10%), moderate for ~~76 eyes~~ (39.58%), and severe for ~~87 eyes~~ (45.31%), with their mean pigmentation score being  $2.98 \pm 0.21$ ,  $6.89 \pm 0.18$ , and  $13.35 \pm 0.16$ , respectively. Detection of PK was not significantly associated ( $P > 0.05$ ) with the sex, coat colour, or the side of the eye, but was significantly associated ( $P < 0.05$ ) with the age of the animal. The severity of CP and the pattern of pigmentation ~~was were~~ not significantly associated with the coat colour or the side of the eye, but ~~was were~~ significantly associated with the age and sex of the animal.

**Conclusion:** PK had a higher prevalence among the study population, and the age and ~~the~~ sex of the animals can be used as reliable predictors of the score of CP in Pugs.

**Keywords:** Eye, pattern of pigmentation, pigmentary keratitis, ~~pattern of pigmentation~~, pugs

## 1. INTRODUCTION

Current trends in ~~the~~ ocular disorders are more ~~breed-breed~~-related, owing mainly to the artificial selection and inbreeding of ~~the pure-bred~~ dogs (Rooney & Sargan, 2009). Ocular disorders affecting the dogs may average ~~to 6.6% percent~~ different eye disorders for each breed, but there are almost 18 or more disorders that may affect the brachycephalic breeds (Whitley et al., 1995). Various reasons reported for the higher incidence of ocular affections among the brachycephalic breeds are shallow orbit, prominent globe, macropalpebral fissure, and lower craniofacial ratio, with an absence of muzzle, all contributing towards an increased scleral show compared to the other breeds of dogs.

Corneal affections account for the majority of the ocular disorders as they act as a window for any traumatic injury to the eye. Brachycephalic breeds are more prone to corneal dry spot formation and exposure keratopathy as they exhibit lagophthalmos while sleeping (Maggs, 2018; Plummer, 2015; Van Der Woerd, 2004).

PK, also termed as corneal melanosis or pigmentation, is one of the most common ocular disorders reported in pugs that is characterized by progressive deposition of melanocytes

and melanin pigment, usually starting from the nasal quadrant of the cornea. The condition was affectionately termed as 'pigmentary keratitis', ~~making reference~~referring to the higher incidence of this condition in pugs (Appelboom, 2016).

PK is not a 'clinical diagnosis' but a mere clinical sign ~~to of~~ the underlying chronic inflammatory process (Maggs, 2018). Migration of the melanocytes into the superficial corneal epithelium or more deeply into the corneal stroma occurs as a response to the chronic corneal irritation and inflammation incited by various ocular affections such as nasal fold trichiasis, medial caruncular trichiasis, distichiasis, ectopic cilia and insufficient tear production (either quantitative or qualitative) and entropion of the eyelids at the nasal canthus (Stades & Woerd, 2013; Westermeyer et al., 2009).

Development of the CP may occur following corneal trauma as a part of the wound-healing response (Kaswan et al., 1989). Corneal vascularisation and fibrosis usually precedes and ~~accompanies~~accompany the corneal epithelial melanosis. The pigmentation of the cornea is also reported frequently as a feature of various inflammatory corneal affections, such as chronic superficial keratitis (pannus), keratoconjunctivitis sicca (KCS), and chronic ulcerative/ non-ulcerative keratitis (Maini et al., 2019). A relatively higher incidence of cases of PK without KCS warrants the presence of some other yet to be determined factors involved in the development of corneal melanosis in pugs (Krecny et al., 2015).

Thus, we aimed to study the clinical occurrence and pattern of pigmentary keratitis (PK) in pugs.

## 2. MATERIAL AND METHODS

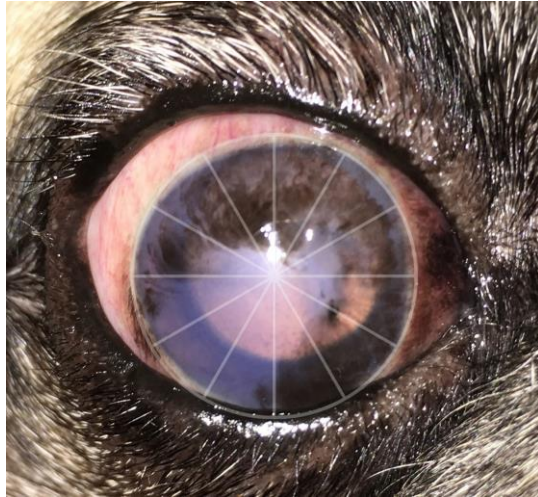
### 2.1. Study Population & Method

The screening study was conducted on clinical cases of the Pug breed of dogs presented to the Department of Veterinary Surgery and Radiology, GADVASU, Ludhiana, for ailments other than ocular affections. Age, sex, and other identification details were recorded, and detailed anamnesis was collected from each case presented for ailments other than ocular affections. Each animal underwent a detailed physical examination to establish a diagnosis. The eyes of the pugs were rinsed with sterile 0.9% normal saline solution, and pictures of the eyes were taken to study the extent of CP. The animals were categorized into three age groups as the younger group (0 to 3 years), the adult group (3 to 7 years), and the senile group (above 7 years).

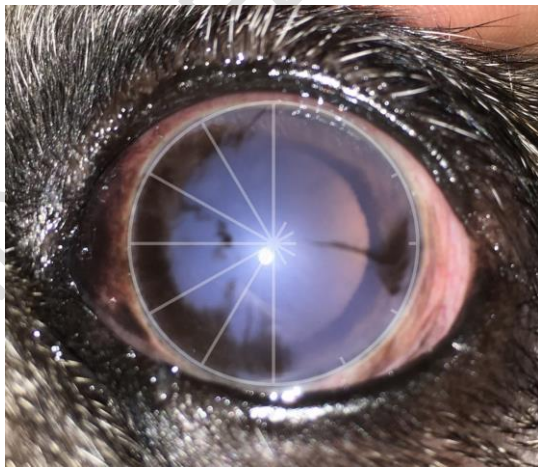### 2.2. Grading of corneal pigmentation

The degree of corneal melanosis was assessed with the help of a grading system suggested by Maini et al. (2019). A circle was drawn with the limbus as the circumference, and the corneal surface was divided into 12 'clock hours' or sectors. The extent of CP was assessed based on the number of 'clock hours' affected with melanosis, and the points were awarded as follows. One point (1 Point) was awarded when the pigment was seen affecting a particular clock hour. One additional point was awarded when the pigment extended up to the resting pupil edge. Two additional points were awarded when the pigment extended beyond the resting pupil edge, affecting the visual axis (Figure 1). Half point (½ Point) was awarded for a single line of pigment in a clock hour (Figure 2). In the eyes that had limbal brush border pigmentation, one point was awarded for each clock hour affected. In a few eyes, grey-white corneal lesions were observed along with the pigmentation. These lesions were considered as a precursor to the CP, and the points were allotted similarly to the CP (Figure 3). The total score of CP for the eyes was then calculated, and the

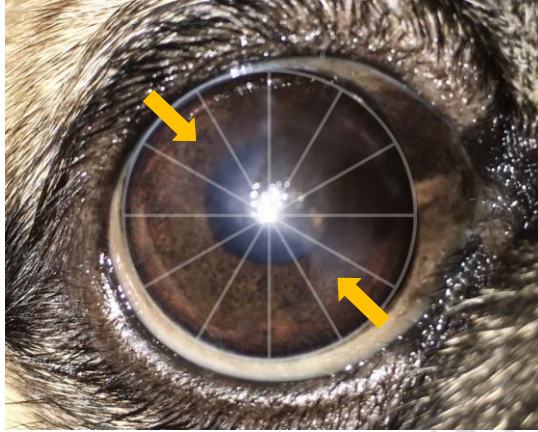
severity of corneal melanosis was graded based on the total score as mild (0.5 - 4.5), moderate (5.0 - 9.5), and severe (10.0 - 14.0) degrees of pigmentation.



(Fig. 1.) 11 clock hours were affected in this eye by corneal melanosis (11 points). Two additional points were given as the pigment can be seen extending beyond the resting pupil edge. Total = 13 points



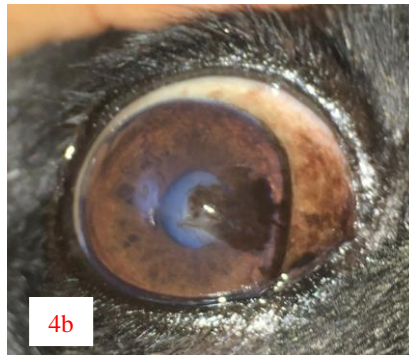
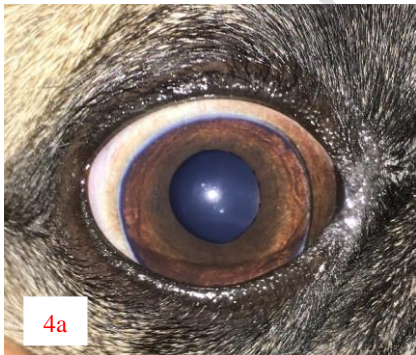(Fig. 2.) 7 clock hours were affected in this eye by corneal melanosis near the medial canthus (7 points). 0.5 point was given to the single line of pigment near the temporal canthus. Two additional points were given as the pigment can be seen extending beyond the resting pupil edge. Total = 9.5 points



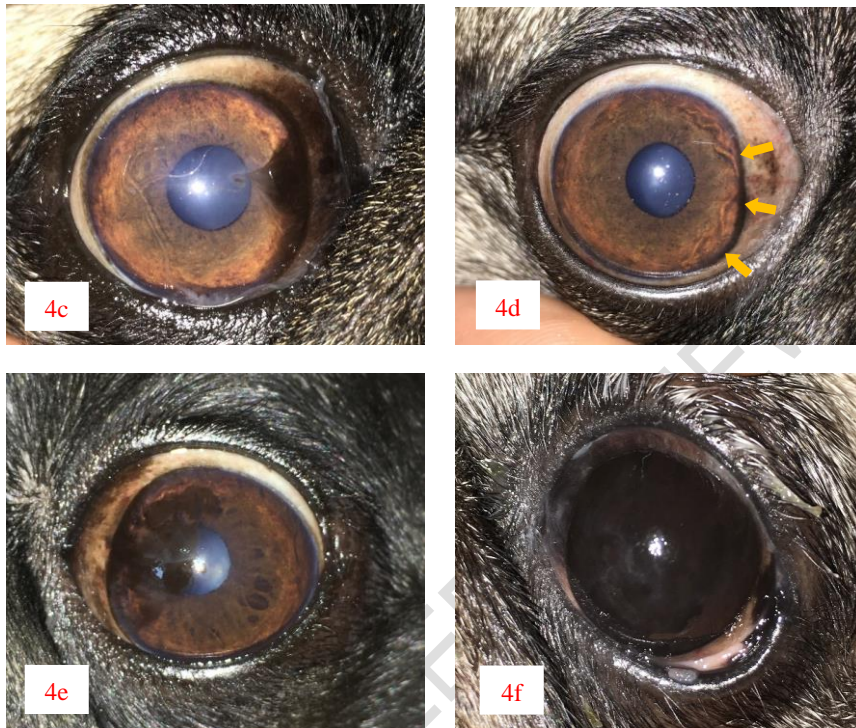
(Fig. 3.) 5 clock hours can be seen affected with pigmentation (5 points). 2 additional clock hours can be seen affected with grey/white corneal lesions (arrows), which were considered as a precursor to the pigmentation, and points were allocated similar to pigmentation (2 points). Two additional points were given as the pigment can be seen extending beyond the resting pupil edge. Total = 9 points

### 2.3. Pattern of corneal pigmentation

The pattern of CP was studied in all the eyes affected with PK and was categorised as suggested by Charbiwala (2019) into 'medial pyramidal', 'paintbrush', 'streak or limbal brush border', 'diffuse', and 'patchy' patterns of pigmentation. In the eyes that exhibited a mixture of patterns, the most prominent pattern among them was recorded (Figure 4).







(Fig. 4.) Photographs showing different patterns of CP. (a) Normal cornea of a Pug, (b) Medial pyramid pattern of pigmentation, (c) Paintbrush pattern of pigmentation, (d) Limbal brush border (or) Streak pattern of pigmentation indicated by arrows, (e) Patchy pattern of pigmentation, (f) Diffuse pattern of pigmentation

#### 2.4. Statistical analysis

The normality of the data collected was tested with the Shapiro-Wilk test, and the descriptive statistical measures such as the mean, range, and standard error were determined for the continuous variables. A Pearson's chi-square test or Fisher's exact test was performed to assess the presence or absence of an association between various predictors (Age, sex, coat colour, side of the eye) and the presence, severity, and pattern of CP. The predictors that had a significant association in the non-parametric tests ( $\chi^2$  or Fisher exact test values of  $P < 0.05$ ) were further subjected to correlation and regression studies. For the purpose of statistical measures, the categorical variables (nominal/ordinal) were scored as described in Table 1. Based on the results of regression analysis, a model was built to predict the pigmentation score of the eyes. All the statistical measures were performed using the statistical software IBM SPSS Statistics 26.

**Table 1. Scores assigned for various categorical variables for statistical purposes**

Variables	Scoring system
Sex of the animal	1 = male; 2 = female
Coat colour	1 = black; 2 = fawn
Detection of PK	0 = absent (Transparent cornea) 1 = present (Pigmented cornea)
Severity of PK	0 = no pigmentation; 1 = mild; 2 = moderate; 3 = severe
Pattern of PK	0 = transparent cornea; 1 = diffuse pattern; 2 = medial pyramid; 3 = paintbrush; 4 = patchy pattern; 5 = limbal brush border

### 3. RESULTS

One hundred clinical cases of Pugs were included in the study, and they included 53 sexually intact males (53%; 95% CI, ~~43.29% to 62.49%~~) and 47 sexually intact females (47%; 95% CI, ~~37.51% to 56.71%~~). Eighty Pugs had a fawn coat colour (80%; 95% CI, ~~71.12% to 86.66%~~) and 20 Pugs (20%; 95% CI, ~~13.34% to 28.88%~~) had a black coat colour. Of the 100 Pugs, 16 (16%; 95% CI, ~~10.00% to 24.42%~~) were of the younger age group, 56 (56%; 95% CI, ~~46.23% to 65.33%~~) were adults, and 28 (28%; 95% CI, ~~20.14% to 37.49%~~) were senile animals. The mean age of the animals was  $5.27 \pm 0.29$  years (~~range, 0.42 to 10.0 years~~). Ninety-six Pugs (96%; 95% CI, ~~90.16% to 98.43%~~) were detected with CP of various degrees, and 4 Pugs (4%; 95% CI, ~~1.57% to 9.84%~~) had a clear and transparent cornea. CP was observed as a brown to black opacification of the cornea originating from the medial canthus of the eyes and progressing into the visual axis pathway of the affected eyes. Bilateral CP with varying patterns of pigmentation was observed in ~~43/46~~ (81.25%) young animals, ~~55/56~~ (98.21%) adult animals, and ~~28/28~~ (100%) senile animals. Among the animals that had a clear and transparent cornea, 3 were young animals and 1 was an adult. Corneal melanosis was detected in ~~52/53~~ (98.11%) males and ~~44/47~~ (93.62%) females, while CP was detected in 19/20 (95%) Pugs that had a black coat colour and ~~77/80~~ (96.25%) Pugs that had a fawn coat colour.

Detection of CP was not significantly associated with the side of the eye, sex, and coat colour of the animal (Table 2). Detection of CP was significantly associated with the age of the animal ( $P = 0.0002$ ). The severity of CP was not significantly associated with the side of the eye or the coat colour of the animal, but it was significantly associated with the age ( $P = 0.00003$ ) and the sex of the animal ( $P < 0.00001$ ).

The photographs of the cornea were studied for the severity and pattern of pigmentation. Of the 96 affected left eyes, CP was mild for ~~43~~ (13.54%), moderate for ~~40~~ (41.67%), and severe for ~~43~~ (44.79%) eyes. The mean pigmentation score of the affected left eyes was  $8.9 \pm 0.52$  (95% CI, ~~7.86 to 9.94~~). Of the 96 affected right eyes, CP was mild for ~~16~~ (16.67%), moderate for ~~36~~ (37.5%), and severe for ~~44~~ (45.83%) eyes. The mean pigmentation score of the affected right eyes was  $8.78 \pm 0.52$  (95% CI, ~~7.75 to 9.81~~). Among the younger age group, CP was mild for ~~12~~ (46.15%), moderate for ~~9~~ (34.62%), and severe for ~~5~~ (19.23%)

eyes. Corneal melanosis was mild for ~~42~~ (10.91%), moderate for ~~40~~ (36.36%) and severe for ~~58~~ (52.73%) eyes in the adult group, while CP was mild for 5 (8.93%), moderate for ~~27~~ (48.21%), and severe for ~~24~~ (42.86%) eyes in the senile group. The severity of pigmentation was mild to moderate in the young animals, with a mean pigmentation score of  $5.15 \pm 0.87$ , while the severity of melanosis was moderate to severe in the adult and senile group, with a mean pigmentation score of  $9.60 \pm 0.47$  and  $9.43 \pm 0.60$  respectively.

**Table 2. Animal variables and their association with CP parameters**

Predictor	Detection of pigmentation ( <i>P</i> -value)	Severity of pigmentation ( <i>P</i> -value)	Pattern of Pigmentation ( <i>P</i> -value)
Age of the animal (years)	0.000265	0.00003	< 0.00001
Sex of the animal (male vs female)	0.151	< 0.00001	0.00008
Coat colour (black vs fawn)	0.6615	0.075	0.16549
Side of the eye (left vs right)	1.0	0.766	0.9528

The *P*-values were determined with chi-square or ~~fisher-Fisher's~~ exact tests. Values of *P* < 0.05 are considered

significant.

In male Pugs, CP was mild for 4 (3.85%), moderate for ~~39~~ (37.5%) and severe for ~~64~~ (58.65%) eyes, while in the female Pugs, CP was mild for 25 (28.41%), moderate for ~~38~~ (43.18%) and severe for ~~25~~ (28.41%) eyes. The mean pigmentation score of the eyes in males and females was  $10.34 \pm 0.44$  and  $7.13 \pm 0.53$ , respectively. In the Pugs that had a black coat colour, corneal melanosis was mild for ~~7~~ (18.42%), moderate for ~~20~~ (52.63%) and severe for 11 (28.95%) eyes while in the Pugs that had a fawn coat colour, CP was mild for ~~22~~ (14.29%), moderate for 56 (36.36%) and severe for ~~76~~ (49.35%) eyes. The mean pigmentation score of the eyes in black and fawn coat colour Pugs was  $7.48 \pm 0.78$  and  $9.18 \pm 0.41$ , respectively. Out of the 192 eyes that exhibited CP, ~~66~~ (34.38%) eyes had a diffuse pattern, ~~44~~ (21.35%) had a patchy pattern, 40 (20.83%) had a medial pyramid pattern, ~~24~~ (12.50%) had a streak or limbal brush border pattern, and ~~24~~ (10.94%) eyes had a paintbrush pattern of pigmentation. Whorl pattern and endothelial deposit patterns were not identified in any of the study cases.

Bivariate correlation studies indicated that pigmentation score and severity of pigmentation of left eyes had a significant positive correlation with the age of the animals, but a significant positive correlation was observed only between the pigmentation score of right eyes and the age of the animals (Table 3).

**Table 3. Bivariate correlation analysis between predictors and pigmentation variables**

Pigmentation variables	Predictors of Pigmentation		
	Age of the animal	Sex of the animal	Coat colour
Detection of PK	0.221	- 0.082	0.068
Pigmentation score of <u>the</u> Left eyes	0.269*	- 0.339**	0.161
Severity of pigmentation in <u>the</u> Left eyes	0.261*	- 0.409**	0.175
Pattern of pigmentation in <u>the</u> Left eyes	- 0.027	0.143	- 0.027
Pigmentation score of <u>the</u> Right eyes	0.234*	- 0.363**	0.140
Severity of pigmentation in <u>the</u> Right eyes	0.192	- 0.325**	0.134
Pattern of pigmentation in <u>the</u> Right eyes	- 0.119	0.129	- 0.083

\*. Correlation is significant at the 0.05 level (2-tailed) & \*\*. Correlation is significant at the 0.01 level (2-tailed)

Pigmentation score and severity of pigmentation of both right and left eyes had a highly significant negative correlation with the sex of the animal. The results of the regression analysis were significant for the predictor variables (age & sex) for each eye, though the regression models accounted for less than 20% of the variation in the pigmentation score of the eyes (Tables 4 & 5). The regression models built to predict the pigmentation score of the eyes is-are shown in Table 6.



**Table 4. Regression analysis of the influence of age and sex on the pigmentation score of eyes**

Predictors	Regression coefficient (B)		95% CI	P - value
	Pigmentation score			
Age	OS	0.545	0.172 – 0.919	0.005
Sex		- 3.067	(- 4.936) – (- 1.198)	0.002
Age	OD	0.477	0.103 – 0.852	0.013
Sex		- 3.125	(- 4.998) – (- 1.252)	0.001

OS – ~~oculus~~-Oculus sinister, OD – ~~oculus~~-Oculus dexter. Values of P < 0.05 are considered significant.

**Table 5. Regression analysis of the influence of age and sex on the severity of pigmentation of the eyes**

Predictors	Regression coefficient (B)		95% CI	P - value
	Severity of pigmentation			
Age	OS	0.257	0.070 – 0.444	0.007
Sex		- 1.739	(- 2.697) – (- 0.781)	< 0.001
Age	OD	0.188	0.010 – 0.366	0.038
Sex		- 1.261	(- 2.159) – (- 0.362)	0.006

OS – ~~oculus~~-Oculus sinister, OD – ~~oculus~~-Oculus dexter. Values of P < 0.05 are considered significant.

**Table 6. ~~Linear~~-A linear regression model was built to predict the pigmentation score of the eyes ~~on-basis-of~~based on age and sex of the animals**

Linear regression equation	R <sup>2</sup>
Pigmentation score of left eye = 10.524 + (0.545 × Age) - (3.067 × Sex)	0.196
Pigmentation score of right eye = 10.847 + (0.477 × Age) - (3.125 × Sex)	0.180

Age of the animal (No. in years); Sex of the animal (1 = male; 2 = female)

#### 4. DISCUSSION

To the knowledge of the author, this is the first study in which corneal melanosis has been documented for a large number of Pugs in the country. This study suggests a high prevalence of PK in Pugs. PK is a common ocular disorder affecting the brachycephalic breed of dogs involving the progressive deposition of pigment in the corneal epithelium and associated conjunctival surface (Maggs, 2018). Corneal melanosis was described as a response to ~~the~~ chronic corneal and conjunctival irritation. The centripetal migration of the melanocytic cells from the limbal and perilimbal tissues into the corneal epithelium or more deeply into the corneal stroma is usually accompanied by other signs of active keratitis, such as corneal vascularization, stromal inflammatory cell infiltration, and granulation tissue formation. Melanocytic pigment was seen deposited in the basal epithelial cells of the corneal epithelium and ~~in~~ the anterior stromal tissue (Bedford & Longstaffe, 1979; Bellhorn & Henkind, 1966).

In the present study, age had a significant association with the detection of pigmentation in the eyes of Pugs which was similar to the findings mentioned in other studies (Labelle et al., 2013; Maini et al., 2019). The adult and senile dogs had moderate to severe degree of pigmentation compared to the younger dogs which had mild to moderate pigmentation corroborating a significant association between the age and the severity of the pigmentation recorded in this study which was contradictory to the findings reported in earlier studies (Labelle et al., 2013; Maini et al., 2019). The male animals, when compared with the females, had a severe degree of pigmentation. Though the sex of the animal had no significant association with the detection of PK, it had a significant association with the severity of pigmentation, which was analogous and contradictory ~~with to~~ the findings of other studies (Labelle et al., 2013; Maini et al., 2019). Coat colour and the side of the eye had no significance with either the detection or severity of pigmentation. The pattern of pigmentation varied according to the severity of pigmentation with the diffuse, patchy and medial pyramid pattern more commonly observed in the older animals with severe degree of pigmentation while the younger animals with mild degree of pigmentation exhibited paint brush and limbal brush border pigmentation corroborating these parameters (age and sex of the animals) to be reliable predictors of CP.

The therapeutic aspect of PK is mainly aimed at addressing any underlying disorders, including corneal inflammation and/or tear film disorders, typically using topical corticosteroids, Cyclosporine A, tacrolimus, and/or tear film replacements/stabilizers (Esson, 2015). Though the surgical management of PK varies with the inciting cause, most of them are only successful in ~~the~~ management of the condition for a short term, with the recurrence of pigmentation reported as early as 1 month post-operatively as the major complication. Soft cryotherapy has been reported to be successful for the management of PK with ~~lesser~~ ~~fewer~~ post-operative complications (Azoulay, 2014).

#### 5. CONCLUSION

The study ~~was mainly aimed at reporting the prevalence of PK in the Pugs and given the higher prevalence of this condition in this breed, it~~ warrants further study into the concurrent clinical findings that accompany this condition. Though few studies have reported on the concurrent clinical features associated with CP, all of them suggest a yet ~~to be to be~~ identified genetic background of this condition in Pugs. The CP score in Pugs and their severity varied depending ~~up~~ on the age and sex of the animal. Age and sex of the animal

can be used as predictors of the pigmentation score and hence the severity of pigmentation of the eyes in the Pugs.

## 9. REFERENCES

1. Rooney, N. J., & Sargan, D. R. (2009). Pedigree dog breeding in the UK: A major welfare concern. *RSPCA*, 1–76.
2. Whitley, R., McLaughlin, S., & Gilger, B. (1995). Update on eye disorders among purebred dogs. *Veterinary Medicine*, 90, 574–592.
3. Maggs, D. J. (2018). Diseases of the cornea and sclera. In D. J. Maggs, P. E. Miller & R. Ofri (Eds.), *Slatter's Fundamentals of Veterinary Ophthalmology* (6th edn, pp. 213–253). Elsevier Health Sciences.
4. Plummer, C. E. (2015). Addressing Brachycephalic Ocular Syndrome in the Dog. *Today's Veterinary Practice*, April.
5. Van Der Woerd, A. (2004). Adnexal surgery in dogs and cats. *Veterinary Ophthalmology*, 7(5), 284–290. <https://doi.org/10.1111/j.1463-5224.2004.04044.x>.
6. Appelboom, H. (2016). Pug appeal: brachycephalic ocular health. *Companion Animal*, 21(1), 29–36. <https://doi.org/10.12968/coan.2016.21.1.29>.
7. Stades, F. C., & Woerd, A. (2013). Diseases and Surgery of the Canine Eyelid. In K. N. Gelatt, B. C. Gilger, & T. J. Kern (Eds.), *Veterinary Ophthalmology* (5th edn, pp. 832–893). John Wiley & Sons, Inc.
8. Westermeyer, H. D., Ward, D. A., & Abrams, K. (2009). Breed predisposition to congenital alacrima in dogs. *Veterinary Ophthalmology*, 12(1), 1–5. <https://doi.org/10.1111/j.1463-5224.2009.00665.x>.
9. Kaswan, R. L., Salisbury, M.-A., & Ward, D. A. (1989). Spontaneous canine keratoconjunctivitis sicca: a useful model for human keratoconjunctivitis sicca: treatment with cyclosporine eye drops. *Archives of Ophthalmology*, 107(8), 1210–1216.
10. Maini, S., Everson, R., Dawson, C., Chang, Y. M., Hartley, C., & Sanchez, R. F. (2019). Pigmentary keratitis in pugs in the United Kingdom: prevalence and associated features. *BMC Veterinary Research*, 15(1), 384. <https://doi.org/10.1186/s12917-019-2127-y>.
11. Krecny, M., Tichy, A., Rushton, J., & Nell, B. (2015). A retrospective survey of ocular abnormalities in pugs: 130 cases. *Journal of Small Animal Practice*, 56(2), 96–102. <https://doi.org/10.1111/jsap.12291>.
12. Charbiwala, M. K. (2019). Ocular affections in animals with particular reference to corneal melanosis (Master's thesis, Chaudhary Sarwan Kumar Himachal Pradesh Krishi Vishwavidyalaya, Palampur, Himachal Pradesh, India).
13. Bedford, P. G. C., & Longstaffe, J. A. (1979). Corneal pannus (chronic superficial keratitis) in the German Shepherd Dog. *Journal of Small Animal Practice*, 20(1), 41–56. <https://doi.org/10.1111/j.1748-5827.1979.tb07019.x>.
14. Bellhorn, R. W., & Henkind, P. (1966). Superficial pigmentary keratitis in the dog. *Journal of the American Veterinary Medical Association*, 149(2), 173–175.
15. Labelle, A. L., Dresser, C. B., Hamor, R. E., Allender, M. C., & Disney, J. L. (2013). Characteristics of, prevalence of, and risk factors for corneal pigmentation (pigmentary keratopathy) in Pugs. *Journal of the American Veterinary Medical Association*, 243(5), 667–674. <https://doi.org/10.2460/javma.243.5.667>.
16. Esson, D. W. (2015). *Clinical atlas of canine and feline ophthalmic disease*. John Wiley & Sons.
17. Azoulay, T. (2014). Adjunctive cryotherapy for pigmentary keratitis in dogs: A study of 16 corneas. *Veterinary Ophthalmology*, 17(4), 241–249. <https://doi.org/10.1111/vop.12089>.

**Commented [es1]:** MUST BE UPDATED as 11.7% (2 out of 17) of the listed references were published in the past five years. The percentage has to be increased to at least 35-40%. Old references and lack of updates negatively influence the study and indicate that the study is no longer a point of interest.