

## **Case report**

### **A Nephrotic syndrome induced by Rifampicin: Case report**

#### **Abstract :**

The aim of this paper is to remind practitioners of this unusual complication of anti-tuberculosis treatment. It is a rare side effect, but it can be a source of chronic disease.

A 20-year-old female patient being treated for lymph node tuberculosis presented with a generalized edematous syndrome 1 week after starting anti-tuberculosis treatment. She had a history of mental illness and lymph node tuberculosis diagnosed 3 months prior to admission.

The diagnosis of a nephrotic syndrome with minimal glomerular lesions was made based on biological and anatomopathological arguments.

The responsibility of rifampicin was assessed using the French method of imputability for unexpected or toxic effects of drugs.

The patient was managed medically with a satisfactory outcome.

We report a rare but potentially serious side effect associated with rifampicin.

#### **Introduction**

Tuberculosis is an infectious disease that can now be cured with a well-administered **course of medication. Although the efficiency of currently available drugs is undeniable, their poor tolerability is often the price of their therapeutic success.**

Rifampicin, for example, has been reported to have several undesirable effects.

The most frequent form of rifampicin nephrotoxicity is acute renal failure with tubular necrosis on histology. Other forms of nephrotoxicity include interstitial nephritis with or without glomerular damage.

Here we report a case of minimal glomerular injury, following the introduction of rifampicin to treat lymph node tuberculosis.

#### **Case presentation**

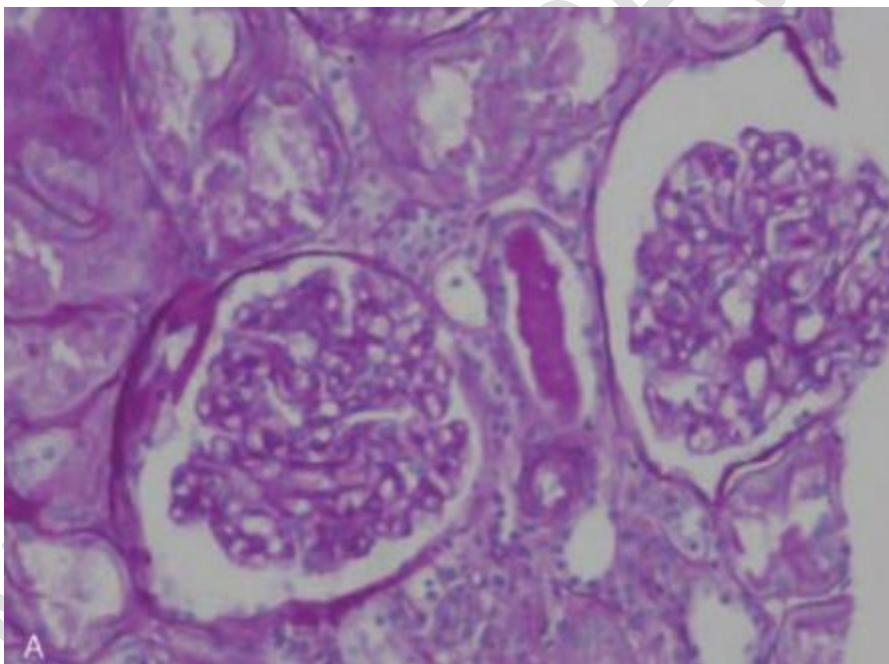
A 20-year-old female patient admitted to the nephrology department of the Ibn Rochd university hospital in Casablanca for edema. She had a history of mental illness since birth, and lymph node tuberculosis diagnosed 3 months prior to admission for which she had undergone surgery.

Questioning of the family revealed the onset of an edematous syndrome concomitant with the introduction of anti-tuberculosis treatment.

On admission, the patient was afebrile at 37.1°, her blood pressure was 125/85 mmHg, and she weighed 65 kg. She had gained 12 kg over the previous 3 months. The clinical examination was unremarkable, apart from oedema in both lower limbs. Biological findings included 24-hour proteinuria of 5g, hypoalbuminemia of 14. Renal function was normal (creatinine 5 mg/l and urea 0.3 to g/l), and normal liver function (ASAT 19 and ALAT 20).

Serologies for syphilis, HIV and hepatitis B and C were negative, antinuclear antibodies, anti-DNA antibodies, ANCA and complement C3 and C4 were normal. Ultrasound showed normal-sized, well-differentiated kidneys without dilated excretory cavities. The Chest X-ray was normal.

A renal biopsy was performed 2 weeks after discontinuation of treatment, concluding in a nephrotic syndrome with minimal glomerular lesions.



*Image [1] : Renal biopsy : Minimal glomerular lesions*

The patient had a good response to corticosteroids, with a complete regression of the edema and a proteinuria at 0.17 g per day.

The responsibility of rifampicin was assessed using the French method of accountability of unexpected or toxic effects of drugs [1].

Intrinsic accountability was level (C3S3) with a score of 16, and extrinsic accountability level B2.

## Discussion

Rifampicin is an antibiotic used to treat several bacterial infections including tuberculosis, leprosy and legionellosis in combination with other antibiotics.

Our patient had been on the ERIP protocol (Ethambutol - Rifampicin - Isoniazid and Pyrazinamide) since June 2022 to treat her lymph node tuberculosis. One week after the introduction of treatment, the patient developed a generalized edematous syndrome, with minimal glomerular lesions on renal biopsy. She was not on any previous treatment, so the diagnosis of antituberculosis -induced nephrotic syndrome was suspected.

Rifampicin occasionally causes renal damage ranging from mild proteinuria to acute renal failure. [2]

Park et al [3] speculated that rifampicin-induced MGL(write full form) nephrotic syndrome was due to the direct toxic effects of the drug, as there was no hemolytic anemia or thrombocytopenia and no immune deposits to suggest a humoral response.

In general, MGL nephrotic syndrome is treated with corticosteroids, with complete remission in 80-95% of adult cases. [4]

In some cases, the nephrotic syndrome improved after stopping rifampicin and taking oral corticosteroids. Only one case was reported where stopping rifampicin alone was sufficient to regress the nephrotic syndrome. On the other hand, our patient improved only after the introduction of corticosteroids at a dose of 1mg/kg/day.

In general, the prognosis is good in cases of rifampicin-induced nephrotic syndrome. No deaths were reported, and normalization of renal function and proteinuria were the rule after a few months of evolution. [5]

## Conclusion

Clinicians should be aware of the possibility that rifampicin may cause nephrotic syndrome especially during the first few months of treatment. Therefore, all patients on Rifampicin should be closely monitored. And if a nephrotic syndrome induced by anti-tuberculosis treatment is suspected, renal biopsy should be performed to establish the diagnosis and initiate any necessary corticosteroid therapy.

## COMPETING INTERESTS DISCLAIMER:

Authors have declared that they have no known competing financial interests OR non-financial interests OR personal relationships that could have appeared to influence the work reported in this paper.

## References :

- [1] Bégaud B, Evreux JC, Jouglard J, Lagier G. Imputability of unexpected or toxic effects of drugs: updating the method used in France. *Therapy*. 1985;40(2): 111-8. PubMed| Google Scholar.
- [2] De Vriese AS, Robbrecht DL, Vanholder RC, et al. Rifampicin-associated acute renal failure: pathophysiologic, immunologic, and clinical features. *Am J Kidney Dis* 1998;31:108–15
- [3] Park DH, Lee SA, Jeong HJ, et al. Rifampicin-induced minimal change disease is improved after cessation of rifampicin without steroid therapy. *Yonsei Med J* 2015;56:582–5.
- [4] Nakayama M, Katafuchi R, Yanase T, et al. Steroid responsiveness and frequency of relapse in adult-onset minimal change nephrotic syndrome. *Am J Kidney Dis* 2002;39:503–12.
- [5] Mori S, Matsushita Y, Arizono K. Minimal-change nephrotic syndrome associated with isoniazid in anti-tuberculosis chemoprophylaxis for a patient with rheumatoid arthritis. *Intern Med* 2011;50:253–7.