

Case report

Budd-Chiari Syndrome Revealing Behcet's Disease: A Case Report

ABSTRACT

The Budd-Chiari syndrome is a rare and serious complication of Behçet's disease, involving thrombosis of the hepatic veins and/or the intrahepatic or suprahepatic inferior vena cava. It primarily affects young men. We report the case of a 23-year-old patient admitted with Budd-Chiari syndrome accompanied by inferior vena cava thrombosis and deep vein thrombosis of the left lower limb. The patient was treated with curative anticoagulation and immunosuppressants, including methylprednisolone, cyclophosphamide, and azathioprine, resulting in significant clinical and biological improvement. Vascular Behçet's disease should be suspected in cases of recurrent venous and/or arterial thrombosis, as it is associated with high morbidity and mortality. Immunosuppressive treatment is essential for management.

Keywords: *Budd-Chiari syndrome, Behçet's disease, Thrombosis, Inferior vena cava, Immunosuppressive treatment, Anticoagulation*

1. INTRODUCTION

"Behçet's disease (BD) is a chronic inflammatory disease of unknown etiology, characterized by recurrent oral and genital aphthous ulcers, uveitis, skin lesions, and other multisystemic conditions associated with vasculitis. The frequency of vascular lesions, such as superficial and deep venous thrombosis, arterial aneurysms, and occlusions, varies from 7% to 29%. Budd-Chiari syndrome (BCS) is a rare and serious complication of Behçet's disease and involves thrombosis of the hepatic veins and/or the intrahepatic or suprahepatic inferior vena cava. Serious vascular complications of BCS associated with BD mainly affect young men" (1,2). We report the case of a 23-year-old patient with subacute Budd Chiari syndrome with IVC thrombosis revealing Behcet's disease.

2. CASE REPORT:

A 23-year-old male was hospitalized in the Gastroenterology Department at Ibn Rochd University Hospital for progressive abdominal distension without abdominal pain, transit disorders, jaundice, or other digestive or extra-digestive symptoms. Upon further questioning, the patient reported recurrent oral and genital ulcers and a history of inflammatory pericarditis treated with colchicine. Clinical examination revealed collateral thoracic venous circulation (Figure 1), hepatomegaly with a liver span of 15 cm, and chylous ascitic fluid (Figure 2) with an exudative profile (35 g/L). Abdominal CT angiography showed thrombosis of the supra-renal IVC, hepatic veins, and left renal vein extending to the right atrium, completely occluding the IVC lumen and most of the atrium (Figures 3,4). Transthoracic echocardiography confirmed a thrombus in the right atrium.

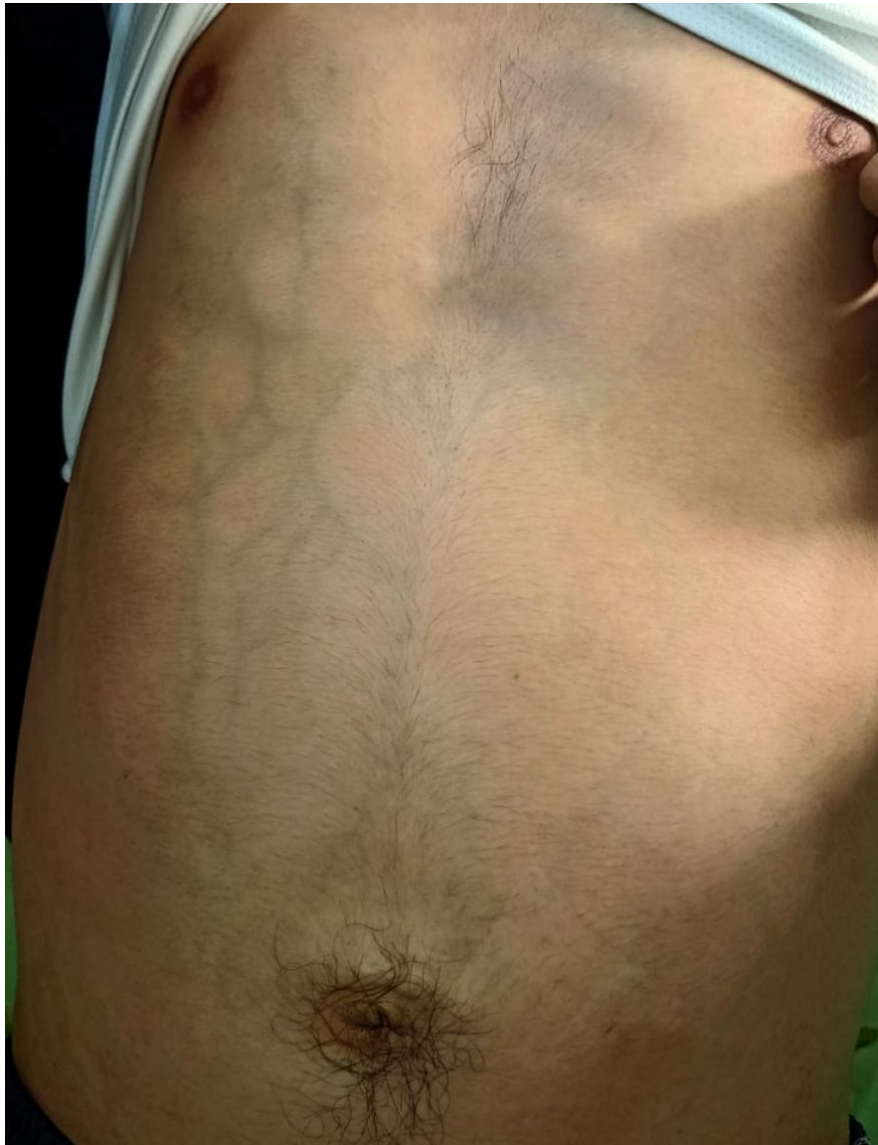

Figure 1 : Collateral Thoracic Venous Circulation



Figure 2 : Ascitic Fluid

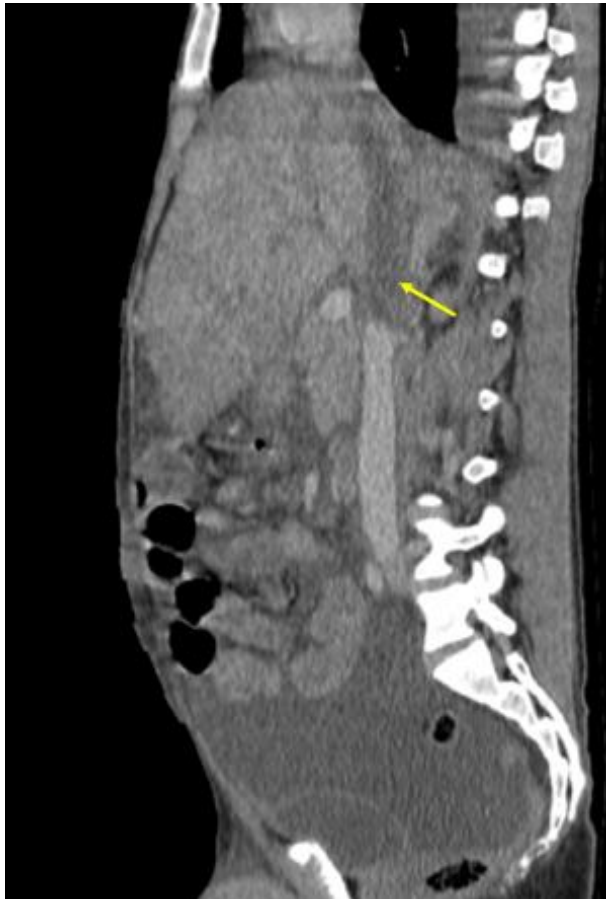

Figure 3: Thrombosis of the Inferior Vena Cava (IVC)

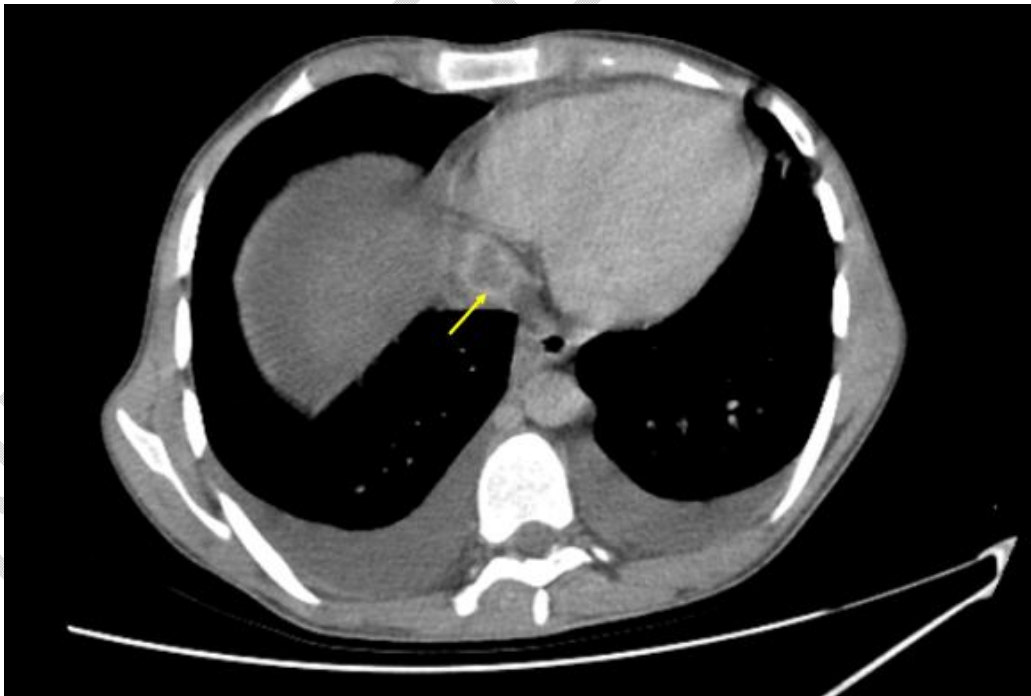


Figure 4: Thrombosis of the Inferior Vena Cava (IVC)

Behçet's Disease was diagnosed based on male sex, young age, recurrent oral and genital ulcers, bilateral shoulder arthralgia, a history of inflammatory pericarditis improved with colchicine, renal involvement (24-hour proteinuria: 4.45 g/day), and vascular involvement. Additional tests revealed cytolysis with ASAT: 256 (6.4x normal), ALAT: 268 (4.7x

normal), prothrombin time (PT): 61%, and Factor V: 63%. The thrombophilia workup showed reduced Protein C (40 U/mL), reduced Protein S (93 U/mL), normal Antithrombin III (71 U/mL), heterozygous MTHFR gene mutation, and no mutations in Factor II, JAK2, or Factor V Leiden genes.

Therapeutically, the patient received curative anticoagulation with LMWH switched to vitamin K antagonists, intravenous methylprednisolone (500 mg/day for three days), followed by long-term corticosteroid therapy (1 mg/kg/day, 60 mg/day) supplemented with vitamin D, calcium, and potassium. Despite repeated ascitic fluid drainage (twice a week), the patient developed deep vein thrombosis (DVT) in the left lower limb, evidenced by limb pain and a positive Homans' sign. Doppler ultrasound confirmed thrombosis of the external iliac vein extending to the proximal third of the superficial femoral vein. Biologically, there was a reduction in cytotoxicity (ASAT: 52, 1.3x normal; ALAT: 77, 1.4x normal) and normalization of coagulation tests (PT: 72%, Factor V: 73%). C-reactive protein (CRP) was negative at 5.3 mg/L. The patient was transferred to the Internal Medicine Department, where corticosteroids and anticoagulants were continued, along with biweekly cyclophosphamide boluses and azathioprine (100 mg/day). Clinical improvement included a reduced need for ascitic fluid drainage (once a week) and resolution of left lower limb pain. Biochemical improvement included normalized transaminases (ASAT: 56 U/L, 1.6x normal; ALAT: 64 U/L, 1.1x normal) and improved coagulation (PT: 88%, Factor V: 103%).

DISCUSSION:

"Behçet's disease (BD) is a relapsing-remitting vasculitis of unknown etiology characterized by a variety of clinical manifestations including uveitis, oral aphthae, skin lesions, and genital ulcers. The neurological, gastrointestinal, and vascular systems may also be affected, but less frequently" [3,4]. "BD-related BCS is a rare form of vascular involvement that significantly increases mortality and typically involves the IVC (suprahepatic and hepatic parts) and hepatic veins [5]. The prognosis is poor in patients with liver failure, but there is also a "silent" form with a relatively better outcome" [6]. "Although BD is a relatively rare cause (<5%) of BCS in Europe, it is more common (9–14%) as a cause of BCS in endemic countries such as Turkey [5,7]. Patients with BCS should be evaluated for BD, especially young adult male patients if they present with indicative symptoms including IVC thrombosis and recurrent oral or genital ulcers, as in our case" [5].

"Recently, a multicenter study including 61 patients with BCS related to BD showed a significantly higher mortality rate ($p = 0.04$) in the 25 (54.3%) patients with IVC thrombosis" [5]. "In another study of a large cohort of 9,000 patients with BD, 43 had BCS. The mortality rate of symptomatic patients with ascites was 60%, with a median survival of 10 months after diagnosis [8]. In comparison, asymptomatic patients without ascites who progressively developed BCS had a better prognosis with a mortality rate <10% at 7 years. Three treatment-refractory patients were treated with IFX, which was successful in reducing disease activity in only one of these patients, the other two having end-stage liver disease and eventually dying of liver failure" [8].

"The European League Against Rheumatism (EULAR) recommends a multidisciplinary approach to BD, with treatment depending on age, sex, type and severity of organ involvement" [6]. "Treatment of BD with vascular involvement mainly consists of immunosuppressive therapy with steroids and immunomodulators (cyclophosphamide, azathioprine and methotrexate). However, some BD patients may not respond well to these drugs. Anti-TNF monoclonal antibodies could be considered for treatment-refractory patients with major vessel involvement" [9].

Immunosuppressants, with or without glucocorticoids, are essential in the management of vascular involvement in BD. Several retrospective studies have shown that they reduce the relapse rate and prolong survival.

"The addition of anticoagulants to prevent recurrent thrombosis has been debated" (10,11). "Several retrospective studies have shown the ineffectiveness of anticoagulation alone or added to immunosuppressants to prevent recurrences" (12). "Anticoagulation could increase the risk of aneurysm rupture" (13,14,15). "Nevertheless, the tolerability of anticoagulant treatment was satisfactory in patients at low risk of bleeding after exclusion of pulmonary artery aneurysms and it could be used in refractory venous thrombosis" (13,16).

"In the last decade, several studies have demonstrated an improvement in survival with the use of angioplasty/stenting or TIPS in patients with BCS, highlighting the use of TIPS as definitive treatment before liver transplantation, and not only as a bridging treatment" (17,18). "However, experience in patients with BCS and MB is very limited (only a few case reports). A 45-year-old male case with MB presented with acute BCS and was treated with percutaneous transluminal angioplasty showing a dramatic reduction in portal venous pressure. Immunosuppressive agents and anticoagulants have been used for the prevention of recurrent thrombosis" (19). "A case series reported 5 patients with MB and acute BCS showing reversal of liver damage and correction of hemodynamic disturbances, prolonged survival, and good quality of life when lateral portacaval shunt was performed early in the course of BCS" (20). "There is no specific mention of the role of TIPS in the BCS subgroup associated with MB in the latest update of the EULAR (European League Against Rheumatism) guidelines" (13,18). "Furthermore, it is important to note the risk of vascular pathergy phenomena after manipulation of vessels in patients with BD, triggering vascular inflammation and thereby consequently an extension of thrombosis" (10,14,15). This is an important question to answer, given the high mortality of BCS in BD and the management of BCS of any etiology includes TIPS for the most severe cases.

We propose an algorithm for the management of BCS in BD (Figure 5). In case of BCS without known etiology, each patient should undergo a rapid review of the clinical criteria for BD, especially if they are young (< 35 years). Once the diagnosis of BD is established, we must consider that we are facing a case of vascular involvement of BD.

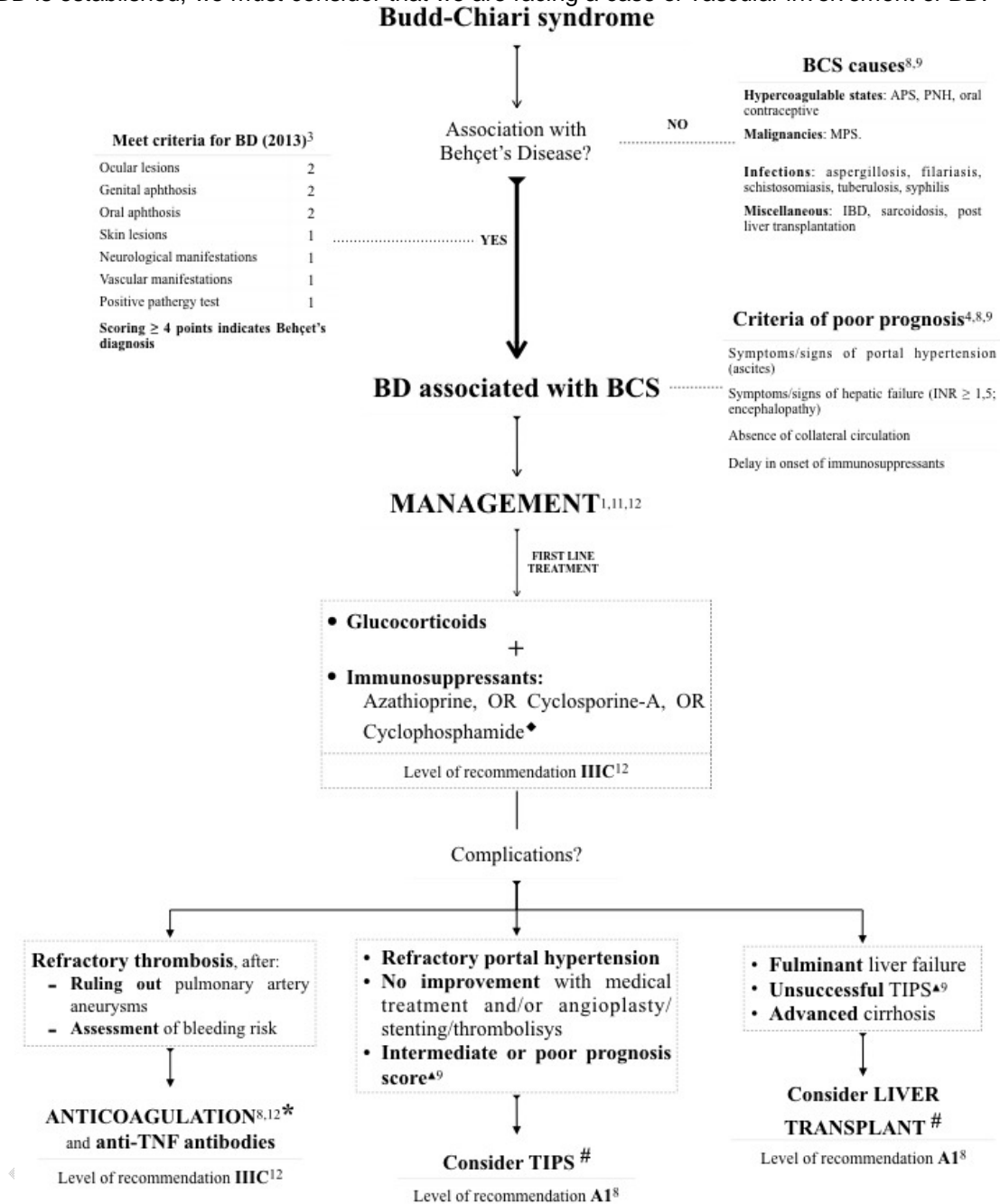


Figure 5: algorithm for the management of BCS in BD

Diagnosis of MB is usually delayed by several years, in our case the presentation was acute symptomatic BCS, The diagnostic process was rapid and allowed for prompt therapeutic intervention. Different therapeutic options were proposed including anticoagulants and immunosuppressants. We opted for intravenous heparin and high dose intravenous corticosteroids and intravenous cyclophosphamide with good clinical and laboratory improvement.

4. CONCLUSION

In conclusion, acute BCS presenting in MB is a serious condition with high mortality. Early diagnosis and appropriate treatment of MB can lead to favorable outcomes. Vascular involvement in MB is managed by immunosuppression, Other therapeutic options such as anticoagulation or interventional vascular therapy have a secondary role and should be considered on a case-by-case basis.

COMPETING INTERESTS

Authors have declared that no competing interests exist.

CONSENT

As per international standards or university standards patient(s) written consent has been collected and preserved by the author(s)

Disclaimer (Artificial intelligence)

Author(s) hereby declare that NO generative AI technologies such as Large Language Models (ChatGPT, COPILOT, etc.) and text-to-image generators have been used during the writing or editing of this manuscript.

REFERENCES

1. La Regina M, Gasparyan AY, Orlandini F, Prisco D. Behçet's disease as a model of venous thrombosis. *Open Cardiovasc Med J.* 2010;4:71–77. [[PMC free article](#)] [[PubMed](#)] [[Google Scholar](#)]
2. Ben Ghorbel I, Ennaifer R, Lamloom M, Khanfir M, Miled M, Houman MH. Budd-Chiari syndrome associated with Behçet's disease. *Gastroenterol Clin Biol.* 2008;32:316–320
3. Bolek E EE, Yardımcı G, Kilic L, Akdoğan A, Karadag O. Amyloidosis in Behçet's disease: experience of a vasculitis centre at Silk road. *Arthritis Rheumatol* 2019;72(suppl 10) 2. Yazici H, Seyahi E, Hatemi G, Yazici Y. Behçet syndrome:
4. Karadag O, Kalyoncu U. Behçet's disease; A rare refractory patient with vena cava superior syndrome treated with infliximab: a case report and review of the literature. *Acta Clin Belgica* 2019;74(5):364-369. doi:10.1080/17843286.2018.1522020
4. Akyol L, Toz B, Bayındır Ö, et al. Budd–Chiari syndrome in Behçet's disease: a retrospective multicenter study. *Clin Rheumatol.* 2022;41(1):177-186. doi:10.1007/s10067-021-05878-21
6. contemporary view. *Nat Rev Rheumatol* 2018;14(2):107-119. doi:10.1038/nrrheum.2017.208
3. Uyaroglu OA, Erden A, Kilic L, Peynircioğlu B,
7. Sakr MA, Reda MA, Ebada HE, et al. Characteristics and outcome of primary Budd-Chiari syndrome due to Behçet's syndrome. *Clin Res Hepatol Gastroenterol* 2020;44(4):503-512. doi:https://doi.org/10.1016/j.clinre.2019.10.006
8. Seyahi E, Caglar E, Ugurlu S, et al. An outcome survey of 43 patients with Budd-Chiari syndrome due to Behçet's syndrome followed up at a single, dedicated center. *Semin Arthritis Rheum* 2015;44(5):602-609. doi:10.1016/j.semarthrit.2014.10.014
9. Hatemi G, Christensen R, Bang D, et al. 2018 update of the EULAR recommendations for the management of Behçet's syndrome. *Ann Rheum Dis* 2018;77(6):808-818. doi:10.1136/annrheumdis-2018-213225
10. Seyahi E. Behçet's disease: How to diagnose and treat vascular involvement. *Best Pract Res Clin Rheumatol.* 2016; 30:279-295. [[PubMed](#)] [[Google Scholar](#)]
11. Desbois AC, Rautou PE, Biard L, Belmatoug N, Wechsler B, Resche-Rigon M, Zarrouk V, Fantin B, de Chambrun MP, Cacoub P, Valla D, Saadoun D, Plessier A. Behçet's disease in Budd-Chiari syndrome. *Orphanet J Rare Dis.* 2014 Sep13; 9:104. [[PMC free article](#)] [[PubMed](#)] [[Google Scholar](#)]
12. Saleh Z, Arayssi T. Uptodate on the therapy of Behçet Disease. *Ther Adv Chronic Dis.* 2014; 5:112-134. [[PMC free article](#)] [[PubMed](#)] [[Google Scholar](#)]
13. Hatemi G, Christensen R, Bang D, et al. 2018 update of the EULAR recommendations for the management of Behçet's syndrome. *Ann Rheum Dis.* 2018; 77:808-818. [[PubMed](#)] [[Google Scholar](#)]
14. Wang H, Guo X, Tian Z, Liu Y, Wang Q, Li M, Zeng X, Fang Q. Intracardiac thrombus in patients with Behçet's disease: Clinical correlates, imaging features, and outcome: A retrospective, single-center experience. *Clin Rheumatol.* 2016; 35:2501-2507. [[PubMed](#)] [[Google Scholar](#)]
15. Galeano-Valle F, Demelo-Rodríguez P, Álvarez-Sala- Walther L, Pinilla-Llorente B, Echenagusia-Boyra MJ, Rodriguez-Abella H, Del-Toro-Cervera J. Intracardiac thrombosis in Behçet's Disease successfully treated with immunosuppressive agents: A case of vascular pathergy phenomenon. *Intractable Rare Dis Res.* 2018; 7:54-57. [[PMC free article](#)] [[PubMed](#)] [[Google Scholar](#)]
16. Emmi G, Bettiol A, Silvestri E, Di Scala G, Becatti M, Fiorillo C, Prisco D. Vascular Behçet's syndrome: An update. *Intern Emerg Med.* 2018; 2018; Nov 29. [[PubMed](#)] [[Google Scholar](#)]
11. Garcia-Pagán JC, Heydtmann M, Raffa S, et al. TIPS for Budd-Chiari syndrome: Long-term results and prognostics factors in 124 patients. *Gastroenterology.* 2008; 135:808-815. [[PubMed](#)] [[Google Scholar](#)]

12. European Association for the Study of the Liver. EASL Clinical Practice Guidelines: Vascular diseases of the liver. *J Hepatol*. 2016; 64:179-202. [[PubMed](#)] [[Google Scholar](#)]
19. Han SW, Kim GW, Lee J, Kim YJ, Kang YM. Successful treatment with stent angioplasty for Budd-Chiari syndrome in Behçet's disease. *Rheumatol Int*. 2005; 25:234-237. [[PubMed](#)] [[Google Scholar](#)]
20. Orloff LA, Orloff MJ. Budd-Chiari syndrome caused by Behçet's disease: Treatment by side-to-side portacaval shunt. *J Am Coll Surg*. 1999; 188:396-407. [[PubMed](#)] [[Google Scholar](#)]

UNDER PEER REVIEW