

Case report

Christ-Siemens-Touraine syndrome: case report

ABSTRACT

The teeth, skin, hair, nails and eccrine and sebaceous glands which are tissues ectodermally or mesodermally derived can be affected by rare disorders called ectodermal dysplasias.

The most common type of ectodermal dysplasias is known as Christ-Siemens-Touraine syndrome or anhidrotic ectodermal dysplasia.

A twelve-year old child from consanguineous parents is suffering from poor perspiration and hyperthermia while playing soccer. On physical examination, he shows frontal bossing, periorbital wrinkling, thick lips with prominent chin, scarce or no hair and only three conical teeth. The diagnosis of Christ-Siemens-Touraine syndrome was suggested and was confirmed by the identification of the Ectodysplasin A (EDA) allele.

This entity is important to know because even though there is no curative treatment so far, the patient can make some adjustments that involve moisturizing and avoiding hot environments.

In the view of the rarity of the cases described in the literature, this case is reported

Keywords: Christ-Siemens-Touraine syndrome, anhidrotic ectodermal dysplasia, absence of sweat glands, Ectodysplasin A gene

1. INTRODUCTION

Ectodermal dysplasias are rare disorders characterized by the presence of abnormalities in one or more ectodermally or mesodermally derived tissues.(Mokhtari et al., 2012)

The hypohidrotic/anhidrotic ectodermal dysplasia (AED) represented by Christ-Siemens-Touraine syndrome is the most common form, characterized by the triad of hypohidrosis, hypotrichosis and hypodontia [5-8]. Other features include frontal bossing, thick lips, saddle nose and scarce hair.

It is rare in incidence affecting mostly boys in 1 in 100 000 births(Bouhmidi et al., 2024)

Here we report a case of Christ-Siemens-Touraine syndrome supported by the identification of the EDA gene in a male patient on the view of the rarity of this condition

2. CASE REPORT

A 12-year-old child was referred from the pediatric department to our consultation for dental anomalies, sweating defect and hyperpigmented spots on the face.

The child's main complaint was poor perspiration and hyperthermia while playing soccer.

On physical examination, the patient showed frontal bossing, periorbital wrinkling, no saddle nose nor sunken cheeks, but thick lips with prominent chin. (figure 1)

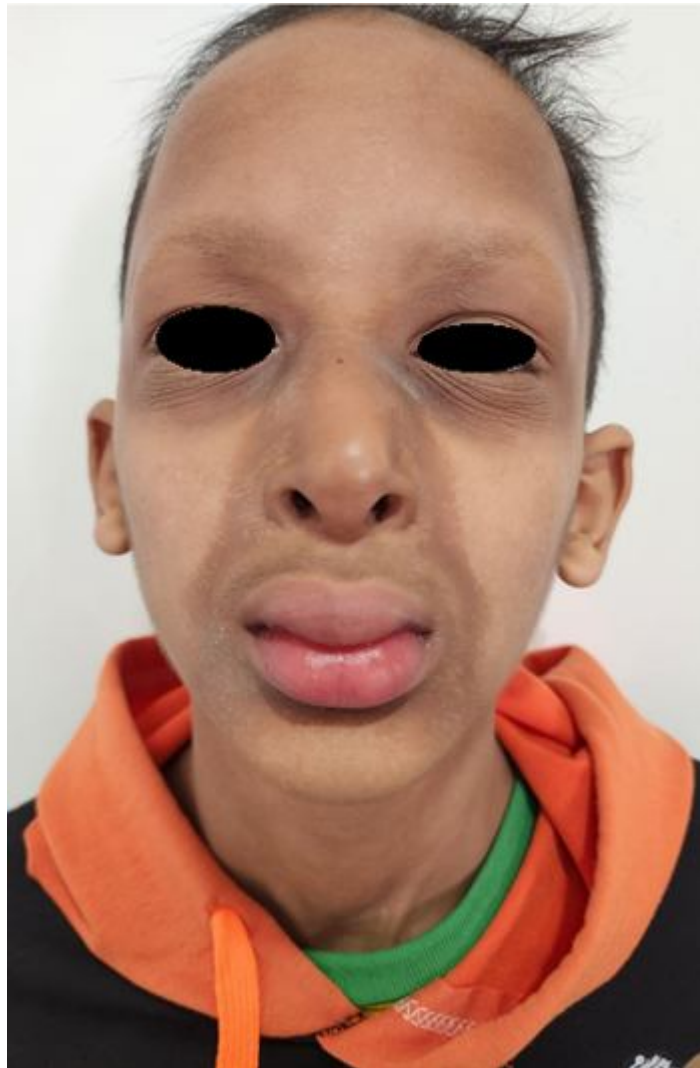

Figure 1: Retraction of the anterior hairline, frontal bossing, periorbital wrinkling, perioral and perinasal hyperpigmentation with milia-like structures and thick lips

Examination of the oral cavity revealed only two conical upper incisors and one conical canine with mild gum atrophy, the remaining dentition was missing (figure 2)

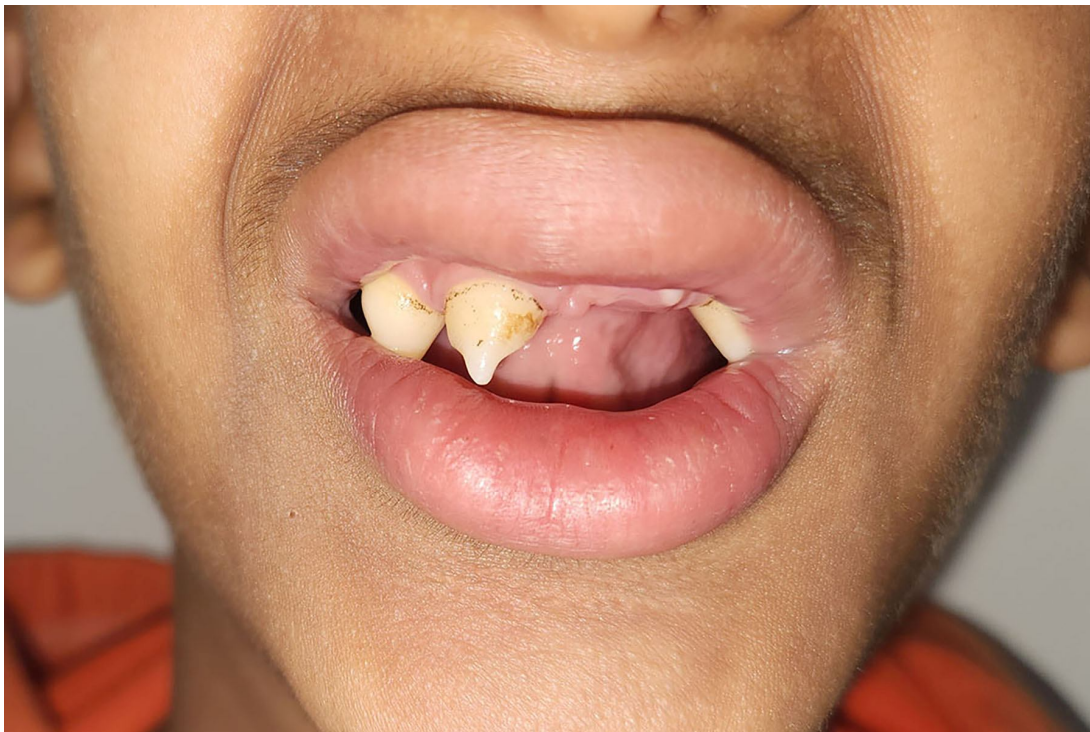

Figure 2: Two conical incisors and one conical canine

There was retraction of the anterior hairline, with short, scattered and thin hair on the scalp (figure 3) and eyebrows.

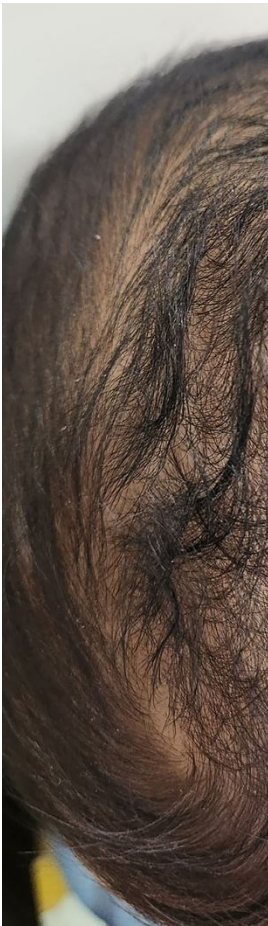

Figure 3: Clinical image showing sparse and thin hair on the scalp

On trichoscopy, the hairs were widely spaced and there was a single hair per orifice, there were also some hair casts and perifollicular scale, but there was no hair thickness heterogeneity, no yellow dots, no perifollicular discoloration, no honeycomb pigmentation and no elongated linear blood vessels. (figure 4)



Figure 4: Trichoscopy showing widely spaced hairs, a single hair per orifice, hair casts and perifollicular scale. Polarized contact dermoscopy (DermLite DL4, original magnification, 10x)

There was no hair in the axilla, pubic area, face, trunk nor limbs.

The nails, palms and soles were normal with no dermatoglyphic alterations.

In addition, there was periorbital, perinasal and perioral symmetrical hyperpigmentation. Dermoscopy of the perinasal area revealed shiny rounded structures that were not expressive under skin pressure.

The skin was overall dry in comparison to salivation and lacrymation that were preserved

There was no otorhinolaryngological nor ophthalmic involvement.

The child is a progeny of consanguineous parents, and his three years old niece also had a hyposudation disorder

This clinical presentation is highly suggestive of Ectodermal dysplasia. The axillary biopsy revealed a total absence of sweat glands, highly suggesting the diagnosis of Christ-Siemens-Touraine syndrome, (figure 5), which was further confirmed by the identification of the Ectodysplasin A (EDA) gene.

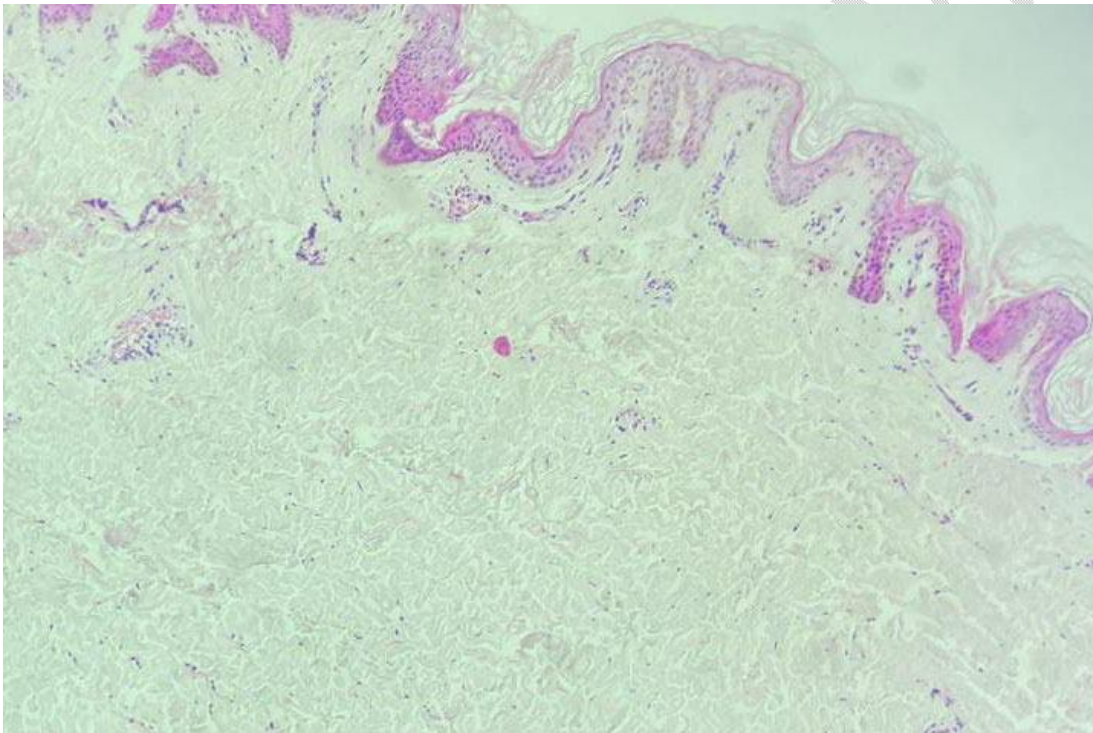


Figure 5: Absence of sweat glands on the axillary region (4x magnification, Hematoxylin and Eosin stain)

The patient was advised to play as a goalkeeper on the late afternoon and frequently moisturize his skin to avoid overheating which he agreed to.

3. DISCUSSION

Christ-Siemens-Touraine syndrome, more commonly known as anidrotic or hypohidrotic ectodermal dysplasia, is a predominantly X-linked recessive genetic disorder, but can also be autosomal dominant or autosomal recessive. This syndrome is caused by a mutation in the ectodysplasin A gene which disrupts signalling pathways in hair follicles, eccrine sweat glands and dental morphogenesis. (Vora et al., 2014)

Autosomal dominant and autosomal recessive forms are linked to other mutations

This syndrome is characterized by the triad of hypotrichosis, hypohidrosis and hypodontia. Hypotrichosis is characterized by fine, light-colored, slow-growing hair(Kumar et al., 2019). Hypohidrosis is characterized by severely deficient perspiration, leading to episodes of hyperthermia, while hypodontia is characterized by abnormal, sparse, cone-shaped teeth.

There may also be changes in nasal secretions, from concretions during infancy to large mucus clots afterwards, depression of the nasal bridge with saddle nose, reduced sebaceous secretion, xerophthalmia due to abnormalities of the meibomus glands, skin xerosis, loss of dermatoglyphs, persistent periorbital hyperpigmentation, recurrent pneumonia, hoarse voice, hypoplasia of the midface.

However, the child's psychological and psychomotor development remains normal.

Diagnosis is based on clinical features and can be confirmed by identification of certain alleles, such as EDA and WNT10A.(Wright et al., 1993)

On the other side, secondary anhidrosis may occur during sympathetic nerve disturbance or be associated with skin disorders like seborrheic dermatitis, atopic dermatitis, psoriasis and lichen planus, with some endocrine and metabolic disorders such as diabetes and Addison's disease; it can also be drug induced by some drug like atropine and scopolamine.(Ohshima & Tamada, 2016)

Treatment of AED relies on access to water and a cool environment during the hot season, wearing wet clothes, humidification of ambient air to avoid nasal concretions, moisturizing eye drops, applying emollients and eventually wigs

The dental treatment requires prostheses and the prevention of cavities.

The orthopedic and dentofacial orthodontic treatments are focused recently on correcting dental malpositioning and jaw asymmetries and not on stimulating their growth from an early age, which may be a point of improvement(Cerezo-Cayuelas et al., 2022)

A comprehensive understanding of the clinical signs of ectodermal dysplasia will enable accurate diagnosis and the development of an effective treatment plan which will ultimately enhance patients overall quality of life(Abdulla et al., 2019)

Future treatments could involve gene therapy or administration of a recombinant EDA protein.(Wright et al., 1993)

4. CONCLUSION

This case report highlights the clinical characteristics of this rare genetic disorder which combines abnormalities of the skin, teeth, hair and eccrine glands which are tissues ectodermally and mesodermally derived. While the diagnosis may be helped by histopathology showing the absence of the sweat glands, it is confirmed genetically by the identification of the EDA or WNT10A genes

CONSENT

All authors declare that 'written informed consent was obtained from the patient (or other approved parties) for publication of this case report and accompanying images. A copy of the written consent is available for review by the Editorial office/Chief Editor/Editorial Board members of this journal

ETHICAL APPROVAL

As per international standards or university standards written ethical approval has been collected and preserved by the authors

Disclaimer (Artificial intelligence)

Author(s) hereby declare that NO generative AI technologies such as Large Language Models (ChatGPT, COPILOT, etc.) and text-to-image generators have been used during the writing or editing of this manuscript.

REFERENCES

Abdulla, A. M., Almaliki, A. Y., Shakeela, N. V., Alkahtani, Z., Alqahtani, M. A., Sainudeen, S.,

&Shamsuddin, S. V. (2019). Prosthodontic Management of a Pediatric Patient with Christ-Siemens-

Touraine Syndrome : A Case Report. *International Journal of Clinical Pediatric Dentistry*, 12(6), 569–572. <https://doi.org/10.5005/jp-journals-10005-1697>

Bouhmidi, M., Boudarbala, H., Elouali, A., Babakhouya, A., Maria, R., & Benajiba, N. (2024). Christ-Siemens-Touraine Syndrome : A Report of a Rare Pediatric Case. *Cureus*, 16(5), e60022. <https://doi.org/10.7759/cureus.60022>

Cerezo-Cayuelas, M., Pérez-Silva, A., Serna-Muñoz, C., Vicente, A., Martínez-Beneyto, Y., Cabello-Malagón, I., & Ortiz-Ruiz, A. J. (2022). Orthodontic and dentofacial orthopedic treatments in patients with ectodermal dysplasia : A systematic review. *Orphanet Journal of Rare Diseases*, 17(1), 376. <https://doi.org/10.1186/s13023-022-02533-0>

Kumar, A., Thomas, P., Muthu, T., & Mathayoth, M. (2019). Christ–Siemens–Touraine Syndrome : A Rare Case Report. *Journal of Pharmacy & Bioallied Sciences*, 11(1), Article 1. https://doi.org/10.4103/jpbs.JPBS_36_18

Mokhtari, S., Mokhtari, S., & Lotfi, A. (2012). Christ-Siemens-Touraine Syndrome : A Case Report and Review of the Literature. *Case Reports in Dentistry*, 2012, 586418. <https://doi.org/10.1155/2012/586418>

Ohshima, Y., & Tamada, Y. (2016). Classification of Systemic and Localized Sweating Disorders. In H. Yokozeki, H. Murota, & I. Katayama (Éds.), *Current Problems in Dermatology* (Vol. 51, p. 7–10). S. Karger AG. <https://doi.org/10.1159/000446753>

Vora, R. V., Anjaneyan, G., Chaudhari, A., & Pilani, A. P. (2014). Christ-siemens-tourainesyndrome : Case report of 2 brothers. *Journal of Clinical and Diagnostic Research: JCDR*, 8(10), Article 10. <https://doi.org/10.7860/JCDR/2014/9544.5031>

Wright, J. T., Grange, D. K., & Fete, M. (1993). Hypohidrotic Ectodermal Dysplasia. In M. P. Adam, J. Feldman, G. M. Mirzaa, R. A. Pagon, S. E. Wallace, L. J. Bean, K. W. Gripp, & A. Amemiya (Éds.), *GeneReviews®*. University of Washington, Seattle. <http://www.ncbi.nlm.nih.gov/books/NBK1112/>