

Original Research Article

Occurrence of *Mannheimia haemolytica* in clinical caprine mastitis in Theni district of Tamil Nadu

ABSTRACT

Aim

To identify and assess the etiological agent responsible for caprine mastitis in a doe, analyse the antibiotic sensitivity ~~and provide suitable treatment, for the same, and provide suitable treatment.~~

Study Design

Clinical examination and microbiological analysis, followed by antibiotic sensitivity testing.

Place and Duration of Study

Veterinary College and Research Institute, Theni. Case presented in the month of November, 2023.

Methodology

A 31 kg doe with a history of udder swelling and watery milk from the right quarter was examined. Clinical examination revealed a swollen, ~~painful and~~ painful and indurated udder. The California Mastitis Test confirmed the mastitis, ~~and the~~ and the milk sample was collected aseptically for microbiological analysis. After initial inoculation in nutrient broth and after overnight incubation, the culture was streaked onto MacConkey agar. Bacterial identification ~~was done~~ was done by routine biochemical ~~tests~~ tests. Antibiotic sensitivity testing (ABST) was conducted using the Kirby-Bauer disc diffusion method.

Results

Gram staining revealed Gram-negative ~~coccobacilli~~ negative coccobacilli with bipolar staining resembling *Mannheimia hemolytica*. The tiny red pinpoint colonies on MacConkey agar and positive catalase, oxidase, and indole tests were suggestive of *Mannheimia hemolytica*. ABST showed resistance to Penicillin, Ampicillin, Methicillin, and Metronidazole, while sensitivity was observed to Amoxicillin Clavulanic acid, Ciprofloxacin, Gentamicin, Cefixime, Ceftriaxone, Enrofloxacin, Chloramphenicol, Streptomycin, Tetracycline, Oxytetracycline, Trimethoprim, and Sulfonamide. Treatment with Ceftriaxone (10 mg/kg) intra-venously and Meloxicam (0.5 mg/kg) intramuscularly, along with topical Mastilep for three days, alleviated udder pain and hardness.

Conclusion

Mastitis in goats is commonly caused by *Staphylococcus* spp.; however, *Mannheimia hemolytica* is a rare but possible etiological agent. This case represents the first report of *Mannheimia hemolytica*-induced mastitis in Tamil Nadu, indicating a need for further molecular study of this pathogen in caprine mastitis.

Keywords: Caprine mastitis; clinical mastitis; *Mannheimia hemolytica*; Antibiotic sensitivity; Gram's stain

1. INTRODUCTION

Caprine mastitis is a prevalent and significant disease among dairy goat populations, significantly impacting milk production, animal welfare, and the economic viability of goat farming (Rasheed and Jwher, 2021). This condition is characterized by ~~inflammation of the mammary gland~~ mammary gland inflammation, often manifesting through symptoms such as a swollen, hard, and painful udder, which may lead to altered milk quality or reduced yield (Bergonier *et al.*, 2003). In addition to the health risks faced by affected goats, mastitis also poses direct financial burdens for smallholder farmers and commercial dairies due to the costs associated with veterinary care, reduced productivity, and the potential culling of chronically infected animals.

The etiological agents responsible for caprine mastitis are diverse, with bacterial infections being the primary cause (Bergonier *et al.*, 2003). *Staphylococcus aureus* and coagulase-negative *Staphylococci*, *Streptococcus agalactiae*, and *Escherichia coli* are the most common pathogens isolated in caprine mastitis cases. Other less commonly isolated bacterial pathogens include *Pseudomonas aeruginosa*, *Mycoplasma species*, *Trueperella pyogenes*, *Klebsiella species* and *Mannheimia hemolytica* (Dore *et al.*, 2016).

M. hemolytica, a Gram-negative coccobacillus more commonly associated with respiratory infections in cattle, sheep, and goats, has also been reported as a cause of mastitis in caprine herds (Omaleki *et al.*, 2011). Recent studies have documented its presence in caprine mastitis cases, suggesting it can act as an opportunistic pathogen in the mammary gland under certain conditions (Mishra *et al.*, 2018). The mechanisms behind the ability of *M. hemolytica* to establish infection in the mammary tissue remain unclear, but it is hypothesized that the production of leukotoxins and other virulence factors by ~~this bacterium~~ this bacterium may contribute to its pathogenicity in the mammary glands (Omaleki *et al.*, 2011).

The emerging role of *M. hemolytica* in mastitis highlights the need for further investigation into its prevalence, pathogenic mechanisms, and antibiotic susceptibility in caprine infections (Omaleki *et al.*, 2011). Given the limited research on the role of *M. hemolytica* in mastitis, particularly in goats, there is a pressing need to document such clinical cases. Therefore, this study aims to report a case of *M. hemolytica*-induced mastitis in a doe from a backyard goat population in Tamil Nadu.

2. MATERIAL AND METHODS

2.1. Case presentation

A doe, weighing 31 kg, was presented to the Veterinary Clinical Complex, Veterinary College and Research Institute, Theni, with clinical signs indicative of mastitis in the month of November, 2023. The owner reported a one-day history of swelling in the right quarter of the udder, accompanied by a watery milk discharge. Upon physical examination, the affected quarter was observed to be markedly swollen and hardened, eliciting pain upon palpation.

2.2. Initial diagnostic screening

To confirm the presence of mastitis, an initial screening was performed using the California Mastitis Test (CMT) as described by Gebrewahid *et al.*, 2012. In brief, the CMT was performed by mixing 3-4 ml of goat milk with an equal volume of CMT reagent. The mixture was gently swirled, and the reaction was observed. Following this, milk sample was collected from the affected quarter aseptically for further microbiological examination to identify the causative agent.

2.3. Sample collection and culture preparation

The milk sample was inoculated into 5 ml of sterile nutrient broth and was incubated overnight aerobically at 37°C. After this initial incubation period, the broth culture was streaked by quadrant streaking method onto MacConkey agar as described by Mishra *et al.* (2018) and pure culture was obtained. The pure culture was subjected to further microbiological identification.

2.4. Microscopic examination and biochemical testing

The isolated bacterial culture was subjected to Gram staining as described in previous study (Cowan, 1974). To confirm the bacterial identity, the culture was subjected to a series of biochemical tests including catalase test, oxidase test and indole test as described by Quinn *et al.*, 2011.

Comment [KA1]: Get more current reference

2.5. Antibiotic sensitivity testing

The pure culture was subjected to antibiotic sensitivity testing (ABST) using the Kirby-Bauer disc diffusion method on Muller Hinton Agar as per the procedure recommended by National Committee of Clinical Laboratory Standards, 2013. In brief, pure culture broth was spread over Muller-Hinton agar plate. Then, commercially available antibiotic discs containing different antibiotics including Penicillin, Ampicillin, Methicillin, Metronidazole, Amoxicillin-Clavulanic Acid, Ciprofloxacin, Gentamicin, Cefixime, Ceftriaxone, Enrofloxacin, Chloramphenicol, Streptomycin, Tetracycline, Oxytetracycline, Trimethoprim, and Sulfonamide were placed on the inoculated agar plate and was incubated at 35-37°C. The Zone of inhibition (in mm) for each antibiotic was recorded after 16-18 hours of incubation and compared with manufacturer-provided standards to determine antibiotic susceptibility.

3. RESULTS AND DISCUSSION

The incidence of caprine mastitis in goat herds are generally less than 5% in a year, however, higher incidences have also been reported in some herds, which has led to mortality of more than 40%, thereby affecting profitability and productivity (Bergonier *et al.*, 2003). The less common causative of caprine mastitis, *Mannheimia* genus, comprises of five species namely *M. haemolytica*, *M. glucosida*, *M. ruminalis*, *M. varigena* and *M. granulomatis*. Of these, only *M. haemolytica* and *M. glucosida* have been reported as pathogens of importance in clinical mastitis in sheep (Omaleki *et al.*, 2010). However, its occurrence in caprine mastitis is regarded as exceedingly rare, although it is a predominant pathogen in respiratory manheimiosis in goats. Thus far, *M. haemolytica* induced caprine mastitis has been reported only once in India (Mishra *et al.*, 2018).

In this study, Gram's stain revealed gram-negative small coccobacillary organism with bipolar staining (safety pin appearance) organisms, suggestive of *M. hemolytica* (Quinn *et al.*, 2011). This initial finding was further confirmed by the tiny red pin-point colonies in MacConkey agar and biochemical tests that demonstrated catalase, oxidase and indole positive, which are characteristic of *M. hemolytica* (Quinn *et al.*, 2011).

ABST revealed that the isolated organism was resistant to Penicillin, Ampicillin, Methicillin and Metronidazole; and was sensitive to Amoxicillin Clavulanic acid, Ciprofloxacin, Gentamicin, Cefixime, Ceftriaxone, Enrofloxacin, Chloramphenicol, Streptomycin, Tetracycline, Oxytetracycline, Trimethoprim and Sulfonamide. Based on the ABST results, treatment included intravenous administration of Ceftriaxone (10 mg / kg body weight), intra-muscular administration of Meloxicam (0.5 mg / kg body weight), and topical application of Mastilep over the infected teat for 3 days.

M. hemolytica is an opportunistic pathogen, therefore infection is mostly endogenous. Under stressful conditions, it causes respiratory manheimiosis. However, in this study, *M. hemolytica* was isolated from goat mastitis. It is speculated that Theni district of Tamil

Nadu witnessed average temperature of 24.7°C, with minimum temperature at 21°C and maximum temperature at 28.4°C in the month of November, 2023. In addition, on an average, 13 days witnessed rain with relative humidity of 72%. The varying climatic conditions could have attributed to stress in goats, which could have led to respiratory mannheimiosis (Kumar *et al.*, 2015). The nasal secretions of infected goats would expel *M. hemolytica*. This can survive in low temperature and high humidity environment, which upon direct contact with udder, could have led to mastitis (Ruffin *et al.*, 2021). Further, *M. hemolytica* causes anemia in goats, which was evident by pale mucous membrane.

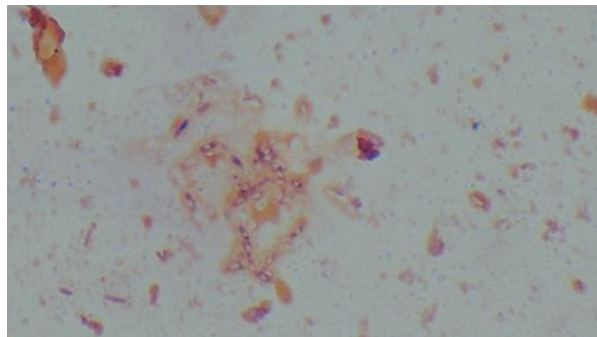


Fig. 1. Gram's stain showing gram-negative pleomorphic organism -"safety-pin" appearance

4. CONCLUSION

M. hemolytica is an opportunistic pathogen, which upon stressful conditions causes disease. In Theni district of Tamil Nadu, the climatic conditions between October and February are highly variable, alternating between rainy days and periods of high environmental temperatures. The fluctuation in climatic conditions causes stress in animals, because of which respiratory mannheimiosis occurs (Kumar *et al.*, 2015). This can serve as a probable source of infection for *M. hemolytica* induced mastitis in goats. Hence, awareness should be provided to farmers on better herd management practices to avoid environmental mastitis, thereby to sustain their economic stability. Future studies may be aimed at analysing the prevalence of *M. hemolytica* in various agro-climatic zones.

REFERENCES

1. Rasheed, T. J., & Jwher, D. M. (2021). Isolation, identification and sensitivity of *Mannheimia haemolytica* from ewes' udder with clinical mastitis. *Journal of Applied Veterinary Sciences*, 6(3), 25-30.
2. Bergonier, D., De Crémoux, R., Rupp, R., Lagriffoul, G., & Berthelot, X. (2003). Mastitis of dairy small ruminants. *Veterinary Research*, 34(5), 689-716.
3. Dore, S., Liciardi, M., Amatiste, S., Bergagna, S., Bolzoni, G., Caligiuri, V., Cerrone, A., Farina, G., Montagna, C. O., Saletti, M. A., & Scatassa, M. L. (2016). Survey on small ruminant bacterial mastitis in Italy, 2013–2014. *Small Ruminant Research*, 141, 91-93.
4. Omaleki, L., Barber, S. R., Allen, J. L., & Browning, G. F. (2010). Mannheimia species associated with ovine mastitis. *Journal of Clinical Microbiology*, 48(9), 3419-3422.

5. Gebrewahid, T. T., Abera, B. H., & Menghistu, H. T. (2012). Prevalence and etiology of subclinical mastitis in small ruminants of Tigray Regional State, North Ethiopia. *Veterinary World*, 5(2), 103-109.
6. Mishra, A. K., Sharma, N., Singh, D. D., Gururaj, K., Kumar, V., & Sharma, D. K. (2018). Prevalence and bacterial etiology of subclinical mastitis in goats reared in organized farms. *Veterinary World*, 11(1), 20.
7. Cowan, S.T. (1974). Cowan and Steel's manual for the identification of medical bacteria. (3rd ed.). Cambridge. United Kingdom.
8. Quinn, P. J., Markey, B. K., Leonard, F. C., Hartigan, P., Fanning, S., & Patrick, E. S. F. (2011). *Veterinary Microbiology and Microbial Disease*. UK: John Wiley & Sons Ltd.
9. Clinical and Laboratory Standards Institute (CLSI). (2013). Performance standards for antimicrobial disk and dilution susceptibility tests for bacteria isolated from animals; Second informational supplement (Document VET01-S2). Wayne, PA, USA.
10. Kumar, J., Dixit, S. K., & Kumar, R. (2015). Rapid detection of *Mannheimia haemolytica* in lung tissues of sheep and from bacterial culture. *Veterinary World*, 8, 1073-1077.
11. Ruffin, R. P., Lawhon, S. D., Lubbers, B. V., & Capik, S. F. (2021). Evaluating the environmental survivability of *Mannheimia haemolytica* on various potential fomites. *The Bovine Practitioner*, 55(2), 120-124.