

## Changes in Histological Indices in the organs of New Zealand White Rabbits Treated with 2,2- Dichlorovinyl Dimethyl Phosphate.

### Abstracts

**Aim:** To assess the changes in histological indices in the organs of New Zealand white rabbits treated with 2, 2- dichlorovinyl dimethyl phosphate

**Study design:** This is an experimental study.

**Methodology:** A total of twenty four male New Zealand white rabbits, two months old weighing between 1.0 and 1.2 kg, were used for the study. They were divided into three (3) groups, each consisting of four (4) rabbits and a corresponding number of matched controls, for long-term toxicological effects of dichlorvos on the rabbits (30 days, 60 days and 90 days). The rabbits received ten (10%) of the LD50 dose. The LD50 dose was 0.05 mg/m<sup>3</sup>, while 10% of the median lethal dose of dichlorvos which was 0.005 mg/dl was diluted with 1.0 milliliter of distilled water. It was administered by oral route daily for the stipulated periods of thirty, sixty, and ninety days. At the end of each month, a set of rabbits in the experimental group with their matched control were sacrificed using chloroform. Organs of the liver, kidney, heart, and lungs were harvested from the rabbits at the stipulated period of thirty, sixty, and ninety days with their matched controls and were preserved in 10% formalin for histological examinations.

**Results:** Examination of organ tissues revealed alterations which depended on the duration of dichlorvos exposure. The Kidney slide showed tubular necrosis; the heart tissues showed degeneration of myocardial fibers with congestion of blood vessels; the liver tissues revealed gross hepatic necrosis, while the lungs tissues revealed area of inflammatory cell infiltrate and alveolar oedema when compared with their matched controls at 30, 60 and 90 days.

**Conclusion:** Examination of tissues of the heart, lungs, liver and kidneys revealed pathological changes on the dichlorvos treated rabbits when compared with their matched controls.

### INTRODUCTION

Dichlorvos (2, 2 dichlorovinyl dimethyl phosphate) is an organophosphate insecticide and pesticide. In Nigerian society, it is marketed by Swiss Nigerian chemical company under the trade name sniper (Owoeye *et al.*, 2019). Dichlorvos due to its effectiveness, has various uses, as a household insecticide and as an agricultural pesticide (Ogunsola, 2019).

Routes of human exposure to dichlorvos are by inhalation, oral and dermal contact. While inhalation route is considered the main exposure pathway in humans based on its

Commented [DBK1]: Percent

Commented [DBK2]: kidney

Commented [DBK3]: delete

Commented [DBK4]: delete

Commented [DBK5]: infiltrated with

Commented [DBK6]: Swiss

Commented [DBK7]: delete

volatility and current use patterns; (Wankasi et al., 2020); oral route exposure has been recorded in various cases of homicidal and suicidal deaths (Wang et al., 2004).

**Commented [DBK8]:** Based on its volatility and current use patterns, inhalation route is considered the main exposure pathway in humans

Dichlorvos exerts its toxic effects by irreversibly inhibiting acetyl cholinesterase enzyme. This leads to the accumulation of acetylcholine in the nervous tissues and muscular motor plates, causing many toxic effects (Okoroiwu, 2019).

**Commented [DBK9]:** Italics

**Commented [DBK10]:** Italics

Organs of dichlorvos toxicity are the CNS, lungs, heart, liver and the kidneys (Iman et al., 2018).

**Commented [DBK11]:** 2018, please check the year

**Commented [DBK12]:** on

**Commented [DBK13]:** Italics

Acute and prolonged exposure to dichlorvos has resulted in neurological illnesses, reproductive disturbances, hepatotoxicity, nephrotoxicity, respiratory complications, and death (Binukumar, 2016).

**Commented [DBK14]:** Missing in the bibliography

Bone marrow depression which resulted in Aplastic anaemia has also been reported in chronic exposure to dichlorvos (Mostafalous, & Abdollahi 2013).

**Commented [DBK15]:** 2017, please check the year

Increase in health challenges associated with dichlorvos exposure coupled with several cases of death reported as a result of dichlorvos poisoning demands a study on the chronic toxicological effects of dichlorvos through the histological assessment of the internal organs.

## 2. Materials and methods

### 2.1 Experimental Animals

For this investigation, twenty-four (24) two-month-old New Zealand white rabbits (*Oryctolagus cuniculus*) with an average weight of 1.0 kg were employed. The rabbits were bought from the Port Harcourt animal shelter at Rivers State University's Department of Biological Science. Oral and oral chronic experiments were conducted using them. The rabbits were housed for fourteen (14) days to acclimate, in a roomy, well-ventilated cage that was kept at room temperature and in accordance with their natural circadian cycle. They were housed in standard cages and allowed access to feed (Top Feed Finisher Mash, Sapele, Nigeria) and water *ad libitum* from the animal house, department of animal and environmental science, Rivers State University, Port Harcourt. All the animals received humane treatment according to the criteria outlined in the Guide for the Care and Use of Laboratory Animals prepared by the National Institute of Health.

### 2.2 Procurement and administration of Dichlorvos

A one-litre concentrated solution of the insecticide dichlorvos (DDVP) 1000EC, which contains one thousand milligrams of the compound 2-2 dichlorovinyl dimethyl phosphate, was bought in Nigeria from Swiss-Nigeria Chemical Company, the exclusive

**Commented [DBK16]:** to

distributor of dichlorvos in Nigeria. For the duration of the 30, 60 and 90 days specified in the chronic oral study, the rabbits received 1.0 milliliter of distilled water mixed with 10% of the lethal dose of dichlorvos, or 0.005 mg/kg. The matched control rabbits received only feed and water *ad libitum* during the study. Whilst, for the chronic oral study, 10% of the LD50 dose of dichlorvos which is equivalent to 0.005mg/m<sup>3</sup> dose of dichlorvos was mixed with 1.0ml of distilled water administered orally for the stipulated period.

### 2.3 Experimental Design

The rabbits were divided into three (3) groups of four (4) rabbits each with four (4) matched controls. A total of 6 cages were used for this experiment as shown below:

Duration	Chronic oral study	Matched control
0-30 days	4	4
0-60 days	4	4
0-90 days	4	4

### 2.4 Sample Collection, Storage and Analysis

#### 2.4.1 Sample collection

At day 30, 60 and 90, 4 rabbits were sacrificed each from the study group and from the matched control group. The organs were harvested and stored in 10% formalin for histological analysis

#### 2.4.2 Laboratory Investigation of Parameters

The histological study was carried out at Rivers State University Teaching Hospital, Port Harcourt, Rivers state, Nigeria.

##### 2.4.2.1 Histological Analysis

The kidneys, heart, liver, lungs and spleen were harvested for histological analysis, and were fixed in 10% formal saline solution. The organs were dissected and representative blocks were taken for histological processing each with identifying label in a tissue cassette. The fixed tissue blocks were dehydrated through ascending grades of alcohol, de-alcoholised in xylene, infiltrated and embedded in molten paraffin wax. Sections were cut at 3µm on a rotary microtome. Deparaffinised sections were then stained with the standard haematoxylin and eosin staining technique and the slides mounted in DPX.

Commented [DBK17]: formalin

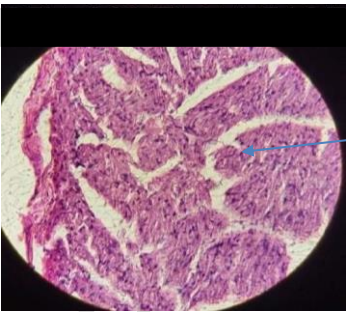Sections on slide were examined and photomicrographs captured with X400 objective lens using the ScopeTek™ device and software v1.3.

2.4.2.2 Staining Procedure

Paraffin wax was removed by dipping slide into xylene 1 and 2 for 1 minute each. The slide was immersed into absolute alcohol for 30 second and hydrated in descending grades of alcohol (90%, and 70%) for 30 seconds each. It was rinsed in tap water for 1 minute, stained with Erlich's hematoxylin for 30 minutes and rinsed in running tap water for minutes until colour turns blue. It was counterstained with 1% aqueous eosin for 5 minutes, and rinsed with tap water for 30 seconds. The slide was dehydrated by passing through ascending grades of alcohol (70%, and 90%) for 30 seconds each and immersed in absolute alcohol twice for 30 seconds each and was finally cleared in xylene for one minute.

RESULTS AND DISCUSSION

Histological examination revealed significant changes on sixty and ninety days' exposure, while at thirty days no significant changes was observed. The different rabbits exhibited different features such as focal inflammatory cells and cardiomyocyte necrosis.



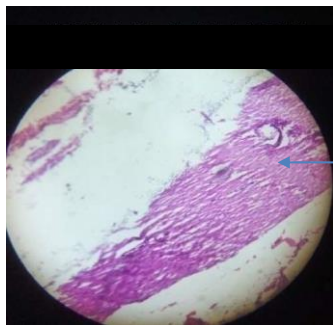
Branch bundle of  
Interventricular  
septum

281µm

Fig. 1: Photomicrograph of Normal Heart Tissue Showing Normal Atria, Interventricular Septa and Ventricles. H & E x400

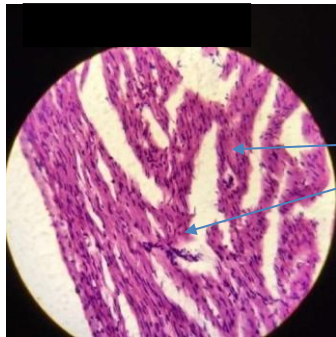
Commented [DBK18]: Heart

Commented [DBK19]: change



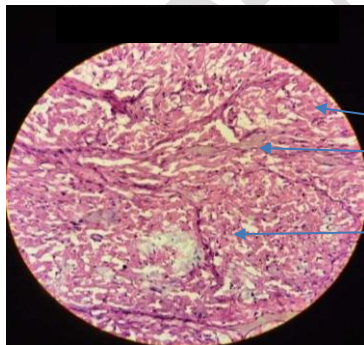
Cardiomyocyte

**Fig. 2: Photomicrograph of Heart Tissue exposed to dichlorvos for Thirty (30) Days Showing Areas of Cardiomyocyte. H & E x400.**



Focal inflammatory cells

**Fig .3: Photomicrograph of Heart Tissue Exposed to Dichlorvos for Sixty (60) Days Showing Area of Focal Inflammatory Cells H & E x400.**



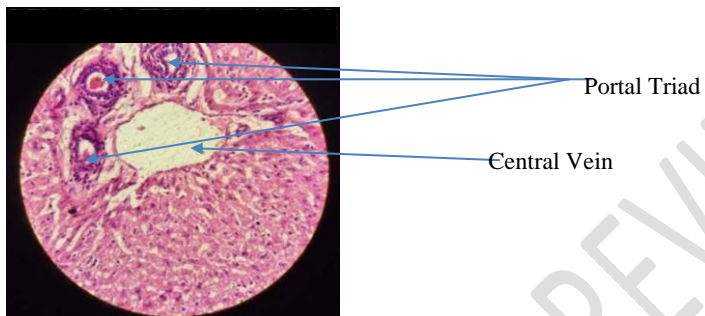
Cardiomyocytes

Cardiomyocyte necrosis

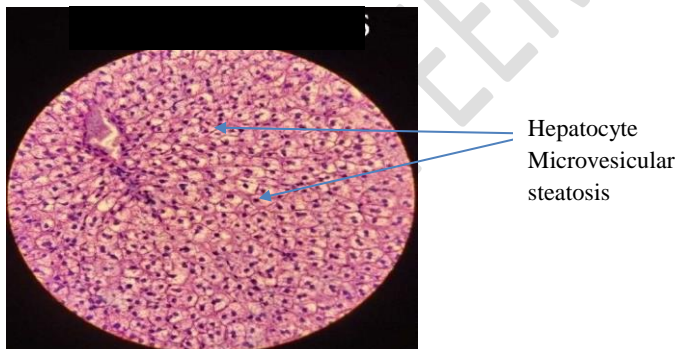
**Fig .4: Photomicrograph of Heart Tissue Exposed to Dichlorvos for Ninety (90) Days Showing Area of Cardiomyocyte Necrosis. H & E x400.**

## Liver

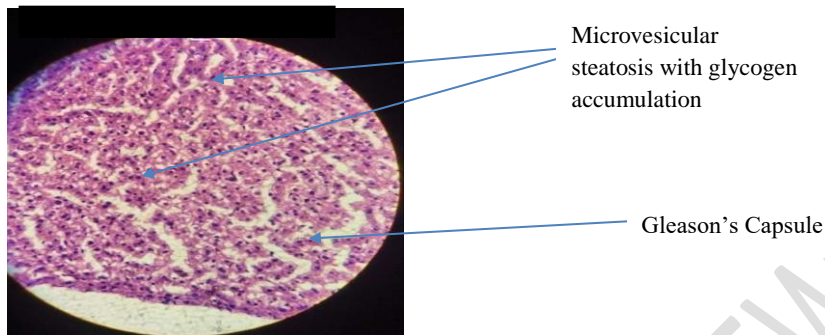
Histological examination revealed significant changes on thirty, sixty and ninety days' exposure. The different rabbits exhibited different features such as hepatocyte microvesicular steatosis with glycogen accumulation and hepatic necrosis.



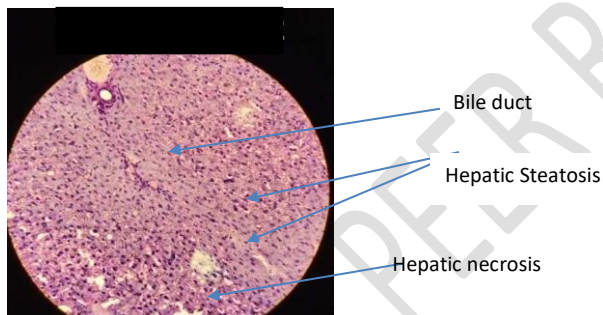
**Fig.5: Photomicrograph of Normal Liver Tissue Showing Normal Hepatic Morphology and Vasculature. H & E x400**



**Fig .6: Photomicrograph of Liver Tissue Exposed to Dichlorvos for Thirty (30) Days Showing Hepatocyte with Glycogen laden and Hepatocyte Microvesicular steatosis. H & E x400**



**Fig .7: Photomicrograph of Liver Tissue Exposed to Dichlorvos for Sixty (60) Days Showing Microvesicular Steatosis with Glycogen Accumulation. H & E x400.**



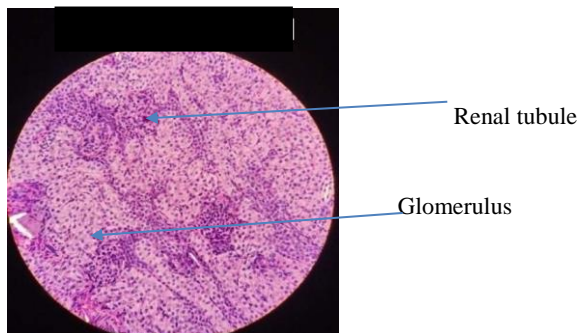
**Fig .8: Photomicrograph of Liver Tissue Exposed to Dichlorvos for Ninety (90) Days Showing Areas of Hepatic Steatosis and Hepatic Necrosis. H & E x400.**

### Kidney

Histological examination revealed significant changes on thirty, sixty and ninety days. The different rabbits exhibited different features such as mononuclear infiltrate, tubular degeneration, glomerulosclerosis, thickened glomerular membrane, dilated tubules, inflammation, thickened renal capsule, cellular infiltrate, tubular necrosis and renal papilla necrosis.

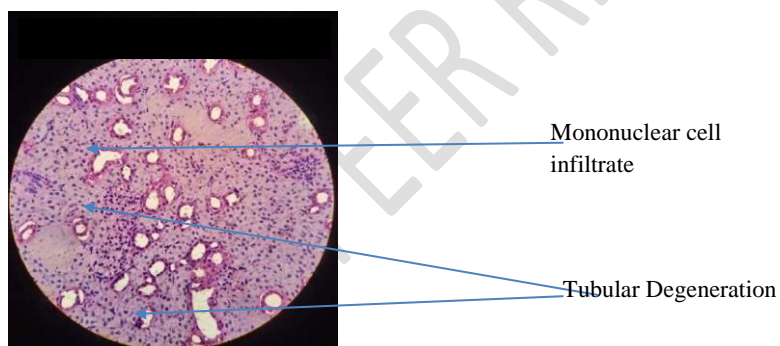
Commented [DBK20]: glomerulosclerosis





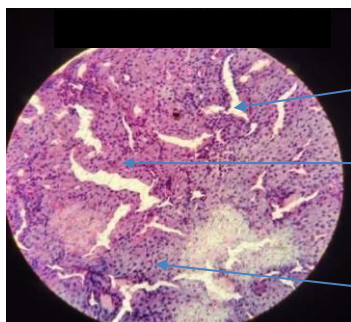
# **CONTROL**

**Fig .9: Photomicrograph of Normal Kidney Tissue Showing Normal Structure and Morphology of Kidney Tissue. H & E x400.**



**Fig .10: Photomicrograph of Kidney Tissue Exposed to Dichlorvos for Thirty (30) Days Showing Areas of Fibrosis, Tubular Degeneration and Mononuclear Cell Infiltrate. H & E x400.**



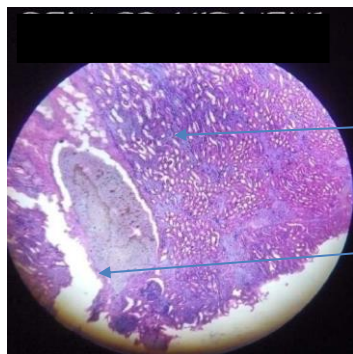


Dilated Tubules

Thickened Glomerular membrane

Tubular necrosis

**Fig .11: Photomicrograph of Kidney Tissue Exposed to Dichlorvos for Sixty (60) Days Showing Areas of inflammation and Necrosis. H & E x400.**



Tubular necrosis

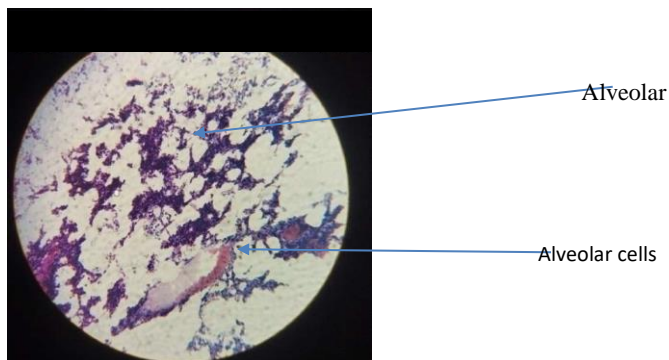
Renal papilla necrosis

**Fig .12: Photomicrograph of Kidney Tissue Exposed to Dichlorvos for Ninety (90) Days Showing Areas of Cellular Infiltrate and Necrosis. H & E x400.**

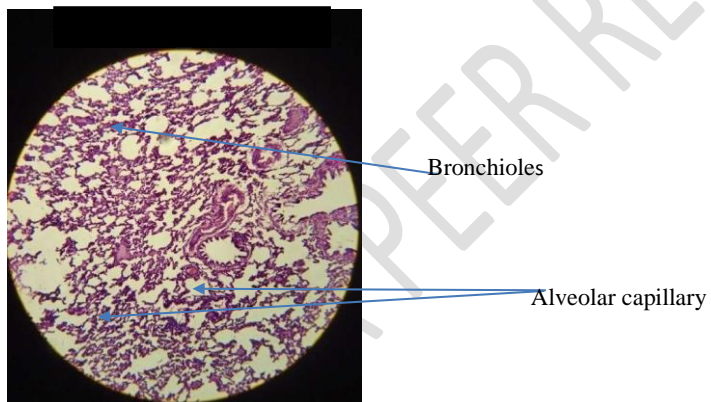
## Lungs

Histological examination revealed significant changes only on ninety days' exposure. Thirty and ninety days dichlorvos exposure caused no significant effect on the lungs as shown in the figures below. Inflammatory cell infiltrate was observed at day 90 dichlorvos exposure on the lung tissue.


Commented [DBK21]: sixty



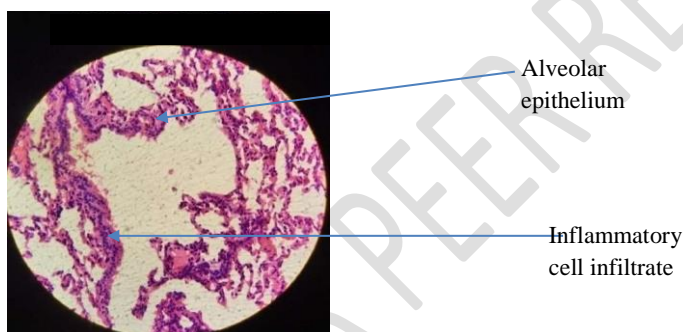
**Fig. .13: Photomicrograph of Normal Lungs Tissue Showing Normal Histoarchitecture of Alveoli, Bronchioles and Vasculature. H & E x400.**



**Fig .14: Photomicrograph of Lungs Tissue Exposed to Dichlorvos for Thirty (30) Days Showing Areas of Bronchioles, Alveolar Epithelial and Capillary Cells. H & E x400.**



**Fig .15: Photomicrograph of Lungs Tissue Exposed to Dichlorvos for Sixty (60) Days Showing Areas of Air Space, Bronchiole and Alveolar Epithelial. H & E x400**



**Fig 16: Photomicrograph of Lungs Tissue Exposed to Dichlorvos for Ninety (90) Days Showing Areas of Inflammatory Cell Infiltrate. H & E x400**

The results of the histomicrographic examination of tissue slides of the heart, kidney, liver and lungs were represented in figs 1 - 16.

The heart slides of the rabbits that were orally treated with dichlorvos at day 30 showed areas of focal necrosis; while the experimental rabbits at days 60 and 90 showed areas of cardiomyocyte necrosis. The histomicrograph of heart tissue of the non dichlorvos treated rabbit group (control) showed normal atria, interventricular septa and ventricles (normal histological architecture). Benjamin *et al.* (2020) also reported congestion, haemorrhage and necrosis of cardiac muscle fibres in wistar rabbits exposed to sublethal dose of dichlorvos.

Commented [DBK22]: delete

Commented [DBK23]: orally

Commented [DBK24]: in

Commented [DBK25]: Wistar

Similar results including severe shredding of cardiomyocytes were observed by (Ogunsola *et al.*, 2019) in an inhalation exposure of adult albino rats to dichlorvos for 90 days.

As shown in slides 4.9 – 4.12, the kidney slides of the rabbits that were orally treated with dichlorvos showed a duration dependent tubular and cellular necrosis, which included glomerular degeneration and congestion, tubular hypertrophy, areas of inflammation and thickened renal capsule. There were also areas of dilated tubules, interstitial fibrosis and gross tubular necrosis which became more marked at day 90 exposure.

Commented [DBK26]: Fig

Commented [DBK27]: Fig

Commented [DBK28]: delete

Commented [DBK29]: orally

Similar results including severe glomerular tubular necrosis caused by dichlorvos exposure were also reported in albino rats that were chronically exposed to dichlorvos for 90 days (Ogunsola *et al.*, 2019).

In the present study, liver of the rabbits that were orally exposed to dichlorvos (30-90) days showed areas of vacuolar degeneration, areas of diffuse hepatocyte microvesicular steatosis, hepatic necrosis and marked cytoplasmic vacuolization which were duration of exposure dependent. The histomicrograph of the control liver tissues (non dichlorvos treated rabbits) showed areas of normal portal traid and central areas of vein. Owoeye *et al.*, (2012) observed micro anatomical alterations including: portal traid and vessels which were completely obscured and appeared circumscribed by fibrous connective tissues, necrotic plaques, periportal cellular infiltration, and diffuse necrosis in rats that were exposed to dichlorvos for 4 weeks.

Commented [DBK30]: delete

Commented [DBK31]: orally

Damaged to the lungs in this study was characterized by accumulation of red blood cells, presence of area of alveolar epithelial cells and area of inflammatory cell infiltrate in the oral chronic study. The severity of the damages caused by the dichlorvos depended on the duration of the treatment. Normal histological pattern was observed in the lungs of the control group rabbits. These findings were consistent with those of (Owoeye *et al.*, 2012) who observed extension in the width of bronchial associated lymphoid tissue (BALT), mild generalized congestion of the peri-bronchiolar and inter alveolar septum in the lungs of rats exposed to dichlorvos before vitamin supplementation.

Commented [DBK32]: observed

Also, Benjamin *et al.* (2020) in their study observed thickened inter-alveolar walls, massive infiltration of the bronchiole by inflammatory cells, congestion and haemorrhages of wistar rats that were exposed to sub-lethal dose of a locally formulated pesticide.

Commented [DBK33]: delete

Commented [DBK34]: also

Commented [DBK35]: Wistar

**Conclusion:** The histopathological examination of the tissues revealed hepatic necrosis, tubular necrosis and respiratory distress of the lungs and degeneration of myocardial fibers with congestion of blood vessels.

Commented [DBK36]: in

## REFERENCES

Benjamin, B., Onwumere, G. B., Orakpoghenor, O., Egbe, N. E. & Dilli, D. D. (2020). Histopathological changes in the brain, heart and lungs of Wistar Rats Exposed to Sub-lethal Dose of a locally formulated pesticide Otapiapia.

*Archives of Pulmonology and Respiratory Medicine*, 3(1), 1 - 9.

Binukumar, B.K., Bal, A. & Gill, K.D. (2011). Chronic Dichlorvos Exposure: Microglial, Activation, Proinflammatory Cytokines and Damage to Nigrostratal Dopaminergic System. *Neuro Molecular Medicine*, 13, 251-265.

Imam, A., Busari, M. O., Adana, M. Y., Ajibola, M. I., Ibrahim, A., Sulaiman, F. A. & Ajao, M. S. (2018). Sub Chronic Dichlorvos Induced Cardio Toxicity in Wister Rats: Mitigate Efficiency of Nigella Naliva Oil. *Journal of Experimental and Clinical Anatomy*, 17(2), 60- 65.

Mostafalou, S. & Abdollahi, M. (2017). An update of Human exposure and toxicity. *Archives of Toxicology*, 91(2), 549-599.

Commented [DBK37]: Pesticides:

Ogunsola, J. O., Oridupa, O. A., Awotunsin, K. O. & Adebowale, B. S. (2019). Chronic Inhalation of 2, 2- Dichlorovinyl Dimethyl Phosphate (DDVP) Induces Organ Toxicity in Rats. *European Journal of Anatomy* 23(3), 151 – 158.

Okoroiewu, H.C. (2018). Dichlorvos Toxicity: A Public Health Perspective. *Interdisciplinary Toxicology*, 11(2), 129-137.

Owoeye, O., Edem, F. V., Akinyoola, B. S., Rahaman, S., Akpang, E. E. & Arinola, G.O. (2019). Toxicological Changes in the Liver and Lungs of Rats Exposed to Dichlorvos Before and After Vitamin Supplementation. *European Journal of Anatomy*, 6(3), 170 - 178.

Owoeye, O., Edem, F. V., Akinyoola, B. S., Rahaman, S., Akang, E. E. & Arinola, G. O. (2012). Histological Changes in Liver and Lungs of Rats Exposed to Dichlorvos before and after Vitamin Supplementation. *European Journal of Anatomy*, 16(3), 190 - 198.

Wang, H. H., Chou, Y. C., Liao, J. F. & Chen, C. F (2004). The Effect of the Insecticide Dichlorvos on Esterase Activity Extracted from the Psocids, *Liposcelis bostrychophila* and *L. entomophila*. *Journal of Insect Science*, 4, 1 - 5.

Wankasi, M. M., Agaro, E. S. & Ikimi, C. G. (2020). Vitreous Humor, Biochemical Parameters as Indicators corroborating Acute Sniper (Dichlorvos) Induced Death. *Journal of Forensic Technology and Pharmacology*, 9 (2), 168.

UNDER PEER REVIEW