

Case report

Occult obstructed inguinal hernia in female-a rarity

Abstract

Background: Groin hernia includes both inguinal and femoral variety but the incidence of inguinal hernia in females is relatively low. Hidden or occult obstructed inguinal hernia in females is a rarity that can turn into a catastrophic event owing to misdiagnosis. Hence, detailed clinical and radiological investigation is essential for diagnosis of occult inguinal hernia so as to prevent any untoward complications. Inguinal hernia surgery is one of the safest and effective procedures performed in surgical discipline. The aim of this study was to report a case of occult obstructed inguinal hernia with no specific symptoms.

Case presentation: Present case study was done on a 62-year old lady who presented with non-specific abdominal symptoms. Radiological investigations detected an occult obstructed bowel loop in the right inguinal region. She underwent open herniotomy with successful reduction of its content in viable form located lateral to Hesselbach triangle. Her post-operative recovery period was uneventful.

Conclusion: Diagnosis and intervention of occult obstructed inguinal hernia with non-specific symptoms should be done at the earliest to prevent any further complications like incarceration and strangulation.

Keywords: Occult, obstructed inguinal hernia, tissue repair

1. Introduction

Hernia is defined as an abnormal protrusion of viscera through normal openings in the body. Inguinal hernias are reported in surgical literature and have always been a subject of interest for the surgeons. They are mostly observed in males and are relatively uncommon in females with a male to female ratio of 6:1 [1, 2]. Incidence of inguinal hernia in females is reported as 1.9 % [2]. Their occurrence on the right side is 68.1 %, on the left side is 23.4 %, and bilaterally is 8.5 % [3]. Majority of the female inguinal hernias are symptomatic and appears as an inguinal lump or palpable swelling. Usually, the content of inguinal hernia sac in females consists of small intestinal loop and omentum while ovaries, fallopian tubes and uterus very rarely protrude into the hernia sac [4, 5]. Inguinal hernia repair surgery is a commonly done, safe and

effective surgical procedure for the treatment of this condition [6]. However, timely diagnosis and appropriate management of inguinal hernia are essential to prevent further complications such as incarcerations or strangulation. This syndrome should be considered as a differential diagnosis in females who present with lower abdominal pain or other abdominal symptoms [7]. Hidden or occult inguinal hernia in females owing to its rarity can be a diagnostic 'conundrum' thereby leading to disastrous consequences particularly in an acute setting. Devoid of a strong clinical suspicion of this condition can deviate the entire treatment modality and its triaging. Here, we present a case of occult obstructed inguinal hernia with non-specific abdominal symptoms in an older woman who was brought to the outpatient unit of our hospital.

2. Case Presentation: A 62-year old lady with hypertension and a past history of stroke presented to emergency unit of the hospital with nausea, vomiting, lack of appetite, and abdomen fullness. On arrival to the hospital, she was experiencing tachycardia, low blood pressure, pallor, moderate abdomen distension, and drowsiness. At first she was under the care of a physician. Blood parameters at that time showed moderate elevations in urea (237mg/dL), creatinine (Creatinine 2.0 mg/dL), sodium (118 m mole/L), potassium (3.4 n mole /L), Erythrocytes sedimentation rate (69 AEFH) and raised hepatic enzymes. Initially, she was managed with antibiotics, proton pump inhibitor, naso-gastric tube indwelling, and correction of fluid and electrolytes balance with regular monitoring of urine output. Ultrasonography (USG) and computed tomography (CT) of whole abdomen revealed herniation of omentum and a loop of small intestine of 5x2 cm in size through a 1.9 cm size defect at right inguinal region. The right inguinal region was further investigated under spinal anaesthesia and the obstructed segment comprising of grossly dilated non-ischemic small bowel loop with omentum filling up entirely a thick walled sac incarceration was noticed at deep inguinal ring situated lateral to Hesselbach triangle [8]. The contents were reduced slowly and carefully in to the peritoneal cavity by splitting open the indirect sac which was then excised followed by the repair of posterior wall of the inguinal canal adopting Bassini's technique without application of a mesh. Tissue repair was done for the posterior wall of inguinal canal in view of advanced age and lax musculature. The post-operative recovery process was uneventful. The patient was discharged with advice for regular follow-up which was done till 18 months. No recurrence of hernia was noted during the follow-up period.

3. Discussion: Inguinal hernias can occur in all ages in both men and women but commonly seen

in extremes of age groups such as in infants and elderly [9]. Hernias in the groin region emerges through the opening in the lower abdominal wall bounded by the transverses abdominis arch and supra-pubic ramus where it harbors spermatic cord in male and round ligament in female. The tendency of herniation through a weak point in the above region is more likely to happen in males. Hence inguinal hernia formation is much higher in males as compared to females. Factors which can increase the risk of hernia occurrence could be genetic, mechanical, and metabolic. Females similar to males who are suffering from chronic cough due to lung disease, obesity, constipation, and pregnancy are prone for developing inguinal hernia in their life span. Those patients who presumably possess a metabolic factor similar to the patient reported in this case study who was aged and had a history of stroke have a tendency to acquire defects in collagen architecture and its stability can also be a predisposition for this condition. Hydroxyproline, a major amino acid component of collagen is found to be less in the aponeurosis of groin hernia patients [10]. There is often a delay in diagnosis of hernia in females as specific clinical features of obstruction could be lacking as noticed in our patient since her symptoms of anorexia, vomiting, and flatulence would indicate any upper gastro-intestinal entity provided an inguinal lump was not palpable. Of course, swelling in the inguinal area if missed or not elicited clinically is not to be ignored as abdominal symptoms per se when corroborated by radiological investigations may reveal an irreducible or obstructed hernia. Further delay in surgical intervention by exploring the inguinal region could escalate the possibility of impending gangrene of a trapped bowel loop [11]. Our case report also reflects with certainty that due to non-palpability of a hernia in the inguinal region, she was initially managed by a physician considering paralytic ileus having a metabolic origin but after a meticulous search through radiological imaging, an occult obstructed inguinal hernia was revealed. Considering acute onset of clinical condition in the inguinal area, easy accessibility, shorter operating time, scope for regional anaesthesia, cost and low morbidity, open surgery for inguinal hernia is the preferred practical option [12]. Experience of strangulation in females with reference to placement of mesh in an obstructed setting is rather limited. However, a good tissue repair of the hernia without a mesh can produce a favorable outcome. Surgery for inguinal hernia in females is stated to be around 11 per 100000 patients and those coming with features of obstruction or strangulation in females for the first time falls within 5 -10 % [9].

4. Conclusion: recent onset of symptoms should alert the attending physician or surgeon in the emergency room for a proper clinical evaluation and to be subjected to necessary imaging techniques be it an USG or CT scan abdomen. Urgent or timely surgical intervention could save an obstructed bowel loop from getting ischemic and necrotic, thereby mitigating an adverse outcome.

Disclaimer (Artificial Intelligence): I hereby declare that no generative AI technologies such as Large Language Models (ChatGPT, COPILOT, etc) and text-to-image generators have been used during writing or editing of manuscripts.

References

1. Bhatta S, Ojha H, Ansari MA, Shrestha A. Bilateral indirect ovarian inguinal hernia in a young female with type 1 Mayer–Rokitansky–Küster–Hauser syndrome: An extremely rare clinical context. *Clin Case Rep*; 2024.
2. Victor C, Selvakumar RJ, Jesudason MR. A Rarity Seen in Female Inguinal Hernias. *J Med Sci Clin Res*; 2018.
3. Ismael DN, Hammood ZD, Kakamad FH, Qadr GA. Obstructed inguinal hernia containing female reproductive organ: A rare presentation. *Int J Case Rep*; 2017.
4. Ballas K, Kontoulis T, Skouras C, Triantafyllou A, et al. Unusual findings in inguinal hernia surgery: report of 6 rare cases. *Hippokratia*; 2009.
5. Gurer A, Ozdogan M, Ozlem N, Yildirim A, et al. Uncommon content in groin hernia sac. *Hernia*; 2006.
6. Kumar A, Anil Kumar A, Anwer M, Kumar D. Case of mullerian agenesis presenting as bilateral inguinal hernia with left sided irreducibility in a 21 years old female: A rare case report. *Int J Surg Case Rep*; 2023.
7. Herrington JK. Occult inguinal hernia in the female. *Ann Surg*; 1975.
8. Nyhus LM, Klein MS, Rogers FB. Inguinal hernia. *Cur Probl Surg*; 1991.
9. Rosen A, Nathan H, Luciansky E, Orda R. The inguinal region: anatomic differences in men and women with reference to hernia formation. *Acta Anat (Basel)*; 1989.
10. Read RC. Collagen synthesis and direct inguinal herniation. In Arregui ME, Nagan RF (eds): *Inguinal Hernia Advances or Controversies?* Oxford, England, Radclif Medical, 1994

11. Playforth RH, Holloway JB, Griffen WO. Mechanical small bowel obstruction: a plea for earlier surgical intervention. *Ann Surg*; 1970
12. Schmedt CG, Sauerland S, Bittner R. Comparison of endoscopic techniques vs. Lichtenstein and other open mesh techniques for inguinal hernia repair: a meta-analysis of randomized controlled trials. *Surg Endosc*; 2005

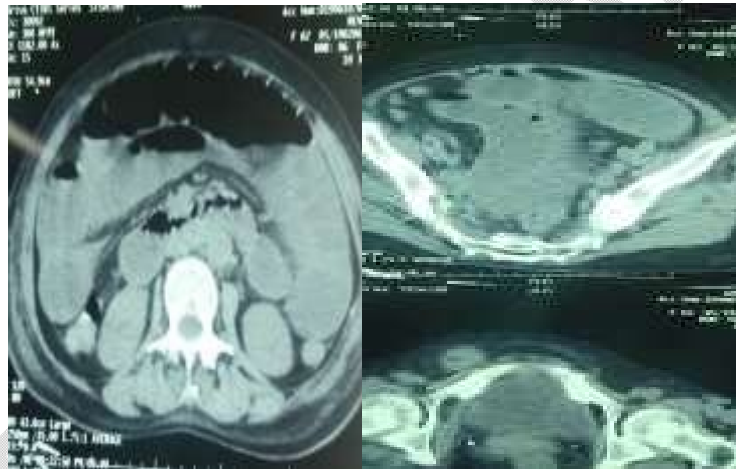


Fig 1: Herniation seen in the right inguinal region as observed in the CT scan

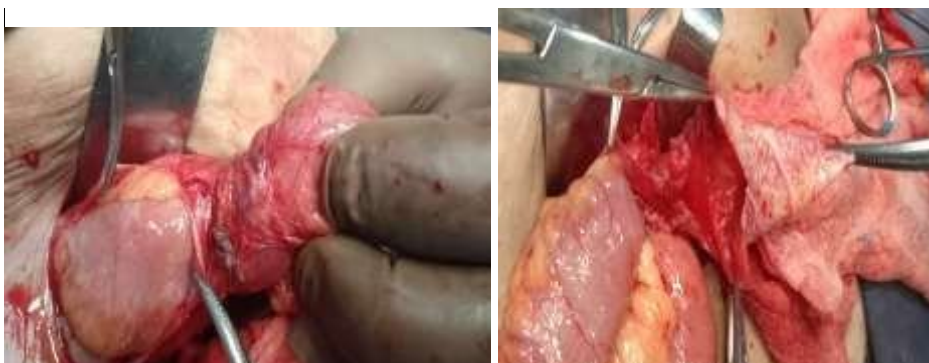

Fig 2: Omentum and small intestine as content of right inguinal hernia

UNDER PEER REVIEW