



Systematic Review

SCLEROSING POLYCYSTIC ADENOSIS OF MINOR SALIVARY GLANDS: A SYSTEMATIC REVIEW

Abstract:

Introduction: Sclerosing polycystic adenosis (SPA) is a rare salivary gland condition resembling sclerosing adenosis of the breast, with both reactive and neoplastic characteristics. It has been reported in over 60 cases globally, primarily affecting major salivary glands, with fewer cases involving minor salivary glands.

Aim: This systematic review analyzes demographics, clinical features, histopathology, differential diagnosis, treatment, and outcomes of SPA cases in minor salivary glands.

Method: A systematic review of case reports/series on minor salivary glands SPA was conducted. Data on demographics, clinical and histopathological features, diagnosis, and treatment were tabulated.

Results: Thirteen cases were analyzed, out of 13 cases, 10 (76.9%) males and 3 (23.1%) females, aged 19–82 years. All presented with slowly-growing, painless masses lasting 2 months to 8 years. Histologically, lesions showed lobular proliferation of ducts, myoepithelial cells, and acini with hyalinized fibrosis. Six cases had apocrine metaplasia resembling atypical ductal hyperplasia of the breast; seven lacked apocrine features.

Conclusion: The presence of apocrine metaplasia may correlate with SPA prognosis. Oral pathologists should recognize the clinical and histopathological features to ensure accurate diagnosis and treatment.

Introduction

Sclerosing polycystic adenosis (SPA) is a rare condition affecting the salivary glands, characterized by an inflammatory process that can be either reactive or neoplastic in nature. Resembling sclerosing adenosis of the breast, SPA has been reported in just over sixty cases globally since its initial identification. Most occurrences involve the major salivary glands with fewer cases affecting minor salivary glands (MSG).¹

SPA has been reported across a wide age range, but it typically occurs in middle-aged adults. There is a slight female predominance. Patients typically present with a painless swelling in the oral cavity, commonly on the palate or buccal mucosa. A definitive diagnosis is usually made through a biopsy, which reveals the distinctive histological features. This condition is marked by the presence of cystic spaces lined with epithelium, areas of squamous metaplasia, and stromal sclerosis.^(2,10,11,12,13,14)

Histologically, SPA represents as sharply circumscribed, mostly unencapsulated lesions composed of acinar and ductal components with diverse cytomorphological characteristics.³ These features include foamy, vacuolated, apocrine, mucous, clear/ballooned, squamous, columnar, and oncocyte-like cells.⁴ A distinctive nature of SPA is the presence of large acinar cells with abundant eosinophilic cytoplasmic granules. The stroma is often densely collagenized, and may contain a chronic inflammatory infiltrate of variable intensity, occasionally accompanied by fat. Rarely, the stroma may exhibit myxoid. Intraductal epithelial proliferation is observed in at least 50% of cases.⁵

Immunohistochemical analysis shows that both ductal and acinar cells are positive for broad-spectrum cytokeratins. Variable immunoreactivity has been reported for epithelial membrane antigen (EMA) and S-100 protein. Carcinoembryonic antigen (CEA), p53, and HER2 are reportedly negative. The proliferative index, measured by Ki-67, is low (1–2%) in the benign acinar and ductal components.⁶

Treatment primarily involves surgical excision of the lesion, particularly when it causes symptoms or concerns regarding malignancy. The prognosis is generally good, as SPA is a benign lesion with low recurrence rates after surgical removal. However, regular follow-up may be necessary to monitor for recurrence or complications.^(15,16,17,18,19)

This systematic review aims to present a comprehensive analysis of demographic details, clinical features, histopathological patterns, differential diagnosis, treatment approaches and the outcomes of the cases of sclerosing polycystic adenosis of minor salivary gland found in the literature in English.

Another objective was to improve the understanding of the lesions with respect to their clinical characteristics, diverse histopathological morphology and prognosis. This systematic review has been registered in the International prospective register of systematic review

PROSPERO (<https://www.crd.york.ac.uk/PROSPERO/record.php> Record Id -CRD42024495741)

Materials and method:

Case reports and case series on sclerosing polycystic adenosis (SPA) of minor salivary gland were retrieved through a systematic search of scientific databases. The databases include Ovid (Walter Kluwer, New York, USA), Medline (National Library of Medicine, Maryland, USA), PubMed Central (National Library of Medicine), Web of Science Citation Index Expanded (Clarivate Analytics, London, UK) and Google Scholar (Google, Mountain View, USA). The searches used keywords such as ‘sclerosing polycystic adenosis’ OR ‘minor salivary gland’ and ‘oral mucosa’. Retrieved literature was reviewed to identify cases with clinical features, histopathological characteristics and differential diagnosis. Case reports prior to year 2007 were excluded from this review. An independent researcher screened the databases and identified 157 relevant studies.

Reference checks of the cases identified were made to help snowballing or networking of the cases. The collected data was organised into a table regarding the author, year of publication, demographic data such as age, gender, clinical features, histopathological features, and differential diagnosis and treatment documented for each case report included.

Protocol

- The study protocol was designed in accordance with the PRISMA-P (Preferred Reporting Items for Systematic reviews and Meta-Analysis-Protocols) guidelines (2015).

Search strategy

- Case reports and Case series were identified by systematic searches across databases- Pubmed, Google Scholar, Cochrane library.
- A systematic search of PUBMED was done. The searches focused on terms “Minor salivary glands, Sclerosing polycystic adenosis, Oral mucosa.”
- All the search articles were in English, published between 2007- 2021 were included.

Eligibility criteria

Inclusion criteria

Following articles were included

1. case reports and case series on patients with sclerosing polycystic adenosis of minor salivary gland
2. Articles published in English
3. Case reports and case series reports between 2007-2021

Exclusion criteria

Following articles were excluded:

1. Case reports and case series on patients with sclerosing polycystic adenosis of major salivary gland
2. Articles published in language other than English
3. Review articles
4. Abstracts without full text availability
5. Randomized and nonrandomized clinical trials
6. Articles with incomplete data
7. Unpublished data.

Selection:

The study selection process consisted of three steps. All the titles were reviewed and appropriate studies were selected based on the inclusion and exclusion criteria. For all the selected titles, abstracts were obtained, reviewed and appropriate abstracts were identified based on the selection criteria. Full-text articles were obtained, analyzed, and filtered to create dataset.

The initial search strategy yielded 639 references. After removing duplicates and irrelevant studies, the number of references reduced to 157. Based on further screening of titles and abstracts the final number of selected studies was 11.

The main reason for exclusion were review articles without new cases, (n= 6), studies *related to title* (n= 3), *abstracts only* (n=6) and *articles in languages other than English* (n=6)

Study characteristics:

Fig -1-PRISMA FLOWCHART OF STUDY SELECTION

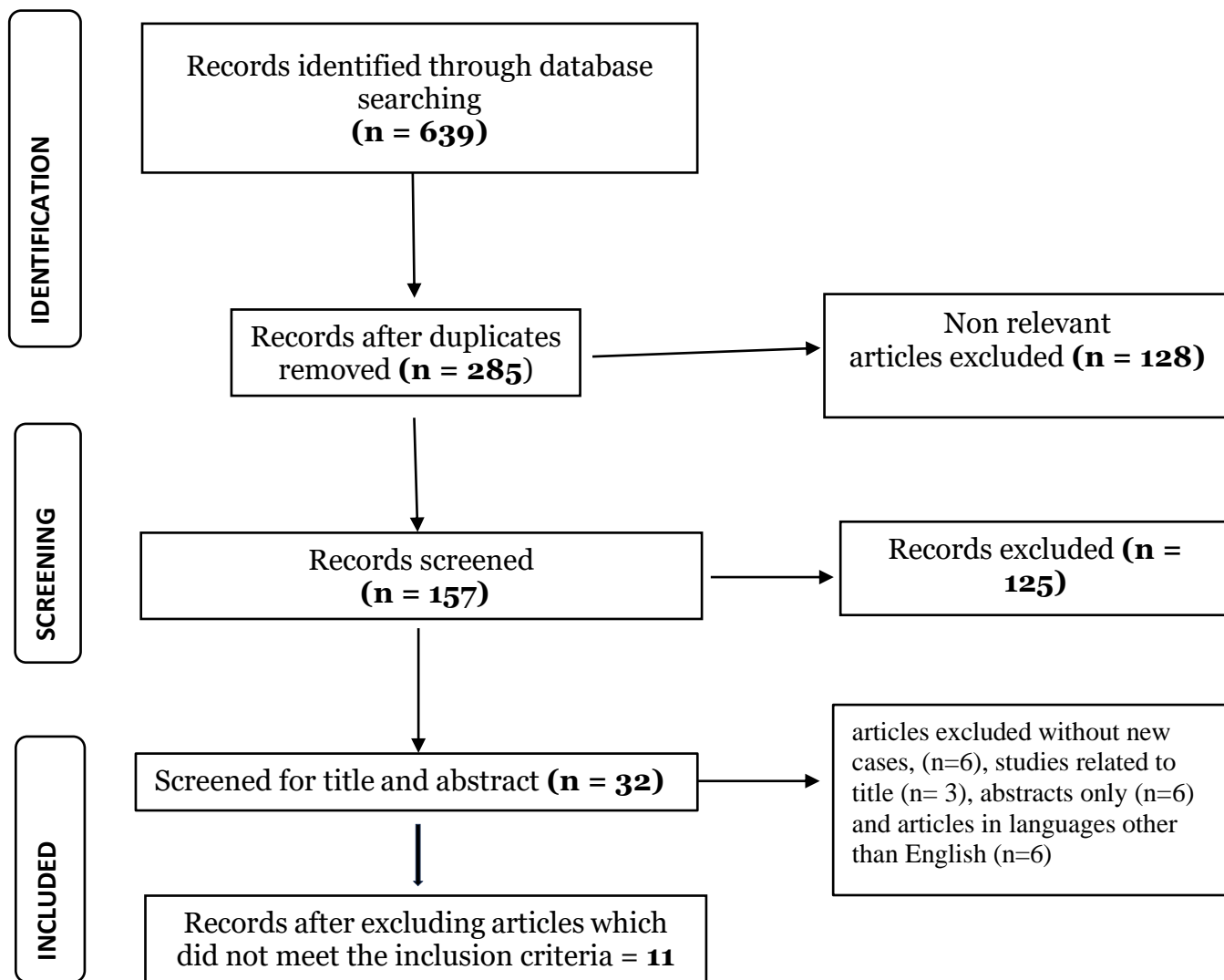




Table 1-List of case reports included

Sr. no.	Author	Year	Title
1	Shabnum Meer Æ Mario Altini et al ¹⁰	2008	Sclerosing Polycystic Adenosis of the Buccal Mucosa
2	Clarissa Araújo Silva Gurgel et al ¹¹ ,	2010	Sclerosing Polycystic Adenosis of the minor salivary gland: case report
3	Il-Ho Park et al ¹²	2010	Sclerosing Polycystic Adenosis of the Nasal Septum: The Risk of Misdiagnosis
4	SepidehMokhtari ¹³	2014	Sclerosing Polycystic Adenosis of the Retromolar Pad Area: A Case Report
5	Braz-silva Ph et al. ¹⁴	2017	Sclerosing Polycystic Adenosis of The Minor Salivary Glands: A Case report
6	Rudrayya Shivanand Puranik et al ¹⁵	2018	Sclerosing polycystic adenosis of lower lip: A new and rare salivary gland entity
7	Khemanand M. et al ¹⁶	2018	Sclerosing Polycystic Adenosis of The Minor Salivary Glands: A Case Report
8	Beena VT, Kavitha A, et al ¹⁷	2019	Sclerosing Polycystic Adenosis: A Rare and Unusual Lesion of the Salivary Gland
9	Guduguntla Pet al ¹⁸	2019	Sclerosing polycystic adenosis of hard palate: A rare entity in salivary glands.
10	Das SN et al ¹⁹	2021	Sclerosing polycystic adenosis of minor salivary glands: Report of a rare case with diagnostic approach and review of literature
Case series included			
11	Vikki L. Noonan et al ⁶ .	2007	Sclerosing polycystic adenosis of minor salivary glands: report of three cases and review of the literature

Risk of bias and quality assessment:

- The ‘Critical Appraisal Tools for Use in JBI Systematic Reviews’ was used to evaluate the quality of 13 cases.

Results:

A total of 10 Case reports and 1 Case series with 3 cases meeting the inclusion criteria were identified, comprising 13 participants. A summary of all cases reported to date is presented in Table 1. Of the 13 cases which were satisfying inclusion criteria were considered in review. Out of 13 cases 10 (76.9%) cases were male. While 3 (23.1%) were female. SPA of

minor salivary glands was observed across a wide age range, with the youngest reported patient being 19 years old, and the oldest (our case) being 82-year-old patient. The mean age of SPA was 52.5 years with 23.1% of cases occurring in 2nd and 3rd decade. The tumors ranged in size from 0.5 to 3 cm with mean dimension of 2.4 cm. Clinical information was limited in these consult cases. Clinically all patient presented with slowly-growing, painless mass. The duration of lesion varied between 2 months to 8 years, with 4 cases were unsure of the time of its precise onset.

Histologically, all cases demonstrated the classic diagnostic features of SPA. The lesions were well-circumscribed, lobular proliferations of haphazardly arranged ducts, myoepithelial cells, and acini separated by frequent bands of hyalinized fibrosis. The ducts ranged from small ductules to cystically dilated spaces often containing secretory material or foamy macrophages. All cases demonstrated variable numbers of serous acinar cells with altered zymogen granules which appeared as brightly hyper-eosinophilic intracytoplasmic granules. Six cases harbored apocrine metaplasia with intraluminal proliferations resembling atypical ductal hyperplasia of the breast; while the remaining seven cases lacked apocrine features.

The differential diagnosis for SPA includes polycystic disease, Fibrocystic disorders of the breast, sclerosing sialadenitis, as well as benign and malignant glandular neoplasia, and reactive phenomenon. Surgical excision of the mass was the treatment of choice for all cases. In this present review of thirteen cases, six cases with follow-up information showed no recurrence after a period of 5 months to 24 months with mean of 13 months whereas other cases were not having any information regarding recurrence.

Discussion:

Sclerosing polycystic adenosis was first described by Smith et al. in 1996. The exact nature of this lesion is unknown, but it bears a striking resemblance to benign cystic fibroadenosis of the breast, exhibiting pseudo-neoplastic, reactive, and inflammatory characteristics.¹

This lesion clinically SPA often presents as a painless swelling in the oral cavity. Most commonly on the palate or the buccal mucosa. The lesion is marked by cystic spaces lined with epithelium, areas of squamous metaplasia and stromal sclerosis.^{2,3,4,5} Diagnosis is usually confirmed through biopsy, which reveal its distinctive histological features.⁶

The pathogenesis of sclerosing polycystic adenosis (SPA) remains unclear, but recent studies suggest a potential association with Epstein–Barr virus (EBV). This correlation is supported

by the expression of EBV and Bcl-2 at the molecular level. EBV may upregulate the latent membrane protein 1 and directly or indirectly suppress Bax, contributing to the upregulation of Bcl-2. Additionally, EBV-encoded small RNAs may enhance the translation of the Bcl-2 gene, possibly by inactivating protein kinase R. As a gamma herpesvirus, EBV contains a single viral Bcl-2 homolog that encodes a protein preventing apoptotic death in virus-infected cells. This etiopathogenic pathway supports the neoplastic nature of SPA.⁸

Justin A. Bishop et al. (2020) highlighted that SPA has been an enigmatic entity since its initial description. While it resembles fibrocystic changes of the breast, SPA is set apart by its unique mixture of ducts, myoepithelial cells, and acini (including those with altered zymogen granules). This distinguishes it from other well-described lesions, whether salivary gland-related or otherwise. Initially, SPA superficial similarity to fibrocystic changes and its distinct appearance from any known neoplasm led to the belief that it was a reactive, non-neoplastic process.⁴

In the 2022 5th Edition of the World Health Organization Classification of Head and Neck Tumours, SPA remained classified as a reactive, non-neoplastic process. Despite this SPA exhibits several characteristic features suggesting its neoplastic nature. Notably, SPA lesions are well-circumscribed and often encapsulated, with a reported low but significant risk of local recurrence (approximately 10%).⁷

Juan C. et al. (2022) proposed that recurrent mutations in the PI3 kinase pathway, particularly in the PTEN gene, confirm the neoplastic nature of SPA. These mutations also suggest a connection with apocrine intraductal carcinoma (IC) and salivary duct carcinoma (SDC).⁸

Further, Canas Marques R et al. (2014) suggested that most cases of SPA contain a proliferation of apocrine ductal cells with a rigid cribriform appearance and nuclear atypia, resembling apocrine intraductal neoplasia of the breast.⁹ Although no SPA patient has developed metastases or died from the disease, there have been reports of at least three patients developing invasive carcinoma with an apocrine ductal phenotype arising from SPA.⁹

Gnepp DR. et al. (2006) highlighted that cytological atypia or dysplasia within some SPA cases has fueled controversies about its nature. Atypia can be found within the ductal epithelial cells, ranging from mild to severe dysplasia and carcinoma in situ.²⁰

Beena VT, Kavitha A, et al. (2019) demonstrated that special staining with periodic acid-Schiff (diastase-resistant) (PAS-D) and mucicarmine confirm the presence of intracellular mucin in cases of sclerosing polycystic adenosis (SPA). The eosinophilic granules often show positivity for PAS staining.¹⁷ For further confirmation, immunohistochemistry is performed with adequate controls. The lining cells of the ductal and tubulo-acinar elements display positivity



for cytokeratin (AE1/AE3) while maintaining the normal lobular architecture. Both the ductal cells and the spindled myoepithelial cells surrounding the ductal and acinar structures show positivity for the S-100 protein. Myoepithelial cells at the periphery of the acini and ducts showed positivity for α -SMA. The proliferative index (Ki-67) with very low (<2%) in the acinar and ductal components.¹⁹

The histopathological differential diagnosis of SPA includes reactive, benign and malignant entities such as;

a. Pleomorphic adenoma is characterized by neoplastic proliferation of glandular and myoepithelial component in a stroma varying from fibromyxoid or chondroid or osteoid or combination of them. However, lack of intraductal proliferation and apocrine and sebaceous elements differentiates from SPA

b. Chronic sclerosing sialadenitis (Kutner's tumor), a rare lesion of submandibular gland, shows remarkable replacement of salivary gland parenchyma by fibrosis and lymphoplasmacytic infiltration accompanied with periductal fibrosis. Absence of ductal changes of hyperplasia and cellular changes delineate from SPA

c. Polycystic disease (dysgenetic); This rare disorder shares certain features with SPA such as lobular proliferation of cystically dilated ducts replacing gland parenchyma. However, it predominantly affects females bilaterally and lack intraluminal proliferations distinguishing it from SPA. Additionally, intraluminal microliths are frequently reported in polycystic disease.

d. Cystadenocarcinoma and SPA both exhibit features of cystic and ductal proliferations including apocrine changes to some extent; However, cystadenocarcinoma is typically exhibits papillary growth and invasive behavior.

e. Malignancies like mucoepidermoid carcinoma, salivary duct carcinoma and acinic cell carcinoma can be ruled out based on their classical histological and cytomorphologic features.

On the basis of the available clinical features of the reported cases, SPA lesion are most commonly seen in the parotid gland (80%) followed by the rare involvement of the submandibular gland and more recently, the minor salivary glands of the nasal septum, mucobuccal fold, hard palate, floor of the mouth, buccal mucosa, retromolar pad, and ventral surface of the tongue. The age range of affected individuals is broad spanning from 9 years to 84 years with most of cases occurring in the fourth and fifth decades of life. The condition affects both males and females, with a slight male predilection in minor salivary gland cases.

In the reported cases, SPA involving minor salivary glands presents over a wide age range, with the youngest reported patient being 19 years of age, while the oldest was 82-year-old patient. The mean age of patients SPA was 52.5 years with 23.1% cases in the 2nd and 3rd

decades of life.

SPA can arise in any minor salivary gland. Among 13 reported cases, 2 cases occurred in the buccal mucosa, 2 in the lower labial mucosa, 2 in the floor of the mouth, and 3 cases involved the palatal minor salivary glands. The other cases involved the ventral surface of the tongue, maxillary mucobuccal fold, retromolar area, and nasal septum.

The tumors size ranged from 0.5 to 3 cm in greatest dimension with a mean size of 2.4 cm. The lesion always occurs as an solitary uni-focal lesion, although multi-focal lesions have been reported in some studies.

Clinically SPA present as showed a well-defined solitary, round to oval, soft to firm and slowly growing, painless mass was reported in all patients. The tumour in typically homogenous in consistency, partly movable with no associated tenderness or ulceration. In a few cases, the overlying mucosa appeared normal to slight reddish in color.

Histologically, all cases demonstrated the classic diagnostic features of SPA. The lesions were well-circumscribed, with lobular proliferations of haphazardly arranged ducts, myoepithelial cells, and acini separated by frequent bands of hyalinized fibrosis. The ducts varied in size ranging from small ductules to cystically dilated spaces often containing secretory material or foamy macrophages. All cases demonstrated variable numbers of serous acinar cells with altered zymogen granules in the form of brightly hyper-eosinophilic intracytoplasmic granules. Six cases harbored apocrine metaplasia with intraluminal proliferation resembling atypical ductal hyperplasia of the breast; the remaining seven cases lacked apocrine features.

The unique combination of features seen in SPA poses a broad differential diagnosis which includes non-neoplastic lesions (e.g., obstructive sialadenitis), benign neoplasms (e.g., pleomorphic adenoma), and malignancies of various grades (e.g., acinic cell carcinoma and salivary duct carcinoma).

Surgical excision of the mass is the most opted treatment for SPA. Among the cases six patients with available follow-up information showed no recurrence after a follow-up period of 5 months to 24 months (mean followup, 13 months) information about recurrence was not available for 3 cases.

Conclusion

In summary, sclerosing polycystic adenosis (SPA) of minor salivary glands may show a distinct male predilection for occurrence, it present wide age range distribution and can involve any of the minor salivary glands. From the present pieces of evidence, the presence of apocrine metaplasia with intraluminal proliferation resembling atypical ductal hyperplasia of the breast can be correlated with the prognosis of SPA. Oral pathologist should be familiar with clinical, histological and immunohistochemical features of SPA to avoid misdiagnosis. Further studies with larger datasets are necessary to confirm these findings.

Limitations

Given the rarity of the disease, this review included case reports and case series as these constitute the only data available in the literature. However, such data are generally considered lower quality on the scales used to evaluate cohort studies, case-control studies, and randomized controlled trials. For this reason, a meta-analysis could not be performed. Additionally, case reports and case series carry an inherently higher risk of bias, and combining data from such sources introduces further concerns.

References

1. Tang CG, Fong JB, Axelsson KL, Gurushanthaiah D. Sclerosing polycystic adenosis: a rare tumor of the salivary glands. *The Permanente Journal*. 2016;20(2):e113.
2. Gnepp DR, Wang LJ, Brandwein-Gensler M, et al. Sclerosing polycystic adenosis of the salivary gland: a report of 16 cases. *Am J Surg Pathol* 2006; 30:154–64.
3. Petersson F. Sclerosing polycystic adenosis of salivary glands: a review with some emphasis on intraductal epithelial proliferations. *Head and neck pathology*. 2013 Jul;7: 97-106.
4. [Justin A.Bishop](#), Sclerosing Polycystic “Adenosis” of Salivary Glands: A Neoplasm Characterized by PI3K Pathway Alterations More Correctly Named Sclerosing Polycystic Adenoma [Head Neck Pathol](#). 2020 Sep; 14(3): 630–636
5. Juan C. et al Sclerosing Polycystic Adenoma: Conclusive Clinical and Molecular Evidence of Its Neoplastic Nature [Head Neck Pathol](#). 2022 Jun; 16(2): 416–426
6. Vikki L. Noonan et al, Sclerosing polycystic adenosis of minor salivary glands: report of three cases and review of the literature *Oral Surg Oral Med Oral Pathol Oral Radiol*

Endod 2007;104:516-20

7. Alena Skálová1 et al, Update from the 5th Edition of the World Health Organization Classification of Head and Neck Tumors: Salivary Glands Head and Neck Pathology (2022) 16:40–53
8. Hernandez-Prera J, Heidarian A, Wenig B. Sclerosing polycystic adenoma: conclusive clinical and molecular evidence of its neoplastic nature. *Mod Pathol.* 2021;34(S2):773–4.
9. Canas Marques R, Felix A. Invasive carcinoma arising from sclerosing polycystic adenosis of the salivary gland. *Virchows Arch.* 2014;464:621–5.
10. Shabnum Meer Mario Altini et al, Sclerosing Polycystic Adenosis of the Buccal Mucosa Head and Neck Pathol (2008) 2:31–35
11. Clarissa Araújo Silva Gurgel et al, Sclerosing Polycystic Adenosis of the minor salivary gland: case report *Braz J Otorhinolaryngol.* 2010;76(2):272.
12. Il-Ho Park et al, Sclerosing Polycystic Adenosis of the Nasal Septum: The Risk of Misdiagnosis *Clinical and Experimental Otorhinolaryngology* Vol. 6, No. 2: 107-109, June 2013
13. Sepideh Mokhtari et al, Sclerosing Polycystic Adenosis of the Retromolar Pad Area: A Case Report Hindawi Publishing Corporation Case Reports in Pathology Volume 2014, Article ID 982432, 4 pages
14. Braz-silva Ph et al. Sclerosing Polycystic Adenosis of The Minor Salivary Glands: A Case report, *bull Tokyo dent coll*(2018) 59(2): 121-125
15. Puranik RS, Shree VG, Puranik SR, Anigol PS. Sclerosing polycystic adenosis of lower lip: A new and rare salivary gland entity. *J Oral Maxillofac Pathol* 2018;22:263-5.
16. Khemanand Maharaj Sclerosing Polycystic Adenosis of The Minor Salivary Glands: A Case Report september 2018 DOI: 10.13140/RG.2.2.17409.68966
17. Beena VT, Kavitha A, *et al.* Sclerosing Polycystic Adenosis: A Rare and Unusual Lesion of the Salivary Gland. *Oral Maxillofac Patho J* 2019;10(2):95–98.
18. Guduguntla P, Korlepara R, Guttikonda VR. Sclerosing polycystic adenosis of hard palate: A rare entity in salivary glands. *Contemp Clin Dent* 2019; 10:676-8.
19. Das SN, Jyoti K, Rath R, Pattnaik B. Sclerosing polycystic adenosis of minor salivary glands: Report of a rare case with diagnostic approach and review of literature. *J Oral Maxillofac Pathol* 2020; 24:590-1.
20. Gnepp DR. et al, Sclerosing polycystic adenosis of salivary gland: a lesion that may be associated with dysplasia and carcinoma in situ. *Adv Anat Pathol.* 2003;30(4):218-22.