

Original Research Article

INTERLEUKIN-6 AND MYELOPEROXIDASE MODULATING POTENTIALS OF CORTICOSTEROID -MUPIROICIN CREAM ON INFECTED WOUNDS IN MALE WISTAR RATS.

Abstract

Background- A wound is disruption of the normal architecture and function of any tissue. Wound infection results from microbial invasion of soft tissue and poses considerable clinical challenges including delayed healing and increased healthcare cost. It is also characterized by excessive inflammation and dysregulated levels of pro-inflammatory cytokines and proteases like interleukins and myeloperoxidases. The use of combined corticosteroids with antibiotics have been shown to modulate the level of cytokines and proteases with varying effects.

Objectives- This study aimed to determine the effects of different combinations of corticosteroids-mupirocin topical agents on tissue interleukin 6 and myeloperoxidase obtained from infected wounds in Wistar rats.

Methodology- An experimental study conducted among 42 male Wistar rats weighing 150-200g. They were randomly assigned into 7 groups of 6 rats each. Group 1 had no wound. A 2x2cm wound was made on the lower back of the rats in groups 2-7 using scalpel on Day 0 and the wounds were infected with *Staphylococcus aureus* and *Pseudomonas aeruginosa* on Day 3. On Day 5, Group 2 had wound dressed with only Vaseline gauze. Group 3 had wound dressed with Mupirocin ointment only. Group 4 had wound dressed with Mupirocin- Betamethasone combination (1:1). Group 5 had wound dressed with Mupirocin- Triamcinolone combination (1:1). Group 6 had wound dressed with Mupirocin- Betamethasone combination (2:1). Group 7 had wound dressed with Mupirocin-Triamcinolone combination (2:1). On the 25th day of the experiment, the rats were sacrificed through cervical dislocation. The wounds were excised and the homogenized tissues were assayed for interleukin- 6 and myeloperoxidase using the ELISA and colorimetry methods respectively. The data were analyzed using SPSS for Windows. Continuous variables were compared across groups using one-way analysis of variance (ANOVA) and the post-hoc test. ROC analysis to determine the sensitivity and specificity of the biochemical markers was done using MedCalc statistical software. The level of significance was set at p-value of < 0.05

Results- The interleukin-6 was insignificantly decreased ($p=0.222$) and myeloperoxidase was insignificantly increased ($p=0.738$) in the treatment groups when compared with group 2 (positive control). There was a negative correlation between interleukin 6 and wound infection on Day 10 of the experiment ($r=-0.510$ $P=0.013$) and a positive correlation between the myeloperoxidase level and wound infection on Day 10 ($r=0.421$ $P=0.013$). Myeloperoxidase \leq

27.81 μ mol/g had a sensitivity of 100%, a specificity of 53.85% while interleukin-6 >154.02 pg/mL had a sensitivity of 50%, a specificity of 88.46%. Comparison of the ROC curves however showed that myeloperoxidase is insignificantly more discriminant than IL-6 (P= 0.287).

Conclusion-Corticosteroid-mupirocin cream combination increases myeloperoxidase and decreases interleukin-6 in rat wounds. Myeloperoxidase is a better marker to diagnose or monitor the resolution of wound infection compared with interleukin-6.

Introduction

A wound is defined as damage or disruption to the normal architecture and function of any tissue. This damage ranges from the loss of epithelial surface of the skin to disruption of deeper structures. (1,2)It becomes chronic when it persists beyond four weeks due to compromise in some of the components of the wound healing process. One of the factors which can cause failure of normal wound healing is wound infection.(3–5)

Wound infection is the result of microbial invasion of soft tissue and poses considerable clinical challenges. It causes increased patient morbidity; anxiety and it is associated with delayed healing and increased healthcare cost.(6) A reduction of observed wound infection rate to a minimum level would have marked benefits in terms of patient comfort and resources used.(7) Strategies for the diagnosis of wound infections also remain a great challenge due to the occurrence of biofilm colonization.(7)

Currently, detection of wound infection is based on evaluation of the local signs of inflammation like redness, pain, exudate etcetera and the use of wound culture to identify the causative organism(s).(8)However, the former is not adequate to make the diagnosis and the later may take some time thus there is a need for a more rapid and effective prognostic aid that would assist in predicting clinical infection of a wound prior to obvious clinical symptoms.

Wound infection is characterized by excessive inflammation and increased levels of pro-inflammatory cytokines and proteases and a couple of cytokines and enzymes are known to be raised in infected wounds.(9,10) One of such is interleukin 6 which is a cytokine with mainly pro-inflammatory effects that has been found to be raised in chronic wounds. Dysregulation of Interleukin 6 signalling has also been shown to lead to increased risk of wound infection. (11–13)Myeloperoxidase (MPO) on the other hand is a haem- containing proteolytic enzyme which is stored in the azurophilic granules of neutrophils and in the lysozymes of monocytes. Elevated

concentration of MPO has been reported to be a potentially useful marker for quantification of tissue infection. In addition, MPO from wound exudates has also been used to monitor the effectiveness of wound therapy.(14–17)

Corticosteroids have been previously known to cause dehiscence of surgical incision, increased risk of infection and delayed healing of open wounds. These actions are mediated by antagonism of various growth factors and cytokines. The tendency for corticosteroids to increase the susceptibility to bacterial invasion has however been reversed by combining it with antimicrobial agents which has also improved its wound healing ability. Mupirocin, the topical antibiotics combined with corticosteroid in this study has been previously utilized for managing various skin and soft tissue infections and in the treatment of methicillin resistant *Staphylococcus aureus* and few gram-negative organism

This study aimed to determine the effects of different combinations of corticosteroids-mupirocin topical agents on tissue interleukin 6 and myeloperoxidase obtained from infected wounds in Wistar rats. Two different corticosteroids (Triamcinolone and Betamethasone) with varying combination ratios with Mupirocin were used in the study. The study also examined the most accurate between the two markers- interleukin-6 and myeloperoxidase in predicting wound infection. At the time of the literature search, no previous research has looked into the effect of Corticosteroid-mupirocin combinations on wound interleukin-6 and myeloperoxidase.

METHODOLOGY

3.1 CHEMICALS AND DRUGS

15g 2% Mupirocin ointment (Mupiderm®, Yash Medicare, India); 25g 0.1% Triamcinolone acetonide cream (Fidson Healthcare Plc, Nigeria); 25g 0.1 % Betamethasone valerate cream (Fidson Healthcare Plc, Nigeria). E-lab Science Colorimetric kit for myeloperoxidase; E-lab Science ELISA kit for Interleukin 6.

3.2 ANIMALS

The male Wistar rats used in the study were housed in plastic cages with controlled temperature 25°C±2.5°C. The rats were allowed free access to food and water. They were fed with standard laboratory diet and water *ad libitum* and maintained under good conditions throughout the

experimental period. They were also allowed to acclimatize for 14 days before the onset of the experiment in order to reduce the effect of untoward metabolic response on the wound.

The ethical approval was obtained from the Ethical Review Board of the Faculty of Basic Medical Sciences, LAUTECH with identification code ERC/FBMS/054/2024. All procedures were conducted in accordance with the approved protocols of the Faculty of Basic Medical Sciences, LAUTECH with and within the provisions for animal care and use prescribed in the scientific procedures on living animals, European Council Directive (EU2010/63)

3.3 EXPERIMENTAL DESIGN

Forty-two male Wistar rats (150 -200 g) were used in the study. The rats were randomly assigned into 7 groups of 6 rats each. A total of 42 rats (n=42) was used for this experiment which was carried out at the Anatomy animal house. The animals were separated into seven groups which include the following:

Group 1- First control with no wounds during the experimental period

Group 2- Second control with wound dressed with only Vaseline gauze

Group 3- Wound was dressed with Mupirocin ointment only.

Group 4- Wound was dressed with Mupirocin- Betamethasone combination (1:1).

Group 5- Wound was dressed with Mupirocin- Triamcinolone combination (1:1).

Group 6- Wound was dressed with Mupirocin- Betamethasone combination (2:1).

Group 7- Wound was dressed with Mupirocin-Triamcinolone combination (2:1).

Each group was kept in separate cages and the animals were differentiated per group using Gentian Violet. The body parts of rats marked were: Left ear (LE), Right ear (RE), Abdomen (A), Back (B), Tail (T) and Neck (N). The tag "2LE" for instance means the rat belong to group 2 and was marked on the left ear for identification and documentation purpose(s). Two of the rats died before the end of the experiment.

3.4 STUDY PROTOCOL

The first phase of the procedure was wound creation. The rats were anaesthetized with ketamine 10mls in concentrations of 50mg/ml and doses of 0.25ml/rat was injected into the peritoneal cavity using 2 mls syringe and needle. A 2x2 cm circular area was measured on the right dorsal part (lower back) of each rat with the aid of a template as is found in the model by Nafiu and colleagues.(18)The hair in the marked area and the adjoining skin were shaved using a razor blade and aseptic skin preparation was carried out using 5% povidone iodine solution. A full thickness excision of the skin and subcutaneous tissue was then done using a scalpel sparing the panniculus carnosus muscle. Hemostasis was secured with pressure pack and the wounds were dressed with Vaseline gauze and Medipore adhesive dressing and further reinforced with zinc oxide plaster.

The rats were observed till they woke up after the procedure. The dressings were left in-situ for three days while the wounds were allowed to granulate. On the third day post-op, all wounds were inoculated with already prepared Colony Forming Unit (CFU) bacteria in order to simulate an infected wound environment. The contamination of the wound with external bacteria was prevented by doing closed dressing under sterile conditions and also by regular disinfection of the environment. At each dressing change the old dressings were removed and the wound cleaned with normal saline before putting a new dressing. The wounds were assessed weekly for signs of infection using the Southampton wound grading system. On the 25th day of the experiment, all the rats were sacrificed through cervical dislocation after anaesthetizing with Intraperitoneal Ketamine. The wounds or the resulting scars and the skin of the negative control (Group1) were excised immediately the rats were sacrificed and subjected to biochemical analysis. The rats were disposed by burying.

3.5 WOUND DRESSING PROTOCOL

The dressing protocol for each experimental group post wound infection are as highlighted below:

Group 2- (positive control) – Vaseline gauze, Medipore adhesive dressing, Zinc oxide plaster.

Group 3-(Mupirocin ointment only)- Mupirocin ointment(0.3mls), Vaseline gauze, Medipore adhesive dressing, Zinc oxide plaster.

Group 4- (Mupirocin- Betamethasone combination {1:1})- 0.15mls Mupirocin ointment/ 0.15 mls Betamethasone cream, Vaseline gauze, Medipore adhesive dressing, Zinc oxide plaster

Group 5- (Mupirocin-Triamcinolone combination{1:1})- 0.15 mls Mupirocin ointment/ 0.15mls Triamcinolone cream, Vaseline gauze, Medipore adhesive dressing, Zinc oxide plaster.

Group 6- (Mupirocin-Betamethasone combination (2:1)- 0.2 mls Mupirocin ointment/ 0.1mls Betamethasone cream, Vaseline gauze, Medipore adhesive dressing, Zinc oxide plaster.

Group 7- (Mupirocin-Triamcinolone combination {2:1}) 0.2mls Mupirocin ointment/ 0.1mls Triamcinolone cream, Vaseline gauze, Medipore adhesive dressing, Zinc oxide plaster.

The volume of the creams applied on the wounds were measured by removing the plunger of 2mls syringe and pressing the cream from the tube directly into the syringe till it reaches the 2mls mark. The plunger is then replaced gently avoiding the spilling of the cream from the tip of the syringe. The appropriate volume is dispensed through the tip of the syringe according to the group protocol.

3.6 PREPARATION AND INDUCTION OF THE BACTERIA COLONY FORMING UNIT

From clinical sample obtained from LAUTECH Teaching Hospital, Microbiology Laboratory. The bacteria were inoculated on blood agar media and incubated at 37°C for 18-24 hours. After incubation, bacteria growth was checked and the bacteria isolate of *Staphylococcus aureus* and *Pseudomonas aeruginosa* was identified using their colonial morphology and biochemical tests. *Staphylococcus aureus* appears on blood agar plate as round colonies surrounded by zones of clear beta haemolysis while *Pseudomonas aeruginosa* appears as round grey colonies with irregular margin also surrounded by zones of clear beta haemolysis. *Staphylococcus aureus* was coagulase positive while *Pseudomonas aeruginosa* was coagulase negative. A 3mm wire loop was used to pick a colony of each organism from the blood agar plate and was diluted in 5mls of normal saline in separate universal bottles. Immediately after excising the skin, each wound was inoculated with 0.1 mls solution of *Staphylococcus aureus* and 0.1 ml solution of *Pseudomonas aeruginosa* respectively. (19)

3.7 BIOCHEMICAL ANALYSES

The tissues obtained were homogenized in phosphate buffer. Biochemical assay of inflammatory markers- Interleukin 6 and Myeloperoxidase of the homogenized tissue was also done as highlighted below:

3.7.1 Interleukin 6

Determination of the tissue interleukin-6 was done by sandwich-ELISA principle. The micro-ELISA plate has been pre-coated with antibody specific for rat Interleukin-6. The reagents used include: washing buffer, standard working solution, biotinylated detection antibody working solution and concentrated HRP conjugate working solution. All reagents were brought to room temperature before use. The assay was done by adding 100µl standard working solution or sample to each well and incubating for 90 minutes at 37°C. The liquid was removed and 100µL biotinylated detection antibody was added and incubated for 1 hour at 37°C. This was then aspirated and washed three times. Subsequently, 100µL HRP conjugate was added and incubated for 30 minutes at 37°C. This was also aspirated and washed five times. 90µL substrate reagent was added and incubated for 15 min at 37°C. 50µL stop solution was thereafter added. The absorbance was read at 450nm and the results were calculated.

3.7.2 Myeloperoxidase

Determination of myeloperoxidase was done by colorimetric principle. Myeloperoxidase (MPO) reduces hydrogen peroxide to a complex. The complex reacts with o-dianisidine (as hydrogen donor) to produce a yellow product which has a maximum absorption peak at 460 nm. The activity of MPO was calculated indirectly by measuring the OD value at 460nm. The assay procedure was conducted as follows: for the control group, 3 mL of double distilled water, 0.2 mL of sample, 0.2 mL of clarificant were added into 5 mL tubes. For the sample tube, 0.2 mL of sample, 0.2 mL of clarificant, 3 mL of chromogenic agent were added into 5 mL tubes. The tubes were oscillated fully with a vortex mixer and incubated for 30 min at 37°C. 0.05 mL of acidreagent was added, oscillated fully with a vortex mixer and incubated for 10 min at 60°C water baths. The tubes were centrifuged at 2325 g for 10 min and the supernatant was taken to measure the optical density value. The spectrophotometer was set to zero with double distilled water and the OD value of each tube was measured at 460 nm with 1.0 cm optical path cuvette immediately.

3.8 DATA ANALYSIS

The data analysis was performed using SPSS for Windows (SPSS, Inc., Chicago, IL) software version 23. Continuous variables were compared across groups using one-way analysis of variance (ANOVA) and the post-hoc analysis. ROC analysis was done to determine the sensitivity and specificity of the two markers using MedCalc statistical software. The level of significance was set at p-value of < 0.05

RESULTS

The result of the tissue myeloperoxidase across the groups showed that Group 2 (positive control) had the lowest level of myeloperoxidase. The myeloperoxidase level was however high in Group 1 (negative control) and the test groups with no significant difference between the groups. (Figure) The result of the tissue interleukin-6 across the groups showed that Group 2 (positive control) had the highest level of interleukin 6 followed by Group 1 (negative control). The Interleukin-6 level was lower in all the test groups with no significant difference between the groups. (Figure)

The result of the correlation analysis showed that there was a negative correlation between interleukin 6 and wound infection on Day 10 of the experiment ($r=-0.510$ $P=0.013$). There was a positive correlation between the myeloperoxidase level and wound infection on Day 10 ($r=0.421$ $P=0.013$). There was however no correlation between both interleukin-6 and myeloperoxidase and wound infection on Day 17 and 24. There was also no correlation between the level of interleukin-6 and myeloperoxidase and other parameters tested which include: epithelization, microbial density and the type of organism cultured.

In our study, myeloperoxidase showed the highest sensitivity in the detection of wound infection when compared with interleukin 6. The ROC curve was constructed to select a cutoff value at which to dichotomize interleukin 6 and myeloperoxidase as being diagnostic of wound infection or not. The area under the ROC curve (AUC) indicates the clinical usefulness of the marker- the larger the AUC, the better the marker. For myeloperoxidase (area under the ROC curve, 0.837; $z=4.705$; $P < 0.0001$), and a cutoff value of $27.81 \mu\text{mol/g}$ was chosen. Myeloperoxidase $\leq 27.81 \mu\text{mol/g}$ had a sensitivity of 100%, a specificity of 53.85%, a positive predictive value of

45.5% and a negative predictive value of 100% with Youden index J of 0.5385. For Interleukin-6 (area under the ROC curve, 0.708; $z=2.132$; $P=0.033$), and a cutoff value of 154.02pg/mL was chosen. Tissue interleukin-6 >154.02 pg/mL had a sensitivity of 50%, a specificity of 88.46%, a positive predictive value of 66.7% and a negative predictive value of 80% with Youden index J of 0.3846. Comparison of the ROC curves however showed that myeloperoxidase is insignificantly more discriminant than IL-6 ($P=0.287$).

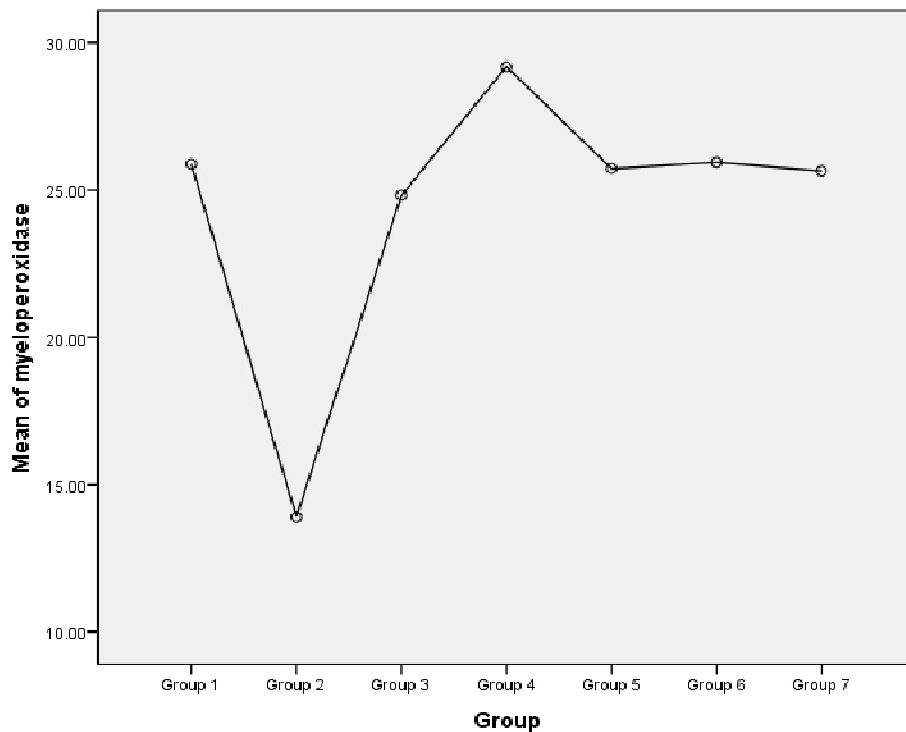


Figure 1- A line graph showing the variation of the mean tissue myeloperoxidase ($\mu\text{mol/g}$) across the groups

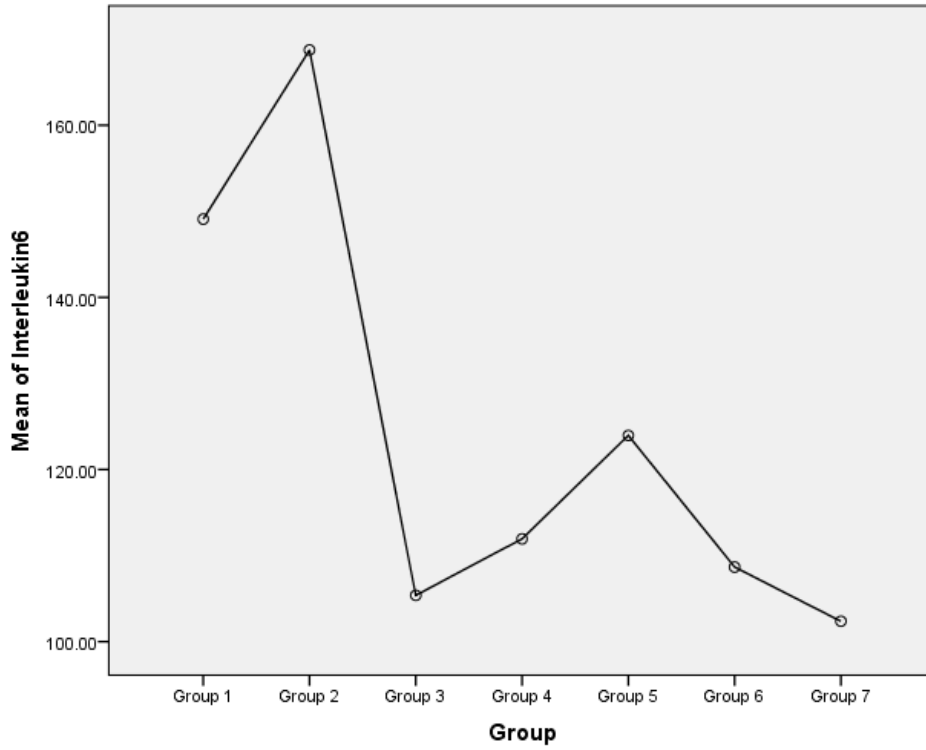


Figure 2 - A line graph showing the variation of the mean tissue interleukin 6 (pg/g) across the groups

Table 1- Correlations between Interleukin-6 and myeloperoxidase tissue level and wound infection

Wound infection	Interleukin- 6		Myeloperoxidase	
	r	P	r	P
Wound infection at Day 10	-0.510	0.002	0.421	0.013
Wound infection at Day 17	0.217	0.218	-0.137	0.438
Wound infection at Day 24	0.349	0.043	0.116	0.513

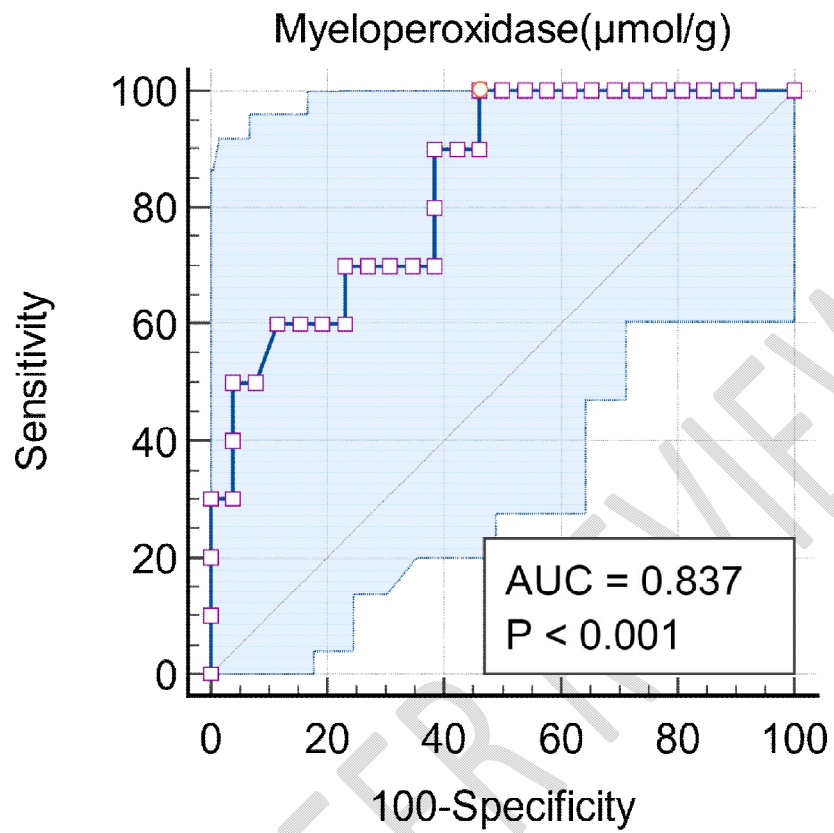


Figure 3- The Receiver Operating Characteristic (ROC) curve for Myeloperoxidase

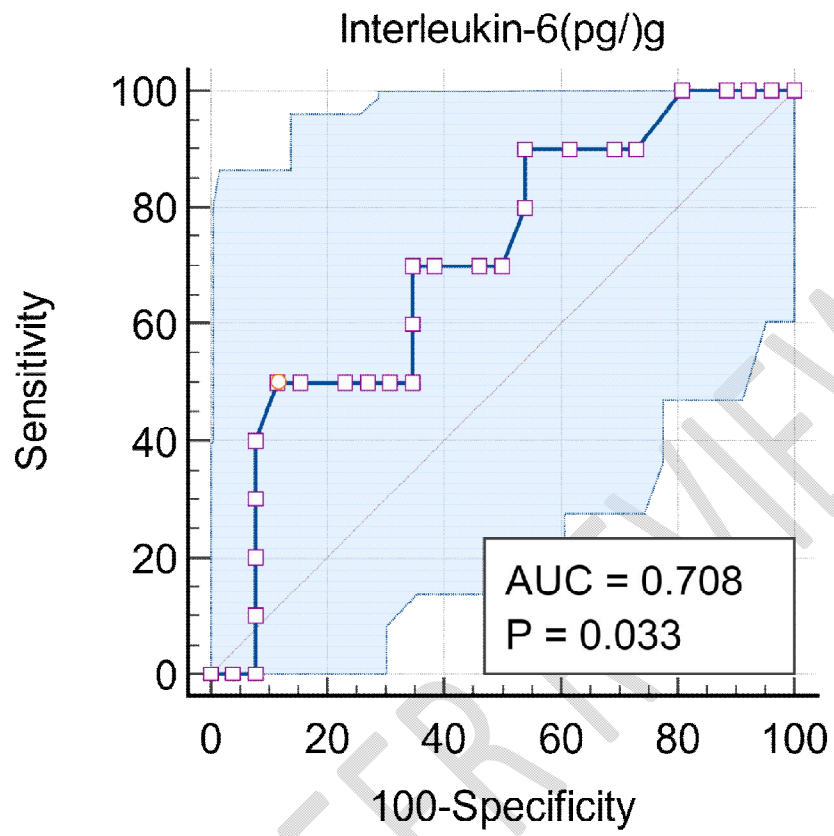


Figure 4-The Receiver Operating Characteristic (ROC) curve for Interleukin-6

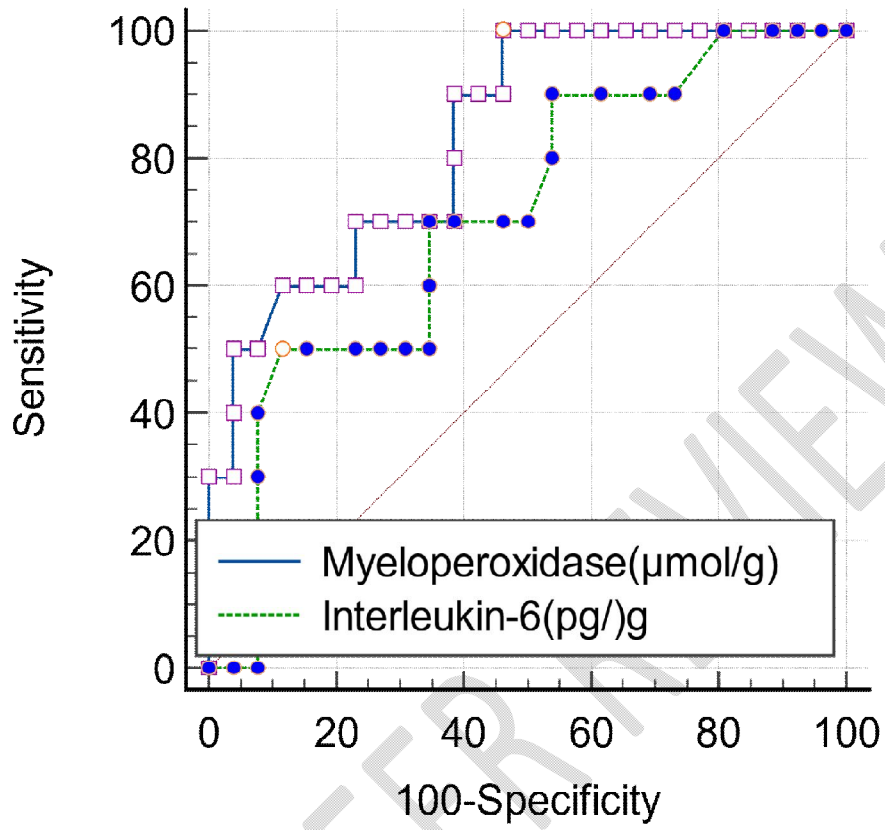


Figure 5-The combined Receiver Operating Characteristic (ROC) curve for Myeloperoxidase and Interleukin-6

DISCUSSION

Cytokines are classes of biologically active low molecular weight proteins with hormone-like and or enzyme-substrate actions that play important roles of modulating the intensity, actions, production and duration of immune and physiologic cells of the body for effective response to the environment. Interleukin 6 is a cytokine which has both pro and anti-inflammatory effects and has also been detected at a high quantity in chronic wounds. It also plays active role in the production of acute phase protein and stimulates the production of cellular and humoral immune responses.

Dysregulation of Interleukin 6 signalling can lead to failure to heal and increased risk of infection. Steroids have been specifically shown to decrease proliferation and IL6 expression in lung fibroblasts. The maximal IL-6 activity in wound reached 12 hours after wounding. In fact, >80% of the peak IL-6 level was detected as early as 6 hours after sponge implantation. After this early peak, the interleukin 6 activity in wound fluid decreased to its nadir at Day 3, only to increase on Days 5-10.(20)

In keeping with most findings in the literature, we found that at the end of the study the control group had a higher concentration of interleukin 6 when compared with other test groups where mupirocin and different corticosteroid combination was used on the wounds. This further buttress the decrease in the tissue Interleukin 6 expression as wound infection resolves and as the wound heals as shown in other previous studies. Group 5 which is made up of Mupirocin cream and Triamcinolone ointment (1:1) however had the highest concentration of Interleukin 6 amidst the test group which possibly emphasized the reduced efficacy of triamcinolone in suppressing interleukin 6 expression. One of the very few earlier contrasting studies was that done by Turksen et al.(21) which showed that IL-6 expression did not lead to enhanced epidermal proliferation, but it did results in a thicker stratum corneum. IL-6 expression also did not lead to leucocytic infiltration making it unlikely that it has direct pro-inflammatory activity in the skin. Supomoetal(22) also documented higher serum post-operative interleukin-6 in patients with surgical site infection. The sensitivity and specificity of interleukin-6 from this study(50% and 88.46% respectively) is quite low when compared with that reported by Elshamy et al(23) with a sensitivity of 100% and a specificity of 90%. The differences in the result may be due to the fact that serum Interleukin-6 was used as opposed wound interleukin in our study.

Myeloperoxidase (MPO) on the other hand is a haem- containing protein consisting of twodimers connected by a disulphide bond. It is stored in the azurophilic granules of neutrophils and in the lysozymes of monocytes and is not released until the activation and degranulation of neutrophils. MPO catalyses the production of hypochlorous acids by converting hydrogen peroxide and chloride ions. Elevated concentration of MPO is potentially useful marker for quantification of tissue PMN accumulation. Dechert et al.(24) has previously shown that MPO concentrations are significantly lower in wound fluid of acute healing wounds compared to those present in tissues of pressure ulcers. In another study by Guo et al,(14) it was also discovered that significantly higher MPO activity was detected in infected skin wounds (*Pseudomonas aeruginosa* or *Staph. aureus*) when compared with non-infected wounds. Maritati et al(25) also showed high levels of myeloperoxidase in periprosthetic joint infections with sensitivity of 69% and specificity of 88% In our study however, there was no statistically difference in the myeloperoxidase concentration between the groups but it was noticed that the MPO for the animals in group 2 (positive control) was lower than that of the other groups.

Conclusion

the study has shown that corticosteroids-mupirocinsuppresses interleukin-6 but increases myeloperoxidase in wounds infected with *Staphylococcus aureus* and *Pseudomonas aeruginosa*. Interleukin-6 was also shown to have a higher sensitivity in predicting wound infection

COMPETING INTERESTS DISCLAIMER:

Authors have declared that they have no known competing financial interests OR non-financial interests OR personal relationships that could have appeared to influence the work reported in this paper.

REFERENCES

1. Heng MC. Wound healing in adult skin: aiming for perfect regeneration. Int J Dermatol. 2011;50(9):1058–66.

2. Reinke JM, Sorg H. Wound repair and regeneration. *Eur Surg Res.* 2012;49(1):35–43.
3. Robson MC. Wound infection. A failure of wound healing caused by an imbalance of bacteria. *Surg Clin North Am.* 1997;77(3):637–50.
4. Rehring JF, Bui TM, Galan- Enriquez CS, Urbanczyk JM et al. Released myeloperoxidase attenuates neutrophil migration and accumulation in inflamed tissue. *Front Immunol.* 2021;12(654259).
5. Guo S, DiPietro LA. Factors affecting wound healing. *J Dent Res.* 2010;89(3):219–29.
6. Cutting KF. The current burden of infected wounds. *Br J Healthc Manag.* 2016;22(9).
7. Sawyer RG, Pruett TL. Wound infections. *Surg Clin North Am.* 1994;74(3):519–36.
8. Ding X, Tang Q, Xu Z, Xu Y, Zhang H, Zheng D et al. Challenges and innovations in treating chronic and acute wound infections: from basic science to clinical practice. *Burn Trauma.* 2022;10:tkac014.
9. schilrreff P, Alexiev U. Chronic inflammation in non-healing skin wounds and promising natural bioactive compounds treatment. *Int J Mol Sci.* 2022;23(4928).
10. Zhao R, Liang H, Clarke E, Jackson C, Xue M. Inflammation in chronic wounds. *Int J Mol Sci.* 2016;17(2085).
11. O'Reilly S, Ciechomska M, Cant R, Hogle T, van Lar JM. Interleukin-6, its role in fibrosing conditions. *Cytokine Growth Factor Rev.* 2012;23:99–107.
12. Lin ZQ, Kondo T, Ishida Y, Takayasu T, Mukaida N. Essential involvement of Interleukin 6 in the skin wound healing process as evidenced by delayed wound healing in Interleukin-6 deficient mice. *J Leucoc Biol.* 2003;73:713–21.
13. Lee EG, Lockett-Chastain LR, Calhoun KN, Frempah B, Bastian A et al. Interleukin-6 function in the skin and isolated keratinocytes is modulated by hyperglycaemia. *J Immunol Res.* 2019;2019(5087847).
14. Guo R, Li S, Xia H, Feng Z et al. Effects of Myeloperoxidase on Methicillin-Resistant *Staphylococcus aureus*-colonized burn wounds in Rats. *Adv Wound Care.* 2019;0865.

15. Suchitra TV, Zuhara KF. Myeloperoxidase activity in infection complicated and uninfected diabetic patients. *Indian J Biochem Biophys.* 2008;45:179–83.
16. Hasmann A, Wehrschoetz-Sigi E, Marold A, Wiesbauer H, Schoeftner R et al. Analysis of myeloperoxidase activity in wound fluids as a marker of infection. *Ann Clin Biochem.* 2013;50:245–54.
17. Saed GM, Jiang Z, Diamond MP, Abu-Soud HM. The role of myeloperoxidase in the pathogenesis of post-operative adhesions. *Wound repair Regen.* 2009;17:531–9.
18. Nafiu AB, Akinwale OC, Akinfe OA, Owoyele BV et al. Histomorphological evaluation of wound healing - comparison between use of honey and vernonia amygdalina leaf juice. *Trop J Heal Sci.* 2016;23:10–8.
19. Fila G, Kasimova K, Arenas Y, Nakonieczna J, et al. Murine model imitating chronic wound infections for evaluation of antimicrobial photodynamic therapy efficacy. *Front Microbiol.* 2016;7:1258.
20. Mateo RB, Reichner JS, Albina JE. Interleukin 6 activity in wounds. *Am J Physiol.* 1994;266:R1840-4.
21. Turksen K, Kupper T, Degenstein L, Williams I, Fuchs E. Interleukin 6: Insights to its functions in skin by overexpression in transgenic mice. *Proc Natl Acad Sci.* 1992;89:5068–72.
22. Supomo S. Correlation of interleukin-6 serum level and surgical site infection in post major surgery patient. *Bali Med J.* 2019;8(1):18–20.
23. Elshamy NT, Elshennawy SM, Donia MA. The predictive ability of interleukin-6 for infection after major surgery. *J Med Sci Res.* 2023;6(3).
24. Dechert TA, Ducale AE, Ward SI, Yager DR. Hyaluronan in human acute and chronic dermal wounds. *Wound repair Regen.* 2006;14:252–8.
25. Maritati M, DeRito G, Rosta V, Cervellati C, Cristina Manfrinato M et al. active myeloperoxidase: a promising biomarker to differentiate acute and low grade peri-prosthetic joint infections from aseptic failure. *Front Microbiol.* 2024;

UNDER PEER REVIEW